



Review Article

Effective lung cancer control: An unaccomplished challenge in cancer research

Neeraja Panakkal, MSc^{1,2}, Asha Lekshmi, PhD¹, Veena Vamadevan Saraswathy, PhD³, Kunjuran Sujathan, PhD¹ 

¹Division of Cancer Research, Regional Cancer Centre, Thiruvananthapuram, Kerala, ²Manipal Academy of Higher Education, Manipal, Karnataka, ³Division of Pathology, Regional Cancer Centre, Thiruvananthapuram, Kerala, India



***Corresponding author:**

Kunjuran Sujathan,
Division of Cancer Research,
Regional Cancer Centre,
Thiruvananthapuram, Kerala,
India.

ksujathan@gmail.com

Received : 15 September 2022

Accepted : 10 October 2022

Published : 07 August 2023

DOI

10.25259/Cytojournal_36_2022

Quick Response Code:



ABSTRACT

Lung cancer has always been a burden to the society since its non-effective early detection and poor survival status. Different imaging modalities such as computed tomography scan have been practiced for lung cancer detection. This review focuses on the importance of sputum cytology for early lung cancer detection and biomarkers effective in sputum samples. Published articles were discussed in light of the potential of sputum cytology for lung cancer early detection and risk assessment across high-risk groups. Recent developments in sample processing techniques have documented a clear potential to improve or refine diagnosis beyond that achieved with conventional sputum cytology examination. The diagnostic potential of sputum cytology may be exploited better through the standardization and automation of sputum preparation and analysis for application in routine laboratory practices and clinical trials. The challenging aspects in sputum cytology as well as sputum-based molecular markers are to ensure appropriate standardization and validation of the processing techniques.

Keywords: Lung cancer, Molecular markers, Sputum cytology

INTRODUCTION

Lung cancer or bronchogenic carcinoma refers to tumors originating in the lung parenchyma or within the bronchi.^[1] Globally, lung cancer has emerged as the most important cause of morbidity and mortality, accounting for more than 180,000 newly diagnosed patients and 160,000 deaths.^[2] A highest incidence rate of 34.2 and a mortality rate of 30/100,000 were reported in men in 2014.^[3] An increased lung cancer incidence among women has been reported in Hungary, followed by North America, North and West Europe, and Chile.^[4] Smoking is responsible for about 85% of all lung cancers^[5] but, now, this is changing. Incidence among non-smoking females has become an important concern.^[6] In India, lung cancer was initially thought to be extremely rare. However, later, it is found to rise all over the country, and currently, it ranks fourth (5.9%) in overall cancer incidence. Shockingly, it is adenocarcinoma, the type least linked with smoking that is increasing faster. A rise in the incidence of lung cancer in non-smoking Indian women is yet another shocking trend.^[7]

Although notable progress in lung cancer treatment has been made in recent years, the mortality rate remains very high because it is often diagnosed at an advanced stage. Long-term survival is confined to patients with Stage 0 disease. However, only 0.6% of the lung cancer population constitutes this group since these small tumors are clinically asymptomatic.^[8] Therefore, much interest has been devoted to identifying reliable methods for detecting the disease in the asymptomatic phase itself and prompt treatment in addition to primary prevention strategies.

Imaging techniques are the current mainstream diagnostic methods to detect lung cancer. The most prevalent approach is computed tomography (CT), sometimes combined with positron emission tomography (PET). Early detection of lung cancer by screening using low-dose CT (LDCT) has been reported to increase survival. International Early Lung Cancer Action Program has documented a 10-year survival of 88% in early stage lung cancer patients, identified in screening.^[9] Furthermore, the National Lung Screening Trial with LDCT reported a reduction of death by 20%, in which three annual CT scans were done.^[10] These results from the developed countries demonstrate that screening can detect disease at an early stage when it can be effectively controlled. However, none of these imaging techniques is feasible for screening in India and similar countries. Sputum cytology has been recognized as the only non-invasive laboratory method of diagnosis for lung cancer, and there are some reports of X-ray chest and sputum-based studies.^[11] The first study was in 1960, in which X-ray chest-based screening could not find any role in identifying the early lesions of lung cancer. During the 1970s, NCI reported the results of three randomized studies of sputum cytology combined with an X-ray chest. During the same period, another randomized study of chest X-ray combined with sputum cytology was reported in Czechoslovakia.^[12] None of these studies were helpful in detecting lung cancer at a resectable stage which has been attributed to the lack of sensitivity of sputum cytology at that time. According to the American Cancer Society guidelines of 2012, the death rate due to lung cancer can be reduced considerably by regular screening with CT, which is out of question in India and other low-resource countries.^[10] Hence, there is an urgent need for more sensitive cost-effective non-invasive techniques for the identification of early malignant and pre-neoplastic lesions of the lung. We present a review of the current literature to identify the possibility of using molecular markers to supplement the conventional morphological evaluation and preselect high-risk people so that they can be subjected to further imaging techniques to identify early lesions.

METHODOLOGY

A systematic literature search in PubMed, Scopus, and Google Scholar databases was performed for relevant articles published up to December 2020 with lung cancer biology, lung cancer early detection, lung cancer molecular markers, and sputum cytology-lung cancer detection as keywords. The search rooted on some inclusion criteria such as the articles published in peer-reviewed journals in the English language with our keywords in the aspects of lung cancer diagnosis and management including pioneer publications relevant to the current review. The case studies, clinical reports, and meeting proceedings were included if they cued on our theme of interest.

LUNG CANCER BIOLOGY

Anatomically, the respiratory tract is constituted by the upper and lower respiratory system composed of multiple types of epithelial and non-epithelial cells. Lung cancers can arise from any of these cells and, therefore, present with highly variable signs and symptoms. The cellular origins of different histopathological subtypes of lung cancers remain controversial. Each subtype arises from distinct cells of origin localized in a defined microenvironment. Squamous cell lung cancers constitute about 25–30% and arise from the proximal airway with a proximal-to-distal distribution pattern, whereas adenocarcinoma constitutes about 40% of all lung cancers, arise from a more distal locus often in the peripheral bronchi.^[13] Bronchioalveolar cancers/adenocarcinoma *in situ* (AIS) and minimally invasive adenocarcinoma arise in alveoli and spread through the intra-alveolar connections. Small cell lung cancers (SCLC) comprise about 10–15%, arise from the hormonal cells of the lung, and tend to be the central mediastinal tumors. Non-small cell lung carcinomas (NSCLCs) not otherwise specified comprise 10% and arise from a more proximal location. However, lung cancer has been generally grouped into two main histopathological subtypes: NSCLC constituting approximately 85% and SCLC about 15% of all lung cancers.

Abundant genetic diversity is distinctive in lung cancer. Next-generation sequencing and similar high-throughput genetic profiling have reported mutations, epigenetic alterations, and structural rearrangements in different genes involved in oncogenic pathways. Activation by amplification of different oncogenes has been reported in different subtypes of lung carcinomas.^[14] Despite its impact on oncogenesis, all these mutations are evident in advanced lung cancers, and none of them is instrumental in early detection of lung cancer.

As for other carcinomas, lung carcinoma is also preceded by precancerous lesions whose molecular signatures remain an enigma for oncologists. Unravelling of the oncogenic progression of these precancerous lesions to invasive lung carcinoma and the molecular insights into it is greatly demanding. Squamous metaplasia, squamous dysplasia (SD), and carcinoma *in situ* (CIS) are the three precursor lesions known for squamous cell carcinoma^[15] whereas atypical adenomatous hyperplasia (AAH) and AIS are that for adenocarcinoma.^[16] For carcinoids, diffuse idiopathic pulmonary neuroendocrine cell hyperplasia (DIPNECH) and tumorlets are ranked as the pre-neoplastic types, and for large cell carcinoma, no such lesions are explored till date.^[17] These asymptomatic precancerous lesions are often present as indeterminate pulmonary nodules and identification of patients at this stage when curative treatment is possible is extremely important and improves the prognosis. Pre-existing basal cell hyperplasia is a hub of squamous metaplasia and dysplasia where squamous differentiation

occurs, and a differentiated ciliated epithelium marks the growing basal zone. Normal bronchial epithelium platforms the development of *in situ* carcinoma in a period of 10–15 years.^[18] AAH is often small and asymptomatic diagnosed incidentally during surgery or with spiral CT having high resolution. AAH often develops in the centriacinar region near the respiratory bronchioles from the progenitor cell with a potential for both Type II pneumocyte and Clara cell differentiation.^[19]

The oncogenic path of many lung tumors is yet to be deciphered. Lung neuroendocrine tumors comprising 25% of all lung cancers are a widely discussed one in this aspect. The hyperplastic and pre-neoplastic lesions are thought to arise from an undifferentiated multipotential bronchial epithelial cell in the central and peripheral regions of the lung.^[20] DIPNECH, one of the most mysterious neuroendocrine disorders of the lungs, is considered as a pre-neoplastic lesion that has to be proved further.^[21]

GENETICAL ALTERATIONS IN PRENEOPLASTIC LESIONS

Sequential alterations of numerous genetic and molecular characteristics have been observed in pre-invasive lesions and even in the bronchial epithelium of smokers that appear to be normal.^[22,23] The frequency and number of these alterations were found to vary with respect to the grade of abnormality in atypia, metaplasia, CIS, and AAH, opening up an opportunity to be exploited as predictors of malignancy in combination.^[24] Genomic integrity of p53 and of bcl2 has been documented as indicators in pre-invasive bronchial lesions.^[25] Mutation of the KRAS gene has been observed to be more frequent in AAH than in SD.^[26]

Deletion of the fragile histidine triad tumor suppressor gene is often seen in lung carcinomas, especially in NSCLC and pre-invasive lesions of both squamous cell carcinoma and adenocarcinoma.^[26] Proliferative markers such as Ki67 have been reported to display a progressive expression level with atypia in both SD and AAH.^[27,28] Among the cell cycle regulatory proteins, p16 was found to be hypermethylated and lost in SD, whereas Cyclin D1 and E were found overexpressed in pre-cancerous lesions of squamous and glandular cells.^[26,29] CIS was reported to be rare in AAH.^[18] Most studies suggest a prolonged pre-invasive lag phase of more than 5 years for the pre-neoplastic lesions to turn malignant. If tackled at this phase, neoplastic progression can be prevented effectively. Recent research focuses on developing suitable criteria for this high-risk population screening. Lung cancer screening was initiated in the early 60s with chest radiography and sputum cytology in multiple centers, but the results were not promising.^[30-33] Thereafter, screening module was upgraded with LDCT found beneficial to reduce the mortality rate significantly.^[34-36] However,

overdiagnosis and several adverse effects such as high false-positive rate, cost of doing, and radiation exposure were the drawbacks making LDCT difficult to practice.^[10] PET using fluorodeoxyglucose and autofluorescence bronchoscopy was found to be highly beneficial for detecting very small lesions and thickenings in the lung.^[37,38]

Selective detection of volatile organic compounds with gas chromatography and pattern recognition method are the two main approaches currently being investigated which aids breath print analysis as a developing powerful tool for enhancing early detection of lung cancer.^[39-41] Despite the promising results of these studies, no large-scale studies have been performed so far to establish its potential for identifying pre-invasive lesions.^[42]

MOLECULAR MARKERS

An escalating number of potential molecular markers for diagnosis as well as prognosis have been added by recent research, but none of them could be moved to clinical practice. Tissue-based studies have revealed several epigenetic modifications of different tumor suppressor genes, gene mutation, and differential expression of several proteins and microRNAs of invasive and pre-invasive lung tissue lesions. Translational researchers have been facing many challenges, such as restricted access to early-stage tumor tissue samples and tumor heterogeneity and complexity. The development of biofluid-based early detection strategies could be encouraging for overcoming the limitation of tissue acquisition.

Exhaled breath condensate, sputum, peripheral blood and its components, and urine suggest the non-invasive utilization of more accessible specimens for analysis. Circulating tumor cells, altered cell-free DNA and RNA, mRNA, miRNA, proteins, peptides, and metabolites which are released into the extracellular microenvironment are potentially the detectable moieties in blood, enabling detection of changes in DNA methylation, DNA amplification, gene mutation, and gene expression. Recently, miRNA-based studies have been added to the panel in categorizing asymptomatic high-risk subjects for developing lung cancer. Many tumor-associated antigen targets have been identified in patient sera using high-throughput screening platforms, with the dearth of autoantibodies and the complexity of the blood proteome as the challenging aspects to be streamlined.^[43]

Sputum and urine are the other biofluids of research interest. Sputum cytology has been recognized as one of the lung cancer detection methods with the highest specificity (an average specificity of 99% from 16 studies involving >28,000 patients^[44] and an average sensitivity of 66%). Earlier our group reported a higher sensitivity and specificity for sputum cytology in the detection of lung cancer on a

retrospective analysis of 8690 samples in a tertiary cancer care hospital.^[45]

The abundance of diagnostic cells present in the sputum sample, the specimen collection method, the specimen preparation technique, and the expertise of the cytologist who is screening the specimen for abnormal cells were the significant factors responsible for the lower sensitivity observed in many of the studies. Furthermore, the major factor contributing to the variation in the sensitivity of sputum cytology appears to be that the number of tumor cells exfoliated to sputum from a small tumor may not be so higher.

A diverse set of sputum processing methods was compared by our study, and sputum processing using red preservative was found to be more effective in preserving cell morphology and removing the mucus from masking the morphology [Figure 1]. The liquid-based cytology preparation using mega funnel technique along with cell block study from a pooled sample of 3 consecutive days increased the sensitivity of sputum cytology than the conventional pick and smear alone.^[46] Sputum cytology is not only used for the detection of tumor cells alone; it is beneficial for the detection of dysplasia of squamous cells and atypia of glandular cells, the precursor lesions of two of the predominant lung cancers.^[47-49] Furthermore, our early reports have familiarized immunohistochemistry and other molecular techniques to supplement the morphological evaluation of cancer cell blocks as well as smears prepared from sputum samples [Figure 2].^[50] Sputum cytology has been suggested as an alternative to bypass the invasive biopsy procedure for differential diagnosis of lung adenocarcinoma.^[51]

Earlier in the 1980s, chest X-rays combined with sputum cytology have been failed as a screening method for lung cancer in many of the studies, probably because of the poor quality of samples and the poor processing techniques, further compounded by the lack of expertise to pick out a handful of abnormal cells among the very many numbers of normal cells and pulmonary macrophages and to differentiate

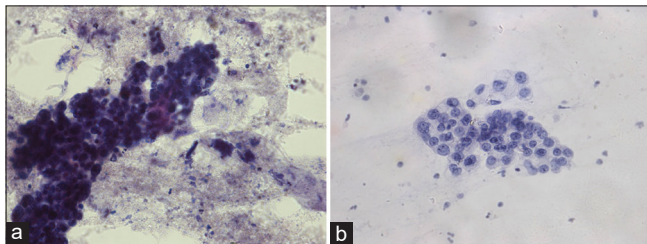


Figure 1: (a) PAP stained sputum sample processed in the conventional pick and smear technique showing a thick cluster of malignant cells ($\times 40$). Morphological details are masked by mucus and inflammatory debris. (b) PAP stained corresponding sputum sample processed in the modified technique showing malignant cells with clear nuclear and cytoplasmic details in a clear background ($\times 40$).

reactive and degenerative atypia from precancerous changes. The challenge today is to update and standardize sample collection and processing methodologies to attain constantly high sensitivities for sputum cytology in routine laboratory practice that would definitely improve the performance. Sample collection is the key to improving performance in sputum cytology. The number of sputum specimens analyzed per patient is the prime factor affecting the sensitivity. An increase in sensitivity from 68% to 85% was documented when three specimens were screened instead of one.^[52] Similarly, the analysis of pooled samples of 3 consecutive days was also found to be fruitful.^[49] Cell selection techniques such as magnetic-assisted cell sorting are reported to enrich epithelial cells in sputum >30 -fold.^[53]

Microscopic evaluation of pre-cancerous and malignant changes also demands substantial improvement. Numerous endeavors, including automation of analysis of malignancy associated changes (MAC) and digital analysis of sputum smears, are on consideration by researchers.^[54-59] A great majority of these studies have reported a high sensitivity. We have reported that analysis of glandular cells in sputum cytology images using scale-space features can help detect lung adenocarcinomas.^[60] Even though, demanding large-scale clinical trials, automated analysis for MAC is another promising area in which the textural features of DNA in the nuclei of apparently normal bronchial epithelial cells are measured to detect malignancy. Several reports on the significance of MAC supplementing conventional sputum cytology have been documented^[61,62] (Sudheesh *et al.*, in Proceedings of the 2016 IEEE Students technology

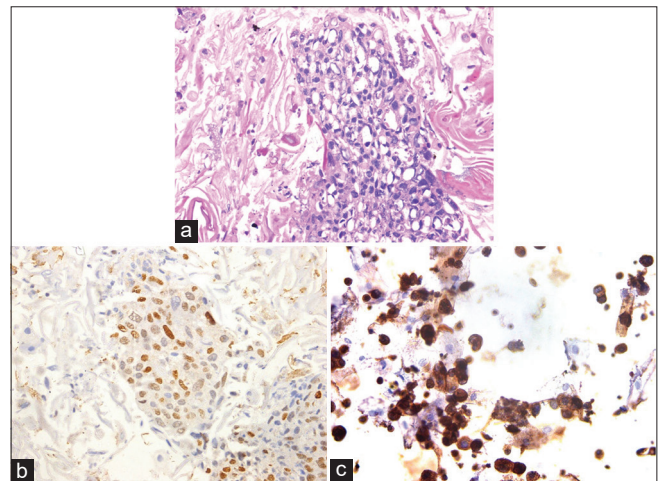


Figure 2: (a) H and E stained cell block of sputum processed in modified technique ($\times 40$) showing malignant cells. (b) Immunocytochemical staining (MCM 2) of sputum smear processed in modified technique showing malignant cells with nuclear expression ($\times 40$). (c) Immunocytochemical staining (MCM 2) sputum cell block sample prepared in modified technique showing nuclear staining of malignant cells in $\times 40$.

symposium), enabling to preselect high-risk people who require precise investigations such as CT.

Modern techniques share hands in overcoming the hurdles in increasing the sensitivity of sputum cytology. Several reports of sputum cytology with a sensitivity of >80% emphasize the importance of sputum cytology in the diagnostic field.^[44] Recent advances in technology have shown the possibility of advanced three dimensional cytometric analysis by combining flow cytometric analysis with CT scan on a cellular level.^[63,64] The next major query in using sputum cytology for lung cancer detection was the presence of premalignant and malignant cells in sputum in a detectable percentage. The earlier notion that tumor stage, type, and tumor location influence the shedding of tumor cells into sputum has clinically proved to be insignificant. Neumann *et al.* revealed that tumor mass sheds dysplastic, premalignant, and malignant cells into sputum irrespective of cancer type. Furthermore, they could find comparable frequency cancer cells other than dysplastic cells in the sputum of patients with different lung tumor subtypes.^[48]

Despite all these advantages, the potential of sputum analysis is yet to be fully exploited in routine clinical settings. Since sputum cytology is a non-invasive, easily repeatable, and highly sensitive approach, routine monitoring of the cellular contour of sputum from high-risk patients may be advantageous for prioritizing further imaging and invasive diagnostic workups.

SUMMARY

An era with sputum cytology as the gold standard for lung cancer detection

The current review highlights the significance of sputum cytology as a promising laboratory-based screening test for lung cancer using the modified processing method, which spares the cells for confirmatory molecular techniques. Identification of MAC will also supplement the diagnosis. Automated screening incorporating the morphological features, MAC, and molecular techniques will enable large-scale screening reliable. We hope that the review will pave a way for initiating sputum-based large-scale screening methods which may preselect high-risk people whom can be subjected to other imaging modalities.

COMPETING INTEREST STATEMENT BY ALL AUTHORS

There are no conflicts of interest.

AUTHORSHIP STATEMENT BY ALL AUTHORS

Each author has participated sufficiently in the work and takes responsibility for appropriate portions of the content

of this article. All authors read and approved the final manuscript.

ETHICS STATEMENT BY ALL AUTHORS

This study was approved by the Institutional Human Ethics Committee vide letter no. HEC 13/2019.

LIST OF ABBREVIATIONS (In alphabetic order)

AAH - Atypical Adenomatous Hyperplasia
 AIS - Adenocarcinoma *in situ*
 CIS - Carcinoma *in situ*
 CT - Computed Tomography
 DIPNECH - Diffuse Idiopathic Pulmonary Neuroendocrine Cell Hyperplasia
 LDCT - Low Dose Computed Tomography
 MAC - Malignancy Associated Changes
 NCI - National Cancer Institute
 NSCLC - Non-Small Cell Lung Carcinomas
 PET - Positron Emission Tomography
 SCLC - Small Cell Lung Cancers
 SD - Squamous Dysplasia.

EDITORIAL/PEERREVIEW STATEMENT

To ensure the integrity and highest quality of CytoJournal publications, the review process of this manuscript was conducted under a **double-blind model** (authors are blinded for reviewers and *vice versa*) through automatic online system.

FUNDING ACKNOWLEDGMENT

The authors would like to thank Council of Scientific & Industrial Research (CSIR) for financial support.

REFERENCES

1. Siddiqui F, Vaqar S, Siddiqui AH. Lung Cancer. In: StatPearls. Treasure Island: StatPearls Publishing; 2022. Available from: <https://www.ncbi.nlm.nih.gov/books/NBK482357> [Last accessed on 2021 Dec 08].
2. Barta JA, Powell CA, Wisnivesky JP. Global epidemiology of lung cancer. *Ann Glob Health* 2019;85:8.
3. Stewart BW, Wild CP. World Cancer Report 2014. France: IARC Publications; 2014.
4. Bray F, Ferlay J, Soerjomataram I, Siegel RL, Torre LA, Jemal A. Global cancer statistics 2018: GLOBOCAN estimates of incidence and mortality worldwide for 36 cancers in 185 countries. *CA Cancer J Clin* 2018;68:394-424.
5. Paoletti L, Jardin B, Carpenter MJ, Cummings KM, Silvestri GA. Current status of tobacco policy and control. *J Thorac Imaging* 2012;27:213-9.
6. Noronha V, Dikshit R, Raut N, Pramesh CS, Karimundackal G, Agarwal JP, *et al.* Epidemiology of lung cancer in India: Focus on the differences between non-smokers and smokers:

- A single-centre experience. *Indian J Cancer* 2012;49:74-81.
7. Shankar A, Saini D, Dubey A, Roy S, Bharati SJ, Singh N, *et al.* Feasibility of lung cancer screening in developing countries: Challenges, opportunities and way forward. *Transl Lung Cancer Res* 2019;8:S106-21.
 8. Chen W, Zheng R, Zhang S, Zeng H, Xia C, Zuo T, *et al.* Cancer incidence and mortality in China, 2013. *Cancer Lett* 2017;401:63-71.
 9. Henschke CI, Yankelevitz DF, Libby DM, Altorki N, Farooqi A, Hess J, *et al.* Survival of patients with Stage I lung cancer detected on CT screening. *N Engl J Med* 2006;355:1763-71.
 10. National Lung Screening Trial Research Team, Aberle DR, Adams AM, Berg CD, Black WC, Clapp JD, *et al.* National lung screening trial research team, reduced lung-cancer mortality with low-dose computed tomographic screening. *N Engl J Med* 2011;365:395-409.
 11. Kim S, Erwin D, Wu D. Efficacy of dual lung cancer screening by chest x-ray and sputum cytology using Johns Hopkins Lung Project Data. *J Biometrics Biostat* 2012;3:139.
 12. Kubík A, Polák J. Lung cancer detection. Results of a randomized prospective study in Czechoslovakia. *Cancer* 1986;57:2427-37.
 13. Giangreco A, Groot KR, Janes SM. Lung cancer and lung stem cells: Strange bedfellows? *Am J Respir Crit Care Med* 2007;175:547-53.
 14. Cooper WA, Lam DC, O'Toole SA, Minna JD. Molecular biology of lung cancer. *J Thorac Dis* 2013;5:S479-90.
 15. Denisov EV, Schegoleva AA, Gervas PA, Ponomaryova AA, Tashireva LA, Boyarko VV, *et al.* Premalignant lesions of squamous cell carcinoma of the lung: The molecular make-up and factors affecting their progression. *Lung Cancer* 2019;135:21-8.
 16. Xu X, Li N, Zhao R, Zhu L, Shao J, Zhang J. Targeted next-generation sequencing for analyzing the genetic alterations in atypical adenomatous hyperplasia and adenocarcinoma in situ. *J Cancer Res Clin Oncol* 2017;143:2447-53.
 17. Koo CW, Baliff JP, Torigian DA, Litzky LA, Gefter WB, Akers SR. Spectrum of pulmonary neuroendocrine cell proliferation: Diffuse idiopathic pulmonary neuroendocrine cell hyperplasia, tumorlet, and carcinoids. *AJR Am J Roentgenol* 2010;195:661-8.
 18. Kerr KM. Pulmonary preinvasive neoplasia. *J Clin Pathol* 2001;54:257-71.
 19. Sone S, Takshima S, Li F, Yang Z, Honda T, Maruyama Y, *et al.* Mass screening for lung cancer with mobile computed tomography scanner. *Lancet* 1998;351:1242-5.
 20. Addis BJ. Neuroendocrine differentiation in lung carcinoma. *Thorax* 1995;50:113.
 21. Aguyao SM, Miller YE, Waldron JA Jr., Bogin RM, Sunday ME, Staton GW Jr., *et al.* Brief report: Idiopathic diffuse hyperplasia of pulmonary neuroendocrine cells and airway disease. *N Engl J Med* 1992;327:1285-8.
 22. Mao L, Lee JS, Kurie JM, Fan YH, Lippman SM, Lee JJ, *et al.* Clonal genetic alterations in the lungs of current and former smokers. *J Natl Cancer Inst* 1997;89:857-62.
 23. Wistuba II, Lam S, Behrman C, Virmani AK, Fong KM, Samet JM, *et al.* Molecular damage in the bronchial epithelium of current and former smokers. *J Natl Cancer Inst* 1997;89:1366-73.
 24. Jeanmart M, Lantuejoul S, Fievet F, Moro D, Sturm N, Brambilla C, *et al.* Value of immunohistochemical markers in preinvasive bronchial lesions in risk assessment of lung cancer. *Clin Cancer Res* 2003;9:2195-203.
 25. Kalomenidis I, Orphanidou D, Papamichalis G, Vassilakopoulos T, Scorilas A, Rasidakis A, *et al.* Combined expression of p53, Bcl-2, and p21WAF-1 proteins in lung cancer and premalignant lesions: Association with clinical characteristics. *Lung* 2001;179:265-78.
 26. Greenberg AK, Yee H, Rom WN. Preneoplastic lesions of the lung. *Respir Res* 2002;3:20.
 27. Mori M, Rao SK, Popper HH, Cagle PT, Fraire AE. Atypical adenomatous hyperplasia of the lung: A probable forerunner in the development of adenocarcinoma of the lung. *Mod Pathol* 2001;14:72-84.
 28. Ashraf MJ, Maghbul M, Azarpira N, Khademi B. Expression of Ki67 and P53 in primary squamous cell carcinoma of the larynx. *Indian J Pathol Microbiol* 2010;53:661-5.
 29. Gazdar AF, Brambilla E. Preneoplasia of lung cancer. *Cancer Biomark* 2010;9:385-96.
 30. Berlin NI, Buncher CR, Fontana RS, Frost JK, Melamed MR. The national cancer institute cooperative early lung cancer detection program. Results of the initial screen (prevalence). Early lung cancer detection: Introduction. *Am Rev Respir Dis* 1984;130:545-9.
 31. Tockman MS. Survival and mortality from lung cancer in a screened population. *Chest* 1986;89:324-5.
 32. Fontana RS, Sanderson DR, Woolner LB, Taylor WF, Miller WE, Muhm JR, *et al.* Screening for lung cancer. A critique of the mayo lung project. *Cancer* 1991;67:1155-64.
 33. Hocking WG, Hum P, Oken MM, Winslow SD, Kvale PA, Prorok PC, *et al.* Screening by chest radiograph and lung cancer mortality: The prostate, lung, colorectal, and ovarian (PLCO) randomized trial. *JAMA* 2011;306:1865-73.
 34. Wille MM, Dirksen A, Ashraf H, Saghir Z, Bach KS, Brodersen J, *et al.* Results of the randomized danish lung cancer screening trial with focus on high-risk profiling. *Am J Respir Crit Care Med* 2016;193:542-51.
 35. Field JK, Duffy SW, Baldwin DR, Whynes DK, Devaraj A, Brain KE, *et al.* UK Lung cancer RCT pilot screening trial: Baseline findings from the screening arm provide evidence for the potential implementation of lung cancer screening. *Thorax* 2016;71:161-70.
 36. Blanchon T, Bréchet JM, Grenier PA, Ferretti GR, Lemarié E, Milleron B, *et al.* Baseline results of the Depiscan study: A French randomized pilot trial of lung cancer screening comparing low dose CT scan (LDCT) and chest X-ray (CXR). *Lung Cancer* 2007;58:50-8.
 37. Edell E, Lam S, Pass H, Miller YE, Sutedja T, Kennedy T, *et al.* Detection and localization of intraepithelial neoplasia and invasive carcinoma using fluorescence-reflectance bronchoscopy-an international, multicenter clinical trial. *J Thorac Oncol* 2009;4:49-54.
 38. Ernst A, Simoff MJ, Mathur PN, Yung RC, Beamis JF. D-light autofluorescence in the detection of premalignant airway changes: A multicenter trial. *J Bronchology Interv Pulmonol* 2005;12:133-8.

39. Chapman EA, Thomas PS, Stone E, Lewis C, Yates DH. A breath test for malignant mesothelioma using an electronic nose. *Eur Respir J* 2012;40:448-54.
40. Shlomi D, Abud M, Liron O, Bar J, Gai-Mor N, Ilouze M, *et al.* Detection of lung cancer and EGFR mutation by electronic nose system. *J Thorac Oncol* 2017;12:1544-51.
41. Van de Goor R, Van Hooren M, Dingemans AM, Kremer B, Kross K. Training and validating a portable electronic nose for lung cancer screening. *J Thorac Oncol* 2018;13:676-81.
42. Nardi-Agmon I, Peled N. Exhaled breath analysis for the early detection of lung cancer: Recent developments and future prospects. *Lung Cancer (Auckl)* 2017;8:31-8.
43. Hassanein M, Callison J, Callaway-Lane C, Aldrich MC, Grogan EL, Massion PP. The state of molecular biomarkers for the early detection of lung cancer. *Cancer Prev Res* 2012;5:992-1006.
44. Schreiber G, McCrory DC. Performance characteristics of different modalities for diagnosis of suspected lung cancer: Summary of published evidence. *Chest* 2003;123:115S-28.
45. Veena VS, George PS, Jayasree K, Sujathan K. Cytological analysis of sputum: The simplest and preliminary method of lung cancer diagnosis-a retrospective analysis of 8690 samples of symptomatic patients. *Int J Sci Res Public* 2012;2:1-6.
46. Veena VS, George PS, Jayasree K, Sujathan K. Comparative analysis of cell morphology in sputum samples homogenized with dithiothreitol, N-acetyl-L-cysteine, cytorich^(®) red preservative and in cellblock preparations to enhance the sensitivity of sputum cytology for the diagnosis of lung cancer. *Diagn Cytopathol* 2015;43:551-8.
47. Kennedy TC, Proudfoot SP, Franklin WA, Merrick TA, Saccomanno G, Corkill ME, *et al.* Cytopathological analysis of sputum in patients with airflow obstruction and significant smoking histories. *Cancer Res* 1996;56:4673-8.
48. Neumann T, Meyer M, Patten FW, Johnson FL, Erozan YS, Frable WJ, *et al.* Premalignant and malignant cells in sputum from lung cancer patients. *Cancer* 2009;117:473-81.
49. Veena VS, Rajan D, Saritha VN, George PS, Chandramohan K, Jayasree K, *et al.* The significance of DNA replication licensing proteins for early detection of lung cancer. *Asian Pac J Cancer Prev* 2017;18:3041-7.
50. Veena VS, George PS, Rajan K, Chandramohan K, Jayasree K, Sujathan K. Immunocytochemistry on sputum samples predicts prognosis of lung cancer. *J Cytol* 2019;36:38-43.
51. Veena VS, Saritha VN, George PS, Rajan K, Jayasree K, Sujathan K. Immuno expression of TTF1 and p63 differentiates lung adenocarcinomas in sputum samples. *J Cytol* 2021;38:151-7.
52. Bocking A, Adler CP, Common HH, Hilgarth M, Granzen B, Auffermann W. Algorithm for a DNA-cytophotometric diagnosis and grading of malignancy. *Anal Quant Cytol* 1984;6:1-8.
53. Qiu Q, Todd NW, Li R, Peng H, Liu Z, Yfantis HG, *et al.* Magnetic enrichment of bronchial epithelial cells from sputum for lung cancer diagnosis. *Cancer* 2008;114:275-83.
54. Hoda RS, Saccomanno G, Schreiber K, Decker D, Koss LG. Automated sputum screening with PAPNET system: A study of 122 cases. *Hum Pathol* 1996;27:656-9.
55. Bocking A, Biesterfeld S, Chatelain R, Gien-Gerlach G, Esser E. Diagnosis of bronchial carcinoma on sections of paraffin-embedded sputum. Sensitivity and specificity of an alternative to routine cytology. *Acta Cytol* 1992;36:37-47.
56. Xing S, Khanavkar B, Nakhosteen JA, Atay Z, Jockel KH, Marek W, *et al.* Predictive value of image cytometry for diagnosis of lung cancer in heavy smokers. *Eur Respir J* 2005;25:956-63.
57. Palcic B, Garner DM, Beveridge J, Sun XR, Doudkine A, MacAulay C, *et al.* Increase of sensitivity of sputum cytology using high-resolution image cytometry: Field study results. *Cytometry* 2002;50:168-76.
58. Kemp RA, Reinders DM, Turic B. Detection of lung cancer by automated sputum cytometry. *J Thorac Oncol* 2007;2:993-1000.
59. Katz RL, Zaidi TM, Fernandez RL, Zhang J, He W, Acosta C, *et al.* Automated detection of genetic abnormalities combined with cytology in sputum is a sensitive predictor of lung cancer. *Mod Pathol* 2008;21:950-60.
60. Kecheril S, Venkataraman D, Suganthi J, Sujathan K. Segmentation of lung glandular cells using multiple color spaces. *Int J Comput Sci Eng Appl* 2012;2:147-58.
61. Bejnordi BE, Moshavegh R, Sujathan K, Malm P, Bengtsson E, Mehnert A. Novel chromatin texture features for the classification of pap smears. In: Gurcan MN, Madabhushi A, editors. *Medical Imaging 2013: Digital Pathology*. Vol. 8676 867608-1. Bellingham: Proceeding of SPIE; 2013.
62. Sudheesh RK, Rajan J, Veena VS, Sujathan K. Study of Malignancy Associated Changes in Sputum Images as an Indicator of Lung Cancer. In: *Proceedings of the 2016 IEEE Students Technology Symposium* held at IIT, Kharagpur; 2016. p. 237.
63. Fauver M, Seibel EJ, Rahn JR, Meyer MG, Patten FW, Neumann T, *et al.* Three-dimensional imaging of single isolated cell nuclei using optical projection tomography. *Opt Express* 2005;13:4210-23.
64. Meyer MG, Fauver M, Rahn JR, Neumann T, Patten FW, Seibel EJ, *et al.* Automated cell analysis in 2D and 3D: A comparative study. *Pattern Recognit* 2009;42:141-6.

How to cite this article: Panakkal N, Lekshmi A, Saraswathy VV, Sujathan K. Effective lung cancer control: An unaccomplished challenge in cancer research. *CytoJournal* 2023;20:16.

HTML of this article is available FREE at:
https://dx.doi.org/10.25259/Cytojournal_36_2022

The FIRST Open Access cytopathology journal

Publish in *CytoJournal* and RETAIN your copyright for your intellectual property

Become Cytopathology Foundation Member to get all the benefits

Annual membership fee is nominal US \$ 50 (US \$ 1000 for life)

In case of economic hardship it is free

For details visit <https://cytojournal.com/cf-member>

PubMed indexed

FREE world wide open access

Online processing with rapid turnaround time.

Real time dissemination of time-sensitive technology.

Publishes as many colored high-resolution images

Read it, cite it, bookmark it, use RSS feed, & many----



CYTOJOURNAL

www.cytojournal.com

Peer-reviewed academic cytopathology journal





NextGen CelBloking™ Kits

**Frustrated with your cell blocks?
We have a better solution!**

Nano

Nano NextGen CelBloking™

Cell block kit to process single scattered cell specimens and tissue fragments of **any** cellularity.



PATENT PENDING



Pack #1



Pack #2


Micro

Micro NextGen CelBloking™

For cellular specimens (more than 1 ml concentrated specimen with Tissuecrit more than 50%)



PATENT PENDING



Pack #2

www.AVBioInnovation.com