




Quiz Case

An extremely rare case of axillary accessory breast swelling with uncommon association of methicillin-resistant *Staphylococcus aureus*

Priyanka Gautam, MD (Pathology)¹, Anshi Singh, MD (Pathology)¹, Divya Singh, MD (Pathology)¹ , Vikas Shrivastava, MD (Pathology)¹, Mukul Singh, MS (Surgery)², Vivek Hada, MD (Microbiology)³, Brijnandan Gupta, MD (Pathology)¹

Departments of ¹Pathology, ²Surgery and ³Microbiology, All India Institute of Medical Science, Gorakhpur, Uttar Pradesh, India.



***Corresponding author:**
Brijnandan Gupta,
Department of Pathology,
All India Institute of Medical
Science, Gorakhpur,
Uttar Pradesh, India.
brij9890470@gmail.com

Received : 12 November 2022
Accepted : 08 June 2023
Published : 08 August 2023

DOI
10.25259/Cytojournal_53_2022

Quick Response Code:



A 34-year-old female presented to the surgery department with persistent nodular left axillary swelling and pain for 15 days. A fine needle aspiration biopsy was performed from the left axilla and image of the smear is depicted below.

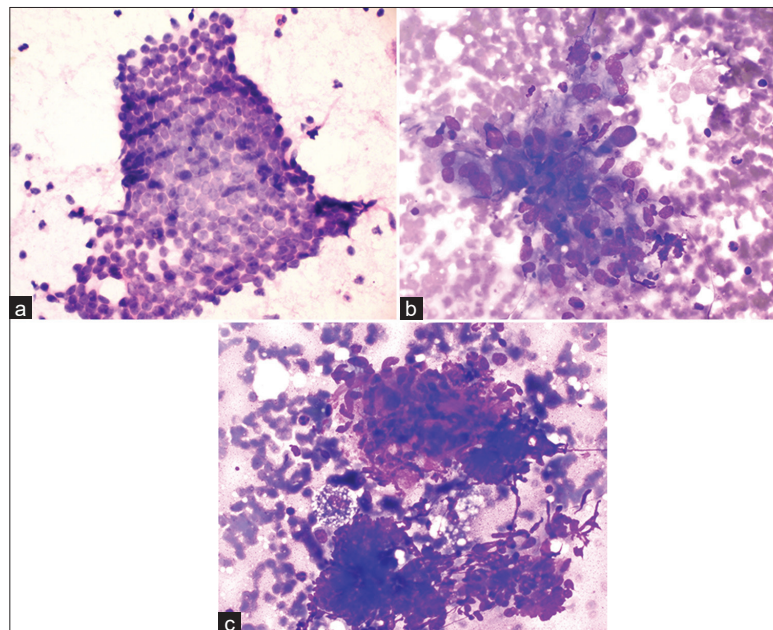


Figure 1: (a-c) Fine needle aspirate biopsy smear from left axillary swelling stained with papanicolaou and may-grunwald-giemsa stain.

QUESTION

Q1. What is the interpretation/diagnosis?

- Breast carcinoma
- Granulomatous mastitis (GM) in accessory axillary breast
- Fibrocystic change
- Phyllodes tumor.

ANSWER

b- GM in accessory axillary breast.

EXPLANATION

Cytological findings showed cellular aspirate with sheets of benign ductal epithelial cells, few non-necrotizing epithelioid cell granulomas, numerous foamy macrophages, neutrophils, and multinucleated giant cells showing emperipolesis [Figures 1a-c]. Ziehl-Neelsen stain and TrueNat for acid-fast bacilli were also performed which was negative, excluding Tuberculosis. Based on cytological findings, the diagnosis of GM in the accessory axillary breast was considered. Methicillin-resistant *Staphylococcus aureus* was later isolated in the bacterial culture performed on aspirate sample. Following the administration of antibiotics, the lesion significantly improved.

ADDITIONAL QUIZ QUESTIONS**Q2. Which of the following is true about GM?**

- Usually occurs in women of reproductive age, and most cases occur around 2 years after breastfeeding
- Malignant disease of the breast
- It is an untreatable condition
- None.

Q3. Which of the following disease is reported in the accessory breast?

- Phyllodes
- Mastitis
- Fibroadenoma
- All of the above.

Q4. What are the other granulomatous diseases of the breast?

- Tuberculous mastitis
- Sarcoidosis
- Both
- Galactocele.

ANSWERS TO ADDITIONAL QUIZ QUESTIONS

Answers: Q2-a, Q3-d, Q4-c.

BRIEF REVIEW OF THE TOPIC

GM is an unusual chronic inflammatory condition of the breast that is characterized by breast masses, erythema, abscesses, indurations, and tenderness. It usually occurs in pregnant women within 5 years of giving birth.^[1] GM was described as a distinct entity in 1972 by Kessler and Wolloch.^[2] In general, accessory breast tissue extends from the axilla to the pubic area

along the embryonic mammary ridge.^[3] The disease processes that affect accessory breast tissue are similar to those that affect normal breast tissue. The most frequent diseases reported in the accessory breasts are cancers followed by mastitis, fibroadenoma, phyllodes tumors, and fibrocystic change.^[4] The majority of cases of GM occur within the first 2 years after breastfeeding, while GM during pregnancy is rare.^[5] Idiopathic GM manifests histologically as non-caseating granulomas and is chronic, rare, and inflammatory. Typically, it presents as an inflamed, tender mass on the breast.^[6] In our case, the patient had given birth to her first child 3 years ago, and there was no history of breast trauma/use of oral contraceptives/any family history of breast cancer. Clinical examination revealed a tender swelling of approximately 1.5 cm in size with redness in the left axilla. Ultrasonography findings were suggestive of left axillary lymphadenitis. The patient was exposed to a number of risk factors, including delivery and breastfeeding, which both contribute to GM and accessory breast tissue formation.^[6,7] The diagnosis of GM remains challenging for clinicians. Cytological examination of fine-needle aspiration biopsy can ensure the diagnosis of this disease, despite the fact that it often mimics breast cancer.^[8] Patients with GM are often subject to prolonged disease courses with substantial negative impacts on quality of life during diagnosis and treatment. Therefore, diagnosing and treating them remain a challenge for clinicians as well as patients. To the best of our knowledge, till date, only two other cases of GM in accessory breast tissue have been reported in the literature. At present, there is no consensus regarding the etiology and management of GM.^[9] In our case, the patient was treated with oral antibiotics and the patient's condition improved.

SUMMARY

The diagnosis of GM on the accessory axillary breast should be considered in women with pain and swelling along the milk line and having recent history of delivery and breastfeeding. As far as GM is concerned, there is no standard management approach. Therefore, treatment strategies should be tailored to the needs of each patient.

COMPETING INTEREST STATEMENT BY ALL AUTHORS

The authors declare that they have no competing interests.

AUTHORSHIP STATEMENT BY ALL AUTHORS

Each author has participated sufficiently in the work and takes public responsibility for appropriate portions of the content of this article. All authors read and approved the final manuscript. Each author acknowledges that this final version was read and approved.

ETHICS STATEMENT BY ALL AUTHORS

As this is case without identifiers, our institution does not require approval from the Institutional Review Board (IRB).

LIST OF ABBREVIATIONS (In alphabetic order)

FNAC – Fine needle aspiration cytology

GM – Granulomatous Mastitis

MGG – May-Grunwald-Giemsa

USG – Ultrasonography

EDITORIAL/PEER-REVIEW STATEMENT

To ensure the integrity and highest quality of CytoJournal publications, the review process of this manuscript was conducted under a **double-blind model** (the authors are blinded for reviewers and vice versa) through automatic online system.

REFERENCES

1. Brown KL, Tang PH. Postlactational tumoral granulomatous mastitis: A localized immune phenomenon. *Am J Surg* 1979;138:326-9.
2. Kessler E, Wolloch Y. Granulomatous mastitis: A lesion clinically simulating carcinoma. *Am J Clin Pathol* 1972;58:642-6.
3. Bartsich SA, Ofodile FA. Accessory breast tissue in the axilla: Classification and treatment. *Plast Reconstr Surg* 2011;128:35e-6.
4. Pfeifer JD, Barr RJ, Wick MR. Ectopic breast tissue and breast-like sweat gland metaplasias: An overlapping spectrum of lesions. *J Cutan Pathol* 1999;26:190-6.
5. Wolfrum A, Kümmel S, Theuerkauf I, Pelz E, Reinisch M. Granulomatous mastitis: A therapeutic and diagnostic challenge. *Breast Care (Basel)* 2018;13:413-8.
6. Lai EC, Chan WC, Ma TK, Tang AP, Poon CS, Leong HT. The

role of conservative treatment in idiopathic granulomatous mastitis. *Breast J* 2005;6:454-6.

7. Khanna S, Mishra SP, Kumar S, Khanna AK. Carcinoma in accessory axillary breast. *BMJ Case Rep* 2015;2015:bcr2015210944.
8. Macansh S, Greenberg M, Barraclough B, Pacey F. Fine needle aspiration cytology of granulomatous mastitis. Report of a case and review of the literature. *Acta Cytol* 1990;34:38-42.
9. Freeman M, Lewis CD, Lower E, Khan S, Shaughnessy E. Refractory granulomas of breast: Benign or malignant disease. *J Clin Oncol* 2014;32 Suppl 26:21.

How to cite this article: Gautam P, Singh A, Singh D, Shrivastava V, Singh M, Hada V, *et al.* An extremely rare case of axillary accessory breast swelling with uncommon association of methicillin-resistant *Staphylococcus aureus*. *CytoJournal* 2023;20:17.

HTML of this article is available FREE at:

https://dx.doi.org/10.25259/Cytojournal_53_2022

The FIRST **Open Access** cytopathology journal

Publish in *CytoJournal* and **RETAIN** your *copyright* for your intellectual property

Become Cytopathology Foundation Member to get all the benefits
Annual membership fee is nominal US \$ 50 (US \$ 1000 for life)

In case of economic hardship it is free

For details visit <https://cytojournal.com/cf-member>

PubMed indexed

FREE world wide open access

Online processing with rapid turnaround time.

Real time dissemination of time-sensitive technology.

Publishes as many **colored high-resolution images**

Read it, cite it, bookmark it, use RSS feed, & many----



CYTOJOURNAL

www.cytojournal.com

Peer-reviewed academic cytopathology journal





NextGen CelBloking™ Kits

**Frustrated with your cell blocks?
We have a better solution!**

Nano

Nano NextGen CelBloking™

Cell block kit to process single scattered cell specimens and tissue fragments of **any** cellularity.



PATENT PENDING



Pack #1



Pack #2

Micro

Micro NextGen CelBloking™

For cellular specimens (more than 1 ml concentrated specimen with Tissuecrit more than 50%)



PATENT PENDING



Pack #2