



Research Article

Cytopathologic features of epithelioid hemangioendothelioma including touch imprints for rapid on-site evaluation

Mega Lahori, MD,¹ Amir Deghani, MD,¹ Christina Wilson, BS,¹ Wyanne Law, MD,² Narasimhan Agaram, MD,¹ Rajmohan Murali, MBBS, MD, FRCPA,¹ Carlie Sigel, MD,¹

¹Department of Pathology and Laboratory Medicine, Memorial Sloan Kettering Cancer Center, New York, United States.

²Department of Radiology, Memorial Sloan Kettering Cancer Center, New York, United States.



*Corresponding author:

Carlie Sigel,
Department of Pathology and
Laboratory Medicine, Memorial
Sloan Kettering Cancer Center,
New York, United States.

sigelc@mskcc.org

Received: 01 December 2022

Accepted: 20 June 2023

Published: 04 September 2023

DOI

10.25259/Cytojournal_57_2022

Quick Response Code:



ABSTRACT

Objectives: Epithelioid hemangioendothelioma (EHE) is a vascular tumor of intermediate malignant potential, which presents as infiltrative lesions involving multiple organs. We reviewed our institutional experience with the cytologic diagnosis of this neoplasm including the performance of rapid on-site evaluation (ROSE).

Material and Methods: From our institutional database, we identified 29 cytology specimens, obtained between 2012 and 2020, from 21 patients with biopsy confirmation of EHE. ROSE and final diagnosis were compared. All cytology slides were reviewed, and selected cytologic features were recorded.

Results: The cohort included 29 specimens comprising 17 (59%) from liver, 6 (21%) from lung, 2 (7%) from lymph node, and 4 (14%) from other sites. At ROSE, 8/27 (30%) were reported inadequate, yet on review, all cases contained scattered cells typical of EHE in the touch imprint air-dried slides including two cases reported with a final diagnosis of non-diagnostic. All cases contained epithelioid and plasmacytoid cells with ovoid nuclei, fine chromatin, delicate (or biphasic) cytoplasm, and scattered cells with delicate, elongated cytoplasmic tails. The majority 26/29 (90%) of cases had multi-nucleated and multi-lobated nuclei. Intracytoplasmic lumens/blister cells were in 17/29 (59%), and a subset had erythrocytes therein (4/29, 14%). Metachromatic fibromyxoid or fibrotic stroma fragments were commonly seen (23/29, 79%). Mitoses and necrosis were absent in all cases. Of 11 tested cases, *WWTR1::CAMTA1* and *YAPI::TFE3* fusions were detected in nine and two cases, respectively.

Conclusion: EHE has distinctive cytologic features which are often under-recognized during ROSE.

Keywords: Epithelioid hemangioendothelioma, Liver, Cytology, Rapid on-site evaluation

INTRODUCTION

Epithelioid hemangioendothelioma (EHE) is a rare vascular tumor of intermediate malignant potential, which presents as infiltrative lesions involving multiple organs such as liver, lung, soft tissue, lymph nodes, and bone. The histologic appearance of EHE is distinctive, consisting of epithelioid cells in a myxochondroid or sclerotic stroma. Yet, cytology descriptive reports and series are limited.^[1-4] In practice, we observed preliminarily that EHE specimens could be hypocellular or contained tumor cells sharing features with the background benign cells such as hepatocytes (in liver), histiocytes or pneumocytes (in lung), and mesothelial cells (in pleural fluid). Our hypothesis was that EHE could be missed or underrecognized on cytology touch

preparations (TP) and fine-needle aspirations (FNA) during rapid on-site evaluation (ROSE). Since this tumor is often multifocal and unresectable, sufficient diagnostic material must be obtained to distinguish EHE from other vascular neoplasms using immunohistochemistry or methods to detect recurrent translocations (*WWTR1::CAMTA1* and *YAP::TFE3*). Therefore, we retrospectively reviewed cytology specimens containing EHE to assess the correlation of adequacy at ROSE with the final diagnosis at our institution and describe EHE cytological features in our cohort.

MATERIAL AND METHODS

We searched our institutional database for histologically confirmed EHE, identified 29 cytology specimens received between 2012 and 2021 (from 23 patients), and retrieved the archived specimens. The radiologist who contributed to the study who was in the list of authors for the approved revision. The name has been added to the sites where authors are listed. Clinical and radiographical data were collected and available scans were reviewed retrospectively by a radiologist (WL) including evaluation for the lollipop sign, as defined by a hypovascular mass with peripheral enhancement, and a hepatic or portal venous branch terminating at the edge of the lesion. Air-dried smears or air-dried TP from core biopsy stained with Romanowsky (Diff-Quik) stain, alcohol-fixed smears stained with Papanicolaou stain, cytospin slides (fixed in Carnoy solution at a 3:1 ratio of 95% ethanol and glacial acetic acid) stained with Papanicolaou stain, and cell block sections stained with hematoxylin and eosin were the most common cytology materials reviewed. Routine practice is such that TPs were prepared by the radiologist obtaining the core biopsy followed by a needle rinse (TP+NR) in Cytolyt® (Hologic, Marlborough, Massachusetts, USA) subsequently prepared as a Thinprep® slide (Hologic, Marlborough, Massachusetts, USA). Documentation of the routinely assessed ROSE result as “adequate” or “inadequate” was recorded from the pathology report. Routine assessment of ROSE for specimens from 2012 to 2015 was performed by a cytotechnologist on-site and for specimens from 2015 to 2021 was performed by an on-site cytotechnologist and cytopathologist through a telecytology system (Remote Medical Technologies, Melville, NY, USA).

All cytology slides were retrospectively reviewed. Cytologic features evaluated included: Cellularity; cytoarchitecture; background cells; presence of stroma; cell shape; molding; cytoplasm texture (delicate or biphasic [dense perinuclear zone and fine outer zone]), volume; shape/processes; intracytoplasmic lumina/blister cells; intracytoplasmic red blood cells; nuclear features; mitoses; and necrosis. Clinical information was obtained from the digital institutional healthcare information system. Concurrent histologic specimens and existing immunohistochemistry from either

core biopsy (generally performed concurrently with the FNA) or subsequent tumor resection were also reviewed. Immunocytochemistry for CAMTA1 using a rabbit polyclonal antibody (NBP1-93620, dilution 1:250 (0.4 µg/mL), Novus biologicals, Centennial, Colorado, USA) was performed on cytology specimens with adequate material for this study. The stain was performed on the Leica-3 auto staining system (Leica, Deer Park, IL) using heat-based antigen retrieval, a high pH buffer solution (AR9640; Leica, Bond Epitope Retrieval Solution 2, 30 min), 30 min primary incubation time, and a polymer detection system (DS9800; Leica Bond Polymer Refine Detection). Results of prior Archer FusionPlex Custom Solid Panel testing® (ArcherDX, Inc., Boulder, Colorado, USA) were recorded if available. This study was approved by the Institutional Review Board, and the need for informed consent was waived due to the retrospective nature of the study.

RESULTS

We included 29 cytology cases containing EHE from 23 patients (13 women and 10 men). The median (interquartile range) patient age was 53 (16) years. The sites of the 29 tumors biopsied were from liver (17, 59%), lung (6, 21%), lymph node (2, 7%), and other sites (4, 14%). The liver tumors ranged in size from 1.3 to 7.3 cm. Radiographic data and scans for review were available for 12 patients with liver involvement. Limited hepatic radiographic features were assessed retrospectively and from most to least prevalent, including multi-focality (10/12, 83%), capsular retraction (5/12, 42%), and lollipop sign (5/12, 42%). None of these 12 patients had a lollipop sign reported prospectively.

The 29 cytology cases consisted of TP (7, 24%), TP+NR (14, 48%), FNA (2, 7%) TP+FNA (5, 17%), and pleural fluid (2, 7%) pleural fluids. The slide count per case ranged from 1 to 20 (median of 4 slides per case). Core biopsies were obtained concurrently for 23/29 (79%).

ROSE was performed in 27 cases on Diff Quik stained air-dried preparations except for the two pleural fluids. At ROSE, 8/27, 30% of cases were touch preps deemed non-diagnostic, with 5/27, 19% of cases deemed non-diagnostic at ROSE, were later diagnostic for EHE on final cytology diagnosis. Retrospectively, we identified cytologic evidence of EHE in the Diff-Quik stained air-dried preparations of all 27 cases, including two touch preps reported as inadequate at ROSE and non-diagnostic on final diagnosis. Cytomorphologically, the cases with an inadequate ROSE contained distinctive EHE cells, but they were scant, scattered, and singly distributed tumor cells with mild nuclear atypia. All 25 concurrent core biopsies, regardless of ROSE status, contained diagnostic material.

Table 1: Cytologic features of 29 cases of epithelioid hemangioendothelioma.

Cytologic feature	n (%)
Epithelioid and plasmacytoid cells	29 (100)
Delicate cytoplasm	29 (100)
Fine chromatin	29 (100)
Cells with long, tapering cytoplasm tails	29 (100)
Multi-nucleation	26 (90)
Multi-lobated nuclei	26 (90)
Moderate to abundant cellularity	19 (65)
Stroma fragments	23 (79)
Intranuclear inclusions	22 (76)
Cell molding	19 (66)
Nucleoli	18 (62)
Tumor cell clusters and single cells	17 (59)
Nuclear grooves	17 (59)
Large cells with biphasic cytoplasm	17 (59)
Blister cells	17 (59)
Single tumor cells present only	11 (38)
Red cells in intracytoplasmic lumens	4 (14)

A summary of the cytologic features is in [Table 1]. The most universal findings, occurring in all cases, including all touch imprints, were epithelioid and plasmacytoid cells with ovoid nuclei, fine chromatin, delicate cytoplasm, and scattered cells with delicate, elongated cytoplasmic tails [Figure 1a and b]. Intranuclear inclusions were commonly seen [Figure 1c]. The distinctive EHE cell type, the blister cell [large cells with rigid intracytoplasmic lumina, sometimes containing erythrocytes Figure 1d-f] was seen in only half of cases. EHE stroma, which can be prominent in histology, in cytology appeared branching with admixed tumor cells, in fragments with frayed edges, or small clumps in association with tumor cell clusters, or large acellular blobs [Figure 1g]. The nuclei seen in EHE cells were ovoid and 2–3 times the size of a resting hepatocyte nucleus [Figure 1h and i].

Immunohistochemical staining had been previously performed on concurrent core biopsy in 13 cases. Positive labeling for a vascular marker (CD31 and/or Factor VII and/or ERG) was seen in all cases. CAMTA immunohistochemistry was performed on three cytology cell block specimens, all with positive labeling.

Eleven of the 29 tumors had Archer FusionPlex testing (performed on corresponding core biopsies). *WWTR1::CAMTA1* fusion was detected in 9 (81%) patients

and *YAP1::TFE3* fusion was detected in 2 (19%) patients. No overt significant differences in morphology were noted in the two specimens with the *TFE3* fusion.

Representative case presentations

Case 1

A 60-year-old woman with elevated gamma-glutamyltransferase and multiple liver masses presented for diagnosis of presumed metastatic cancer. The lesions, up to 2.2 cm, demonstrated hypovascularity and focally an associated tapering vessel at the edge (lollipop sign) [Figure 2a]. Computed tomography (CT)-guided biopsies were deemed inadequate on-site. The FNA was non-diagnostic, containing hepatocytes only while the TP [Figure 2b] and needle rinse [Figure 2c] showed scattered atypical cells. The corresponding core biopsy had fibrosis and inflammatory changes. To achieve a definitive diagnosis, a repeat CT-guided TP of a core biopsy [Figure 2d] contained many loose aggregates of cells markedly enlarged compared to the background hepatocytes. The large epithelioid cells and irregularly spindled cells corresponded to cells on core biopsy labeling for ERG, CD31, and CD34 supporting the EHE diagnosis. The cell block contained blister cells and epithelioid cells [Figure 2e] weakly labeling with CAMTA immunohistochemistry [Figure 2f].

Case 2

A 66-year-old man with elevated alkaline phosphatase (445 U/L) had a solitary 6.2 cm liver mass with capsular retraction and lollipop sign [Figure 2g]. Although clinically suspected to be cholangiocarcinoma, a biopsy obtained at an outside hospital led to the resection and confirmation of EHE. A *WWTR1::CAMTA* fusion was confirmed. Multiple intrahepatic nodules suspicious for metastasis arose within 12 months. TPs from a CT-guided biopsy were adequate on-site due to scattered, large cells with abundant cytoplasm with irregular spindly processes [Figure 2h and i].

DISCUSSION

EHE is a challenging diagnosis in cytology due to its rarity and unusual multicentric presentation. We detected a ROSE non-diagnostic rate of 30%; yet, typical features of EHE were apparent in all touch imprints that we reviewed, even in the eight cases where the diagnostic cells were not confirmed at ROSE. Fortunately, all cases with concurrent core biopsies were diagnostic for EHE histology, regardless of the ROSE status. Possible reasons for the under-diagnosis of tumor cells at the time of rapid on-site adequacy include a lack of clinical suspicion and paucity of tumor cells relative to background cells such as hepatocytes, histiocytes, or

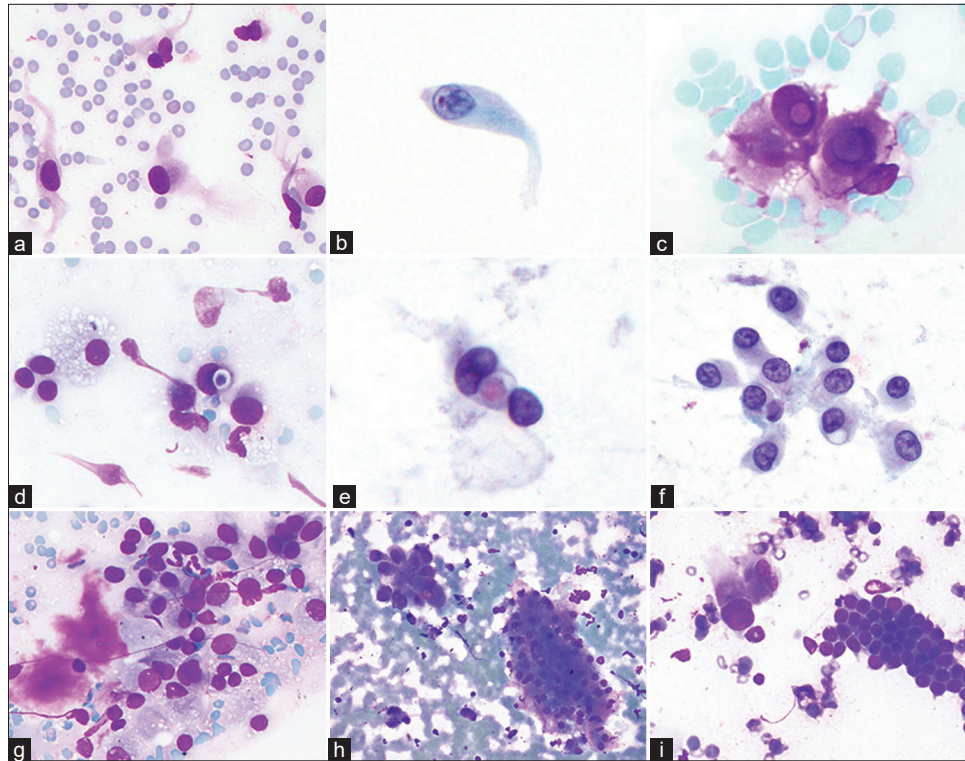


Figure 1: Epithelioid hemangioendothelioma cytologic features in touch imprints and fluid cytology (a and b), tumor cells with the characteristic long, tapering cytoplasmic processes (a: Diff Quik-touch imprint, b: Thinprep-pleural fluid); (c), intranuclear pseudo inclusions and biphasic (center dense, periphery delicate) cytoplasm, (d and e), blister cell with intracytoplasmic lumen containing an erythrocyte (d: Diff Quik touch imprint, e: Papanicolaou stain); (f), loosely cohesive cluster of tumor cells with intracytoplasmic lumen (Papanicolaou stain). (g), Metachromatic stroma with adjacent loosely cohesive cells with delicate cytoplasm (Diff Quik touch imprint); (h), tumor cells compared to cluster of hepatocytes (right) (Diff Quik touch imprint); and (i), large tumor cell with background benign bile duct cells (right) (Diff Quik touch imprint).

pneumocytes. Cellularity of aspirates is likely based on the zone within the tumor from which aspirate is taken, since EHEs show extensive hyalinosis, especially in the center, – which results in hypocellular aspirates. Aspirates from the peripheral proliferating, cell-rich zones of the tumor, are likely to be more cellular.^[5] Nonetheless, the stroma is an important component of EHE and possible clue to the diagnosis because it is characteristically present in cytology as basement membrane-like metachromatic material accompanying fragmented capillary structures in cytologic preparations [Figure 1g].^[6,7] Stroma can also be hyalinized, fibrotic, myxoid, fibromyxoid, or chondromyxoid and may be admixed with tumor cells.

The cytologic features of EHE were first described by Pettinato *et al.* in 1986.^[8] Subsequent case reports of FNA cytology have highlighted distinctive features including intracytoplasmic lumina (vacuoles) containing erythrocytes that distort or “blister” the cell contours.^[2] Our cohort elaborates on features described in the available literature.

We note that some of the typical cytologic features are seen as disproportionate to others. Commonly, EHE cells are described as plump epithelioid (or polygonal) cells with moderately abundant, dense cytoplasm. Other descriptions of the component cells include plasmacytoid,^[2,9,10] signet-ring,^[1,2] dendritic/stellate,^[6,8] and blister and histiocytoid.^[11] Classically, blister, dendritic/stellate, and spindle cells are said to be seen more readily in histology specimens, but we note that they can be seen in cytology, including touch imprints, but erythrocytes are rarely seen in the blister cells and this finding is shared with other cytology studies.^[1,2,6,12,13] Reliance on the presence of erythrocytes within intracytoplasmic lumens to make a cytologic diagnosis of EHE will potentially result in the tumor being overlooked on ROSE. Other features we described agree with prior studies such as well-defined cytoplasm,^[7] rounded, ovoid, bean-shaped/reniform nuclei,^[14] irregular nuclei,^[8,10] bi- or multi-nucleation,^[7,9,13,15] and mild-to-moderate anisonucleosis. Necrosis and mitoses are generally rare or absent,^[2,6,9,10] but exceptions have been reported.^[1,16] We did not observe unusual phenotypes

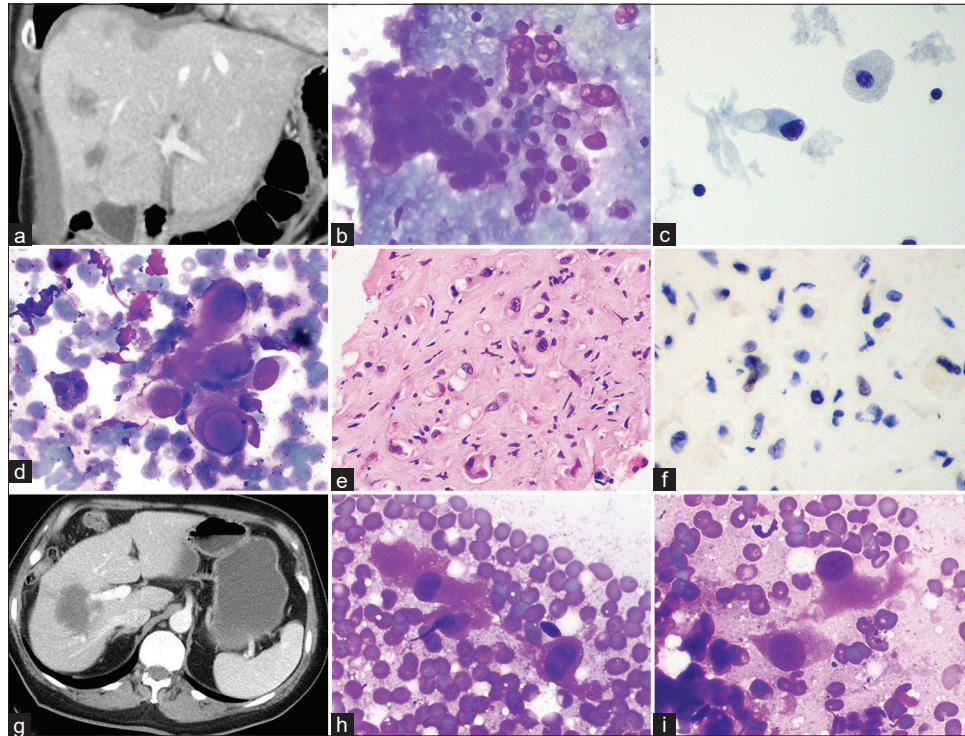


Figure 2: Case 1 (a-f). (a), CT scan with multiple nodules and focal lollipop sign. (b), Multinucleate cells adjacent to a cluster of hepatocytes (Diff Quik touch imprint). (c), blister cell on Thinprep on the left, hepatocyte on the right. (d), Cells dramatically larger than hepatocyte (left) with intranuclear inclusion (Diff Quik touch imprint). (e), Cellblock with intracytoplasmic lumens in a dense stroma. (f), CAMTA immunohistochemical staining labels scattered cells with large multi-lobed nuclei. Case 2 (g-i). (g), Computer tomography scan with lollipop sign. (h and i) Cells with irregular spindle processes (Diff Quik touch imprints).

previously described in the literature, including rhabdoid cells and, osteoclast-like giant cells.^[13] Intranuclear inclusions and intracytoplasmic lumens are often stated to be a distinctive characteristic of EHE cytology, but unlike the cells with long tapering processes, we note that they are not present in every case (76% of cases in this study; Figure 1c).

The radiologic presentation of EHE can be a clue to the diagnosis, but features vary among patients, such as capsular retraction, target-like enhancement, and the lollipop sign.^[17] We note that on retrospective review, 5/12 liver cases had evidence of a lollipop sign, but they were not reported prospectively, as many cancers were already biopsy-proven at the time of the scan, so there was less emphasis on the description of the tumor from the clinical standpoint.

The differential diagnoses of EHE vary depending on the site of the tumor. In liver, the differential includes benign reactive cells, hepatocellular carcinoma, hemangioma, angiosarcoma, and cholangiocarcinoma. In effusion fluids, benign mesothelial cells, mesothelioma, and adenocarcinoma are in the differential. In soft tissue, the list contains metastatic poorly differentiated carcinoma, signet-ring cell carcinoma, epithelioid angiosarcoma, pleomorphic

liposarcoma, melanoma, and granulation tissue.^[6,13] In [Table 2], we briefly note the common mimics of EHE and helpful cytologic features for distinguishing EHE. The so-called dendritic/stellate cells characterized by long tapering cytoplasm tails or processes, similar to a tadpole cell, are distinctive from background hepatocytes, pneumocytes, mesothelial cells, and histiocytes of liver, lung, pleural fluid, and lymphoid specimens, respectively.^[7,12] In addition, EHE cells lack the coarse nuclear chromatin and granular cytoplasm of reactive hepatocytes which also often contain lipofuscin pigment [Figure 1h]. Immunohistochemistry can help with the diagnosis. Notably, cytokeratin is focally expressed in 20–30% of EHE cases.^[18] Vascular markers, ERG, CD31, CD34, FLI-1, or Factor VIII-related antigens, are especially useful to confirm the diagnosis of EHE. Furthermore, EHE is characterized by a pathognomonic t (1;3) (p36.3;q25) translocation, which results in *WWTR1::CAMTA1* fusion (90% cases) (detected by CAMTA1 staining) or *YAPI::TFE3* fusion leading to overexpression of *TFE3*, which has unique clinical features.^[19,20] *TFE3* fusion-positive tumors are reported to be larger, have more well-formed vessels, greater nuclear

Table 2: Common mimics of EHE with cytologic features for the distinction between these entities.

Cell type	Cytomorphological description
Benign hepatocytes	Polygonal cells, round to ovoid nuclei with coarse chromatin and nucleoli, granular cytoplasm, intracytoplasmic pigment, generally 2–3× smaller than EHE cells
Histiocytes	Finely vacuolated “foamy” cytoplasm, cytoplasmic debris; reniform, round, or ovoid nucleus. No cytoplasmic tails or intranuclear inclusions
Mesothelial cells	Intercellular windows, “lacy-skirt” cytoplasmic rim, and large flat two-dimensional sheets
Poorly differentiated adenocarcinoma	Acinar clusters with community border, hyperchromatic nuclei, foamy or vacuolated cytoplasm, mucin, mitoses, and necrosis
Hepatocellular carcinoma	Cytoplasmic granularity, bile pigment, clusters with endothelial rimming, traversing vessels, and abundant naked nuclei within a granular background
Melanoma	Melanin pigment, cherry-red macronucleoli, mirror-image binucleation, necrosis, and severe pleomorphism
Mesothelioma	Hypercellular, morular cytoarchitecture, high n: c ratio, prominent nucleoli, and intercellular windows
Epithelioid angiosarcoma	Hypercellular smears, prominent mitotic activity, significant nuclear and nucleolar pleomorphism, hyperchromasia, apoptotic bodies, and foci of necrosis

EHE: Epithelioid hemangioendothelioma

atypia, and hypercellularity compared with *TFE3* fusion-negative tumors.^[19] With only 2 *YAP1::TFE3* fusions in our study, there were too few cases to determine unable to detect if the clinical features were in keeping with prior reports, and we could not do a differential comparison of the cytologic features of this molecular subtype.

SUMMARY

As Campione *et al.* have suggested, a diagnosis of EHE can be made with confidence on FNA and small biopsies when an adequate specimen is obtained, and the complete spectrum of the morphological findings is observed.^[12] A constellation of features helps in diagnosing cytology as EHE, with no single specific feature defining EHE, or numerical cut-off of cytologic features for diagnosing EHE. A combination of the following features in cytology samples should raise strong suspicion for EHE: predominantly dispersed single cells with occasional cohesive cell clusters; epithelioid and plasmacytoid cells with occasional elongated cytoplasmic tails, scattered cells with bi/multinucleation, blister cells (with or without red blood cells), biphasic cytoplasm, intranuclear inclusions, fibromyxoid stroma, and nuclear grooves. Spotting these features at the time of ROSE can provide assurance that the targeted lesion is sampled and permit the collection of material for molecular studies and/or immunohistochemistry.

COMPETING INTEREST STATEMENT BY ALL AUTHORS

The authors have no conflicts of interest or financial disclosures.

AUTHORSHIP STATEMENT BY ALL AUTHORS

Mega Lahori: Data collection, primary draft of manuscript. Amir Dehghani, Christina Wilson, and Wyanne Law: Data collection. Narasimhan Agaram and Rajmohan Murali: Editing of manuscript. Carlie Sigel: Study design, editing of manuscript, supervision.

ETHICS STATEMENT BY ALL AUTHORS

The study was approved by the Institutional Review Board of the study institution.

LIST OF ABBREVIATIONS (In alphabetic order)

CT - Computed tomography,
EHE - Epithelioid hemangioendothelioma,
FNA - Fine needle aspiration,
NR - Needle Rinse,
ROSE - Rapid on-site evaluation,
TP - Touch preparation.

EDITORIAL/PEERREVIEW STATEMENT

To ensure the integrity and highest quality of cytojournal publications, the review process of this manuscript was conducted under a **double-blind model** (authors are blinded for reviewers and vice versa) through the automatic online system.

REFERENCES

- Murali R, Zarka MA, Ocal IT, Tazelaar HD. Cytologic features of epithelioid hemangioendothelioma. *Am J Clin Pathol*

- 2011;136:739-46.
2. Chen Y, Chen JQ, Katz RL. Epithelioid hemangioendothelioma: A study of 14 cytopathology cases. *J Am Soc Cytopathol* 2015;4:148-59.
 3. Dail DH, Liebow AA, Gmelich JT, Friedman PJ, Miyai K, Myer W, *et al.* Intravascular, bronchiolar, and alveolar tumor of the lung (IVBAT). An analysis of twenty cases of a peculiar sclerosing endothelial tumor. *Cancer* 1983;51:452-64.
 4. Ishak KG, Sesterhenn IA, Goodman ZD, Rabin L, Stromeyer FW. Epithelioid hemangioendothelioma of the liver: A clinicopathologic and follow-up study of 32 cases. *Hum Pathol* 1984;15:839-52.
 5. Thangaiah JJ, Hanley K, Nomani L, Policarpio-Nicolas ML. Cytologic features and immunohistochemical findings of epithelioid hemangioendothelioma (EHE) in effusion: A case series. *Diagn Cytopathol* 2021;49:E24-30.
 6. Makhlof HR, Ishak KG, Goodman ZD. Epithelioid hemangioendothelioma of the liver: A clinicopathologic study of 137 cases. *Cancer* 1999;85:562-82.
 7. Errani C, Zhang L, Sung YS, Hajdu M, Singer S, Maki RG, *et al.* A novel WWTR1-CAMTA1 gene fusion is a consistent abnormality in epithelioid hemangioendothelioma of different anatomic sites. *Genes Chromosomes Cancer* 2011;50:644-53.
 8. Pettinato G, Insabato L, De Chiara A, Forestieri P, Manco A. Epithelioid hemangioendothelioma of soft tissue. Fine needle aspiration cytology, histology, electron microscopy and immunohistochemistry of a case. *Acta Cytol* 1986;30:194-200.
 9. Brimo F, Nahal A. Malignant epithelioid hemangioendothelioma with spindle phenotype: Report of an unusual case diagnosed by fine needle aspiration cytology. *Acta Cytol* 2008;52:721-4.
 10. Soslow R, Yin P, Steinberg C, Yang G. Cytopathologic features of hepatic epithelioid hemangioendothelioma. *Diagn Cytopathol* 1998;17:50-3.
 11. Rosai J, Gold J, Landy R. The histiocytoid hemangiomas. A unifying concept embracing several previously described entities of skin, soft tissue, large vessels, bone, and heart. *Hum Pathol* 1979;10:707-30.
 12. Campione S, Cozzolino I, Mainenti P, D'Alessandro V, Vetrani A, D'Armiento M. Hepatic epithelioid hemangioendothelioma: Pitfalls in the diagnosis on fine needle cytology and "small biopsy" and review of the literature. *Pathol Res Pract* 2015;211:702-5.
 13. Rosenberg A, Agulnik M. Epithelioid hemangioendothelioma: Update on diagnosis and treatment. *Curr Treat Options Oncol* 2018;19:19.
 14. Antonescu CR, Le Loarer F, Mosquera JM, Sboner A, Zhang L, Chen CL, *et al.* Novel YAP1-TFE3 fusion defines a distinct subset of epithelioid hemangioendothelioma. *Genes Chromosomes Cancer* 2013;52:775-84.
 15. Kilpatrick SE, Kopylay PD, Ward WG, Richards F 2nd. Epithelioid hemangioendothelioma of bone and soft tissue: A fine-needle aspiration biopsy study with histologic and immunohistochemical confirmation. *Diagn Cytopathol* 1998;19:38-43.
 16. Jarboe EA, Layfield LJ. Cytologic features of pancreatic intraepithelial neoplasia and pancreatitis: Potential pitfalls in the diagnosis of pancreatic ductal carcinoma. *Diagn Cytopathol* 2011;39:575-81.
 17. Tan H, Zhou R, Yu H, Teng F, Si S, Liu L, *et al.* CT appearances and classification of hepatic epithelioid hemangioendothelioma. *Insights Imaging* 2023;14:56.
 18. Nudo CG, Yoshida EM, Bain VG, Marleau D, Wong P, Marotta PJ, *et al.* Liver transplantation for hepatic epithelioid hemangioendothelioma: The Canadian multicentre experience. *Can J Gastroenterol* 2008;22:821-4.
 19. Iyer VK, Bandhu S, Verma K. An unusual mass lesion of the liver with distinctive cytology. *Cytopathology* 2004;15:233-6.
 20. Manucha V, Sun CC. Cytologic findings and differential diagnosis in hepatic epithelioid hemangioendothelioma: A case report. *Acta Cytol* 2008;52:713-7.

How to cite this article: Lahori M, Dehghani A, Wilson C, Law W, Agaram N, Muralim R, *et al.* Cytopathologic features of epithelioid hemangioendothelioma including touch imprints for rapid on-site evaluation. *CytoJournal* 2023;20:29.

HTML of this article is available FREE at:
https://dx.doi.org/10.25259/Cytojournal_57_2022

The FIRST Open Access cytopathology journal

Publish in *CytoJournal* and RETAIN your copyright for your intellectual property

Become **Cytopathology Foundation Member** to get all the benefits

Annual membership fee is nominal US \$ 50 (US \$ 1000 for life)

In case of economic hardship it is free

For details visit <https://cytojournal.com/cf-member>

PubMed indexed

FREE world wide open access

Online processing with rapid turnaround time.

Real time dissemination of time-sensitive technology.

Publishes as many colored high-resolution images

Read it, cite it, bookmark it, use RSS feed, & many----



CYTOJOURNAL

www.cytojournal.com

Peer-reviewed academic cytopathology journal





NextGen CelBloking™ Kits

**Frustrated with your cell blocks?
We have a better solution!**

Nano

Nano NextGen CelBloking™

Cell block kit to process single scattered cell specimens and tissue fragments of **any** cellularity.



PATENT PENDING



Pack #1



Pack #2

Micro

Micro NextGen CelBloking™

For cellular specimens (more than 1 ml concentrated specimen with Tissuecrit more than 50%)



PATENT PENDING



Pack #2