



Editor-in-Chief:

Miaoqing Zhao, PhD., MD (Shandong First Medical University, Jinan, China)

Co-editor-in-Chief:

Lester J. Layfield, MD, (University of Missouri, Columbia, MO, USA)

Founding Editor & Editor-in-chief Emeritus:

Vinod B. Shidham, MD, FIAC, FRCPath (WSU School of Medicine, Detroit, USA)



Quiz Case

Challenge in the cytological interpretation of a not-so-typical breast carcinoma

Femela Muniraj, MD, DNB, MNAMS, DipRCPath¹, , Sudha Srinivasan, MBBS, MD¹, , Vijayashree Raghavan, MBBS, MD¹

¹Department of Pathology, Chettinad Hospital and Research Institute, Chettinad Academy of Research and Education, Chengalpattu, Tamil Nadu, India.



*Corresponding author:

Sudha Srinivasan,
Department of Pathology,
Chettinad Hospital and
Research Institute, Chettinad
Academy of Research and
Education, Chengalpattu,
Tamil Nadu, India.

sudha15689@gmail.com

Received: 05 July 2023

Accepted: 09 November 2023

Published: 14 August 2024

DOI

10.25259/Cytojournal_43_2023

Quick Response Code:



A 52-year-old postmenopausal female presented with swelling in the right breast of size 4x3 cm. Consistency was hard and margins were ill-defined. The nipple was retracted and the skin over the swelling was fixed to it, showing ulceration and puckering. The tumor was fixed to the chest wall. A history of blood-mixed discharge from the ulcer was present. No axillary lymph nodes were palpable. Clinically the stage of the lesion was T_{4c}N₀M₀, Stage IIIB. Ultrasonography showed a solid cystic lesion in the breast which was reported as BIRADS IV and two subcentimetric lymph nodes were present in the right axilla. Fine-needle aspiration cytology (FNAC) smears showed predominantly sheets and clusters of cells with abundant vacuolated cytoplasm, along with clusters of epithelial cells that showed abundant eosinophilic cytoplasm. The background showed acute and chronic inflammatory cells, occasional giant histiocytes, bare nuclei, and proteinaceous material. Biopsy showed two populations of cells with sharply defined cell borders, one with abundant eosinophilic, periodic acid-schiff (PAS) positive, diastase resistant, granular cytoplasm, and the other with abundant vacuolated cytoplasm. The cells showed marked pleomorphism, vesicular nuclei, prominent nucleoli with brisk mitotic activity, and atypical mitosis. Subsequently modified radical mastectomy specimen confirmed the infiltrative nature of the tumor. The tumor cells were arranged in papillary, micropapillary, acinar and the tubular patterns, and solid sheets. Extensive necrosis, stromal desmoplastic reaction, acute and chronic inflammatory cells, and vascular tumor emboli were also found. No ductal carcinoma *in situ* (DCIS) component was noted. Nottingham's histologic score was 9 (Grade III). The skin over the swelling showed dermal infiltration by the tumor. The other resected margins were free of tumor. Eighteen axillary lymph nodes were harvested and two of them showed metastasis. The pathological stage was pT₃N_{1a}M_x. On immunohistochemical evaluation, estrogen receptor (ER) (Clone: EP1) and progesterone receptor (PR) (Clone: EP2) were negative. Human epidermal growth factor receptor 2 (HER2) (Clone: EP3) showed diffuse strong (3+) membranous positivity in the tumor cells. Ki-67 (Clone: MIB-1) (proliferation index) was 46%. Cytokeratin (CK) 5/6/8/18 (Clone: 5D3/LP34) showed diffuse strong membranous positivity in the tumor cells. Androgen receptor (AR) (Clone: EP120) was positive in the apocrine cells.

QUESTION # 1

What is the most likely diagnosis?

- Secretory carcinoma
- Oncocytic carcinoma
- Apocrine carcinoma
- Lipid-rich carcinoma

ANSWER

c. Apocrine carcinoma

EXPLANATION

The patient presented with features of invasive carcinoma of the breast and with skin ulceration. Fine needle Aspiration cytology (FNAC) smears predominantly showed cells with abundant vacuolated cytoplasm [Figure 1]. Biopsy showed two populations of cells with well-defined cytoplasmic borders; one with abundant eosinophilic cytoplasm with PAS-positive diastase-resistant granules, and the other with abundant vacuolated cytoplasm. The cells showed nuclear atypia, brisk mitotic activity, and atypical mitosis [Figure 2]. Two types of cells are seen in apocrine carcinoma. Type A cells have abundant eosinophilic granular cytoplasm, enlarged nuclei and the prominent nucleoli, and type B cells have abundant vacuolated cytoplasm with intracytoplasmic lipids. The type A cells are diastase-resistant and, the PAS-positive.^[1-7]

The diagnostic interpretation of apocrine carcinoma on cytology smears may be challenging due to its morphologic mimics. FNAC smears show large polygonal cells with abundant granular cytoplasm and sharply defined borders. The nuclei are vesicular, with irregular nuclear borders, and show prominent nucleoli.^[8] Predominance of type B cells in cytology smears poses difficulty in arriving at the diagnosis. This might be due to sampling error. In 2005, Japaze *et al.*,^[6] proposed the following criteria for diagnosing apocrine carcinoma: (i) 75% of tumor cells exhibiting apocrine features, (ii) large cells with granular eosinophilic cytoplasm, (iii) sharply defined cell borders, (iv) large, round, vesicular, may be the pleomorphic nucleus, and (v) low N: C ratio ($\leq 1:2$).^[6]

QUESTION # 2

Which of the following immunohistochemical marker is generally negative in apocrine carcinoma of breast?

- ER
- AR
- HER2
- GCDFP-15

ANSWER

a. ER

EXPLANATION

Apocrine carcinomas lack ER and PRs, Bcl-2, but have AR and express gross cystic disease fluid protein-15 (GCDFP-15), GATA binding protein 3, CK7, CK8, CK18, CK19, CK20, expression of MUC1 (EMA), and E-Cadherin. HER2/neu may or may not be positive. Basal cytokeratins such

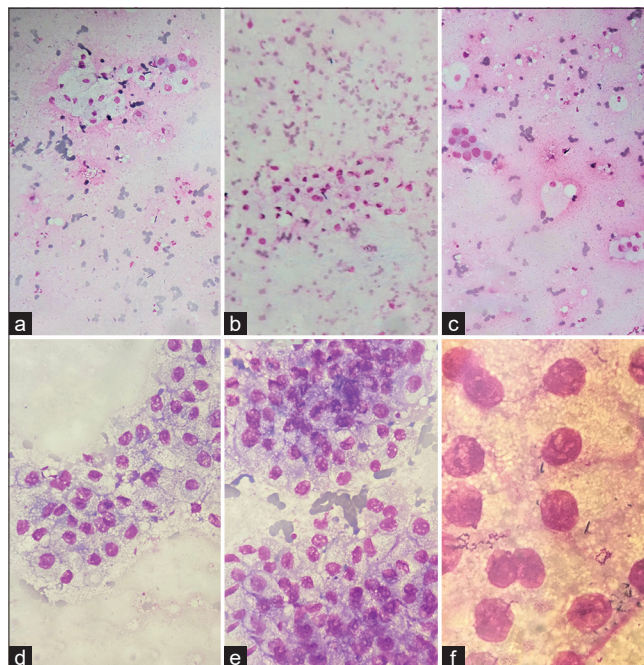


Figure 1: Microphotographs of the cytology smears (May Grunwald-Giemsa [MGG]): (a and b) (MGG, $\times 200$), Fine-needle aspiration cytology (FNAC) smears showing cells with vacuolated cytoplasm, (c) (MGG, $\times 200$) FNAC smear showing benign ductal epithelial cells with apocrine metaplasia along with the foamy cells, (d and e) (MGG, $\times 400$) Fine-needle aspiration cytology (FNAC) smears showing cells with vacuolated cytoplasm, (f) (MGG, $\times 1000$) Cells with well-defined cytoplasmic borders.

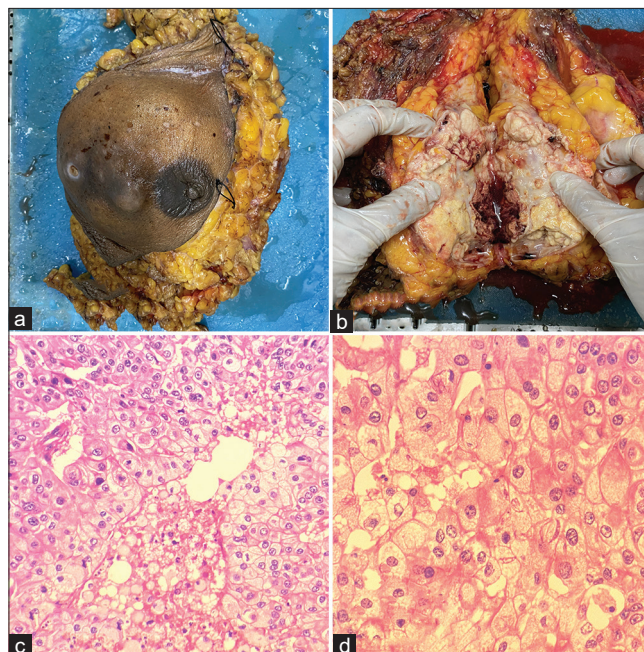


Figure 2: Gross and histopathology of the lesion: (a) Gross image of the modified radical mastectomy specimen, (b) Cut section of the tumor, (c) Histological section of the tumor (hematoxylin & eosin [H & E], $\times 200$), and (d) Section showing the cells with apocrine differentiation (H & E, $\times 400$).

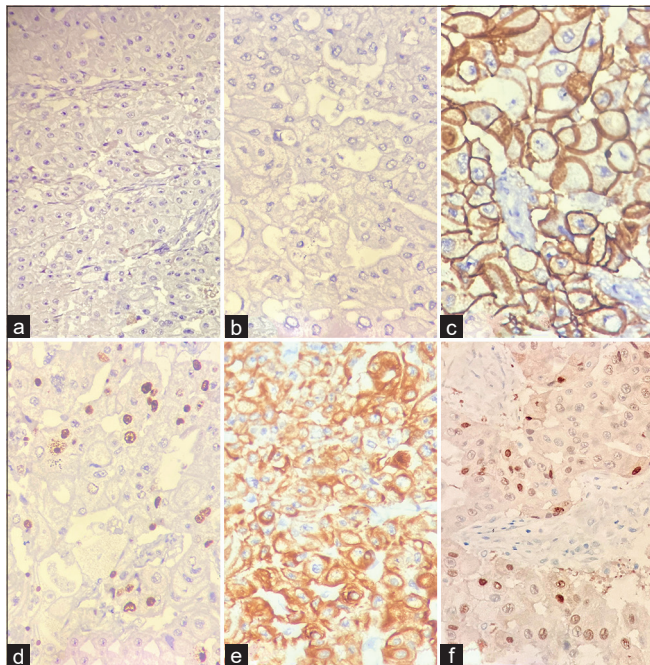


Figure 3: Immunohistochemistry of the tumor: (a) Estrogen receptor (ER) is negative in tumor cells (ER and Diaminobenzidine [DAB], $\times 200$), (b) Progesterone receptor (PR) is negative in tumor cells (PR and DAB, $\times 200$), (c) Human epidermal growth factor receptor 2 (HER2)/neu shows diffuse, strong membranous positivity (Grade 3+) (HER2 and DAB, $\times 200$), (d) Ki-67 (Proliferation marker) is positive in 46% of cells (Ki-67 and DAB, $\times 200$), (e) Cytokeratin (CK5/6/8/18): Strong cytoplasmic to membranous positivity in $>50\%$ of the cells (CK5/6/8/18 and DAB, $\times 200$), and (f) Androgen receptor is positive in the nuclei of cells with apocrine morphology (androgen receptor and DAB, $\times 200$).

as CK5/6, CK14, CK17, and p63 are variably positive. GCDFP is present in the breast cysts and in apocrine cells of mammary glands, salivary glands, sweat glands, Paget disease, etc. HER2/neu is positive in 30–60% of carcinomas with apocrine differentiation. GCDFP-15 and AR are considered the hallmarks of apocrine differentiation [Figure 3]. The expression of GCDFP-15 appears to be reduced in advanced apocrine carcinoma. In oncocytic carcinoma, ER, PR, and anti-mitochondrial antibodies are positive and AR and GCDFP-15 are negative.^[1-15] Hence, apocrine carcinomas have two molecular subtypes: Triple-negative and HER2-positive.^[10]

QUESTION # 3

To be designated as “Carcinoma with apocrine differentiation,” _____% of the tumor cells should have distinct apocrine morphology.

- 50%
- 25%
- 75%
- 90%

ANSWER

- 90%

EXPLANATION

To be designated as “Carcinoma with apocrine differentiation,” the distinct apocrine morphology should be evident in $>90\%$ of the cancer cells. Previously, the cutoff percentage of tumor cells had been defined as 75% by Japaze *et al.*, to be diagnosed as apocrine carcinoma^[1-4,9-12]

QUESTION # 4

Is apocrine carcinoma associated with BRCA 1 or 2?

- Yes
- No
- Not applicable
- Cannot be commented.

ANSWER

- No

EXPLANATION

Although loss of PTEN (Phosphatase and tensin homolog) function may indicate familial breast carcinoma, there is no association between apocrine carcinoma and BRCA1 or BRCA2.^[5]

QUESTION # 5

Which of the following breast carcinomas has a worse prognosis?

- Triple-negative invasive breast carcinoma of no special type
- Triple-negative invasive apocrine carcinoma
- Luminal A type breast carcinoma
- Luminal B type breast carcinoma

ANSWER

- Triple-negative invasive duct carcinoma of no special type

EXPLANATION

The triple-negative subtype of apocrine carcinoma of the breast has better prognosis than triple-negative invasive breast carcinoma of no special type (NST), as targeted therapy with drugs used in prostate carcinoma such as flutamide that inhibits androgen signaling, is available.^[1-6,11] The other two subtypes carry better prognosis.

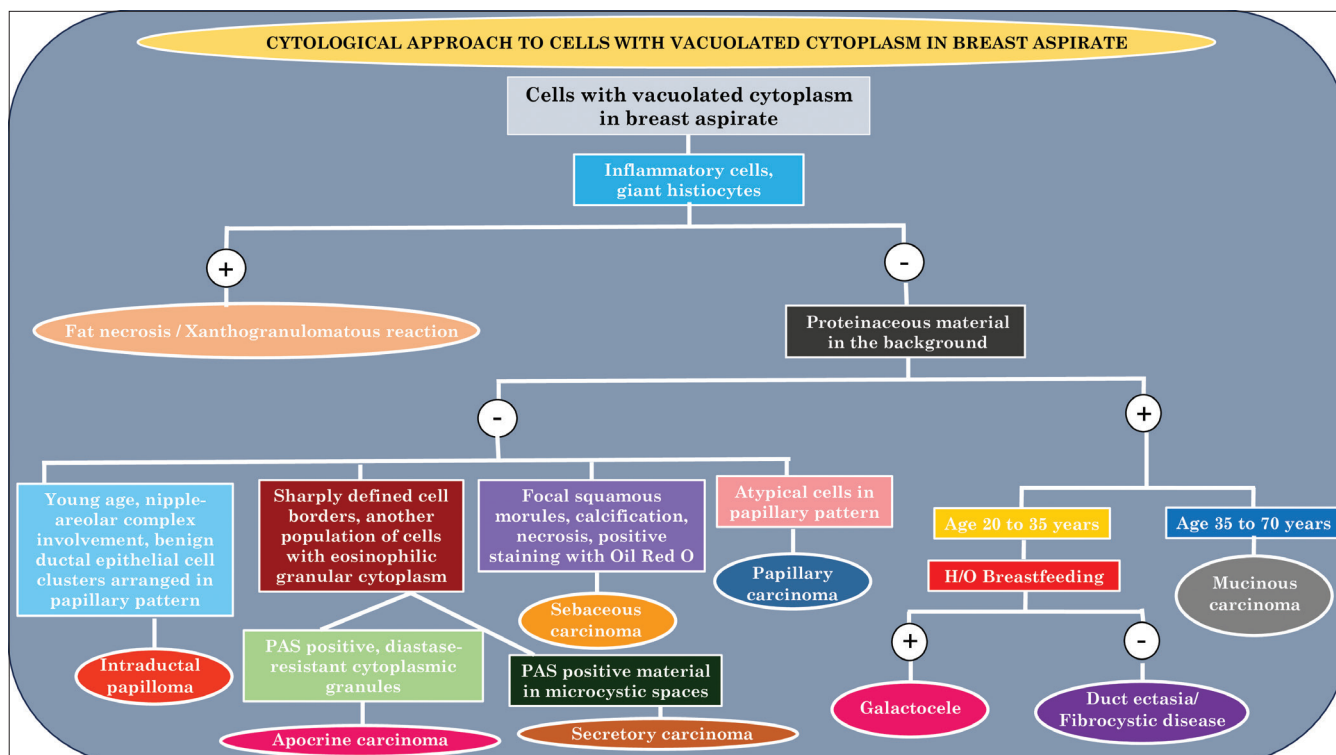


Figure 4: Algorithm for the cytological approach to cells with vacuolated cytoplasm in breast aspirate. (PAS: periodic acid-schiff, H/O: History of.) Algorithm plotted using Microsoft PowerPoint [Microsoft Office Standard 2016, Version 16.0; Manufacturer: Microsoft Corporation, Origin: Silicon Valley, CA, USA]

Table 1: Differentiation of breast carcinoma with cells having vacuolated cytoplasm by immunohistochemical evaluation of cell block sections.

Breast carcinoma subtype	Cellblock IHC (Immunohistochemistry) profile
Apocrine Ca	ER-, PR-, HER2±, AR+, GCDFP+, GATA-3+, Mammaglobin+, CK7+, CK8+, CK18+, CK19+, CK20+, EMA+, E-cadherin+, Bcl-2-
Sebaceous Ca	ER±, PR±, HER2+, AR+
Secretory Ca	ER-, PR-, HER2-, EMA+, α-Lactalbumin+, S100+, E-cadherin+, CK8+, CK18+, CD117+, α-SMA+, Mammaglobin+, GCDFP+, SOX10+, Pan-TRK
Papillary Ca	ER+, PR+, HER2-, CK8+, CK18+ CK5/6-, CK14-
Mucinous Ca	ER+, PR+, WT1+, AR±, HER2-

IHC: Immunohistochemistry, ER: Estrogen receptor, PR: Progesterone receptor, GCDFP 15: Gross cystic disease fluid protein 15, GATA-3: GATA-binding protein 3, AR: Androgen receptor, HER2: Human epidermal growth factor receptor 2, CK: Cytokeratin, EMA: Expression of MUC1

BRIEF REVIEW OF THE TOPIC

Invasive carcinoma of breast with apocrine differentiation is a special subtype of breast carcinoma.^[16] The age of presentation ranges from 48 to 60 years.^[11] It is uncommon and the incidence ranges from 0.3% to 4% of female invasive breast carcinomas. It is seen more commonly in middle-aged women. Its incidence is extremely rare in male breasts. It is an aggressive malignancy. It can be misdiagnosed as invasive duct carcinoma. Lymph node metastasis has been reported in apocrine carcinomas. Malignant adnexal tumors of the skin may arise from apocrine, eccrine, sebaceous, ceruminous, and sweat glands. Normal breast ductal cells undergo metaplasia and transform into apocrine cells. The pattern of growth of apocrine carcinoma is like that of invasive duct carcinoma.^[1-6,8-12]

Apocrine carcinoma was first described by Krompecher *et al.* in 1916. However, the histologic criteria to diagnose the apocrine carcinomas were defined by Japaze *et al.*^[3,6]

The 5th edition of the World Health Organization (WHO) Classification of Breast Tumors recognized “Carcinoma with apocrine differentiation” as a distinct entity. Apocrine differentiation occurs in invasive carcinomas NST, lobular,

tubular, medullary, and micropapillary carcinomas, DCIS, and lobular carcinoma *in situ*.^[1,7]

Apocrine carcinoma arises from the milk duct of the breast. Grossly, it presents as a solidified whitish mass. It generally presents with skin ulceration. Nipple discharge may or may not be present. It has been reported in accessory breast also. The growth pattern is like that of invasive duct carcinoma. The cells of apocrine carcinoma have abundant eosinophilic granular cytoplasm, well-defined cytoplasmic borders, apical snouting at places, large round vesicular nuclei, and multiple nucleoli.

Differential diagnoses of carcinoma with apocrine differentiation include malignancies such as secretory carcinoma, oncocytic carcinoma, lipid-rich carcinoma, invasive duct carcinoma, and benign lesions such as granular cell tumor, apocrine metaplasia, and histiocytic proliferation [Figure 4].^[8,17-27] Immunohistochemistry can help in cases where morphological interpretation alone cannot aid in differentiating between these cases [Table 1].^[1-8,10,17-28]

Focal apocrine changes can be seen in several breast lesions ranging from benign cysts to invasive carcinomas. Benign breast lesions with apocrine morphology include fibrocystic disease, apocrine cysts, the apocrine adenosis, and apocrine adenoma. Malignant lesions with apocrine morphology include apocrine DCIS and apocrine carcinoma. Hence, diagnosis of apocrine carcinoma can be challenging. Overlapping of cells, nuclear pleomorphism, and high N: C ratio are not usually seen in benign lesions with apocrine differentiation.^[5,8]

Cytogenetic analysis of apocrine carcinoma cells reveals gains of 1p, 1q, 2q, 7 and 17, losses of 1p, 12q, 16q, 17q, and 22q.^[5]

Electron microscopy of the apocrine carcinoma cells shows abundant cytoplasm with well-defined outlines, membrane-bound electron-dense granules in the cytoplasm, abundant Golgi apparatus, mitochondria with incomplete cristae and perinuclear condensation, and empty vesicles. In oncocytic carcinoma, numerous mitochondria are seen occupying >60% of the cytoplasm and they are seen to be dispersed, in contrast to apocrine carcinoma.^[4,8]

In the gene expression studies, these tumors express luminal cytokeratins (AMACR) and lack basal features. Hence, these tumors are called “Luminal Androgen Receptor” (LAR) tumors. A small proportion of cases may show a basal phenotype. AMACR is positive in 97% of invasive carcinomas with apocrine differentiation, the 96% of apocrine DCIS, but only in 22% of carcinomas without apocrine differentiation.^[10]

Next-generation sequencing frequently shows loss of PIK3CA/PTEN/AKT and TP53, followed by mutations of KRAS, NRAS, and BRAF.^[10,13]

Genetic studies on the AR gene showed the highest CAG repeats in DCIS with apocrine differentiation compared to fibroadenomas and invasive breast carcinomas.^[10]

Immunohistochemical and molecular features do not necessarily correlate in all cases of carcinomas with apocrine differentiation.^[10]

The expression of PD-L1 is low in apocrine carcinoma. They are found to be microsatellite stable.^[10] Expression of 5 α -reductase is found in 60% of apocrine carcinomas, and it correlates with poor prognosis in terms of invasion of lymphatics, blood vessels, and higher histologic grade. Gamma-glutamyl transferase 1 and tumor-associated glycoprotein-72 are specific markers of apocrine differentiation.^[5]

The unavailability of molecular and genetic studies due to financial constraints in the setting of developing countries may pose the challenge in diagnosing apocrine carcinoma.^[3]

SUMMARY

Apocrine carcinoma is an aggressive malignancy that tends to ulcerate the skin, and metastasize to lymph nodes. It is of two types – triple-negative and HER2-positive. Even in triple-negative cases, targeted therapy with anti-androgen is available. Hence, making a correct diagnosis of the tumor is necessary. Whenever vacuolated cells are encountered in the cytology smears, especially in an elderly female/male, it is prudent to sample the lesion thoroughly so that making an inappropriate diagnosis can be avoided.

AVAILABILITY OF DATA AND MATERIALS

The datasets used and/or analyzed during the current study are available from the corresponding author upon reasonable request.

ABBREVIATIONS (In alphabetic order)

AMACR – Alpha-methyl acyl-CoA racemase
 GATA3 – GATA binding protein 3
 GCDFP 15 – Gross cystic disease fluid protein 15
 AR – Androgen receptor
 DCIS – Ductal carcinoma *in situ*
 LCIS – Lobular carcinoma *in situ*
 ER – Estrogen receptor
 FNAC – Fine-needle aspiration cytology
 H & E – Hematoxylin & Eosin
 IHC – Immunohistochemistry
 LAR – Luminal androgen receptor
 MGG – May Grunwald-Giemsa
 MRM – Modified radical mastectomy
 PR – Progesterone receptor.

AUTHOR CONTRIBUTIONS

FM and SS: Designed the research study and performed the research; VR: Provided help and advice on the research. All

authors contributed to editorial changes in the manuscript. All authors read and approved the final manuscript. All authors have participated sufficiently in the work and agreed to be accountable for all aspects of the work.

ETHICS APPROVAL AND CONSENT TO PARTICIPATE

The study was started only after getting informed consent from the patient and approval from the Institute Human Ethical committee no: CARE IHEC-II/0030/21. The patients' details were maintained confidentially and had not been disclosed. The details of the study were explained to the patient in the language he could understand. The patient had not been affected by any injury/complications due to the study, as it has used only the data available.

ACKNOWLEDGEMENT

Authors would like to thank Chettinad Hospital and Research Institute (Chettinad Academy of Research and Education) for providing the necessary equipment, data, and support for studying this case.

FUNDING

Not applicable.

CONFLICT OF INTEREST

The authors declare no conflict of interest.

EDITORIAL/PEER REVIEW STATEMENT

To ensure the integrity and highest quality of CytoJournal publications, the review process of this manuscript was conducted under a **double-blind model** (authors are blinded for reviewers and vice versa) through an the automatic online system.

REFERENCES

- Jagtap SV, Jagtap SS, Phalke A, Vartak S, Billawaria S. Apocrine carcinoma of breast - uncommon variant of breast malignancy. *Clin Pathol Res J* 2021;5:1-4.
- Goel D, Maurya MK, Ramakant P. Apocrine carcinoma of breast: A rare case report. *Indian J Pathol Microbiol* 2022;65:221-3.
- Ismail S, Kherbek H, Skef J, Zahlouk N, Abdulal R, Alshehabi Z. Triple-negative apocrine carcinoma as a rare cause of a breast lump in a Syrian female: A case report and review of the literature. *BMC Womens Health* 2021;21:396.
- Muthusamy RK, Mehta SS. Giant apocrine carcinoma of the breast: A case report with review. *Asian J Oncol* 2018;4:21-4.
- Vranic S, Schmitt F, Sapino A, Costa JL, Reddy S, Castro M, *et al.* Apocrine carcinoma of the breast: A comprehensive review. *Histol Histopathol* 2013;28:1393-409.
- Wader JV, Jain A, Bhosale SJ, Chougale PG, Kumbhar SS. Apocrine carcinoma of breast: A case report with review of the literature. *Case Rep Pathol* 2013;2013:e170918.
- Allison KH, Brogi E, Ellis IO, Fox SB, Lakhani SR, Lax SF *et al.* Epithelial tumours of the breast. In: Dilani Lokuhetty, Valerie A. White, Reiko Watanabe, Ian A. Cree. WHO classification of tumours: Breast tumours. 5th ed., Vol. 2. France: IARC/WHO Committee; 2019. p. 9-161.
- Khandeparkar SG, Deshmukh SD, Bhayekar PD. A rare case of apocrine carcinoma of the breast: Cytopathological and immunohistopathological study. *J Cytol* 2014;31:96-8.
- Adiputra PA, Sudarsa IW, Irawan H, Saputra H. Malignant adnexal tumor of the skin on breast: A case report of apocrine carcinoma. *Int J Surg Case Rep* 2023;108:108383.
- Vranic S, Gatalica Z. An update on the molecular and clinical characteristics of apocrine carcinoma of the breast. *Clin Breast Cancer* 2022;22:e576-85.
- Touimi SH, N'chiepo D, Mbarki I, Elkacemi H, Elmajjaoui S, Kebdani T, *et al.* Apocrine carcinoma of breast in a male patient: Case report. *Tumori J* 2020;106:12-3.
- Fujiwara-Tani R, Hashizume J, Hanaoka K, Kuniyasu H. Axillary carcinoma with apocrine differentiation: A case report. *Clin Diagn Pathol* 2018;2:1-3.
- Vranic S, Feldman R, Gatalica Z. Apocrine carcinoma of the breast: A brief update on the molecular features and targetable biomarkers. *Bosn J Basic Med Sci* 2017;17:9-11.
- Tsuchiya A, Rokkaku Y, Nihei M, Nomizu T, Abe R. Apocrine carcinoma of the breast-a case report. *Jpn J Surg* 1988;18:714-7.
- Sinn HP, Kreipe H. A brief overview of the WHO classification of breast tumors, 4th edition, focusing on issues and updates from the 3rd edition. *Breast Care (Basel)* 2013;8:149-54.
- Tan PH, Ellis I, Allison K, Brogi E, Fox SB, Lakhani S, *et al.* The 2019 World Health Organization classification of tumours of the breast. *Histopathology* 2020;77:181-5.
- Singh TH, Rathod GB. Diagnosis of fat necrosis on FNAC-A case report. *Int Arch Integr Med* 2015;2:236-9.
- Jyoti K, Preeti B, Sandip S, Archana P, Manjushree G, Suresh M. Comparison of fine needle aspiration cytology of non-neoplastic lesions of breast with histopathology. *Sch J Appl Med Sci* 2013;1:804-13.
- Nikumbh DB, Ningurkar NU, Gondane SR, Dravid NV. Cytological diagnosis of ductal papilloma: An unusual entity in male breast. *IP Arch Cytol Histopathol Res* 2016;1:39-41.
- Aggarwal D, Sooin N, Kalita D, Pant L, Kudesia M, Singh S. Cytodiagnosis of papillary carcinoma of the breast: Report of a case with histological correlation. *J Cytol* 2014;31:119-21.
- Singla T, Singla G, Singla S, Singh M. FNAC diagnosis of crystallizing Galactocoele-an unusual presentation. *Journal of Cytology* 2020;37:149-50.
- Javadzadeh B, Finley J, Williams HJ. Fine needle aspiration cytology of mammary duct ectasia: Report of a case with novel cytologic and immunocytochemical findings. *Acta Cytol* 2001;45:1027-31.
- Mendoza P, Lacambra M, Tan PH, Tse GM. Fine needle aspiration cytology of the breast: The nonmalignant categories. *Patholog Res Int* 2011;2011:547580.
- Chikkannaiah P, Thangngeo D, Guruprasad C, Venkataramanappa S. Clinicopathological study of mucinous

carcinoma of breast with emphasis on cytological features: A study at tertiary care teaching hospital of South India. *J Lab Physicians* 2020;12:68-75.

25. Miesbauerová M, Tommola S, Šteiner P, Baněčková M, Skálová A, Kholová I. Cytopathological features of secretory carcinoma of salivary glands and ancillary techniques in its diagnostics: Impact of new Milan system for reporting salivary gland cytopathology. *APMIS* 2019;127:491-502.
26. Jung MJ, Kim SY, Nam SY, Roh JL, Choi SH, Lee JH, *et al.* Aspiration cytology of mammary analogue secretory carcinoma of the salivary gland. *Diagn Cytopathol* 2015;43:287-93.
27. Jo VY, Krane JF. Ancillary testing in salivary gland cytology: A practical guide. *Cancer Cytopathol* 2018;126 Suppl 8:627-42.
28. Cimino-Mathews A. Novel uses of immunohistochemistry in breast pathology: Interpretation and pitfalls. *Mod Pathol* 2021;34:62-77.

How to cite this article: Muniraj F, Srinivasan S, Raghavan V. Challenge in the cytological interpretation of a not-so-typical breast carcinoma. *CytoJournal*. 2024;21:25. doi: 10.25259/Cytojournal_43_2023

HTML of this article is available FREE at:
https://dx.doi.org/10.25259/Cytojournal_43_2023

The FIRST **Open Access** cytopathology journal

Publish in *CytoJournal* and **RETAIN** your *copyright* for your intellectual property

Become Cytopathology Foundation (CF) Member at nominal annual membership cost

For details visit <https://cytojournal.com/cf-member>

PubMed indexed

FREE world wide **open access**

Online processing with rapid turnaround time.

Real time dissemination of time-sensitive technology.

Publishes as many **colored high-resolution images**

Read it, cite it, bookmark it, use RSS feed, & many----



CYTOJOURNAL

www.cytojournal.com

Peer -reviewed academic cytopathology journal





NextGen CelBloking™ Kits

**Frustrated with your cell blocks?
We have a better solution!**

Nano

Nano NextGen CelBloking™

Cell block kit to process single scattered cell specimens and tissue fragments of **any** cellularity.



PATENT PENDING



Pack #1



Pack #2

Micro

Micro NextGen CelBloking™

For cellular specimens (more than 1 ml concentrated specimen with Tissuecrit more than 50%)



PATENT PENDING



Pack #2