

Case Report

Open Access

Cytologic findings of peripheral T-cell lymphoma (PTCL) with high epitheloid cell content (Lennert's lymphoma) in imprint smear. A case report

Yahya Daneshbod*

Address: Department of Hematopathology, University of Kiel, and Lymph Node Registry, Kiel, Germany

Email: Yahya Daneshbod* - daneshbk@yahoo.com

* Corresponding author

Published: 06 February 2006

Received: 14 November 2005

CytoJournal 2006, 3:3 doi:10.1186/1742-6413-3-3

Accepted: 06 February 2006

This article is available from: <http://www.cytojournal.com/content/3/1/3>

© 2006 Daneshbod; licensee BioMed Central Ltd.

This is an Open Access article distributed under the terms of the Creative Commons Attribution License (<http://creativecommons.org/licenses/by/2.0>), which permits unrestricted use, distribution, and reproduction in any medium, provided the original work is properly cited.

Abstract

Background: Lymphoepitheloid lymphoma is a T-cell lymphoma with peculiar histologic picture with massive proliferation of epitheloid cell clusters intermingled with many, mostly small-sized lymphoid cells. The cytomorphologic features in imprint of a case of lymphoepitheloid T-cell lymphoma is described together with diagnostic pitfalls.

Case report: A 74 years old man presented with weight loss, anemia and fever. Physical examination showed bilateral cervical lymphadenopathy with hepatosplenomegaly. With the clinical impression of hypersplenic syndrome vs lymphoma, excisional biopsy of a lymph node was performed and both imprints and histologic sections made. Cytologic findings showed uniform isolated small lymphocytes with closely intermingled scattered and aggregates of epitheloid cells. Histologic sections were diagnosed as lymphoepitheloid lymphoma (Lennert's lymphoma).

Conclusion: Cytologic findings of this variant of lymphoma is distinctive enough for a correct initial suggestive diagnosis. However the presence of high content of epitheloid cell clusters can cause cytologic misinterpretation with other benign and malignant conditions.

Background

Fine needle aspiration (FNA) and touch imprint cytology is widely used in the initial investigation of lymphadenopathy, and offers immediate preliminary diagnosis. Lymphoepitheloid lymphoma (Lennert lymphoma) is a particular variant of peripheral T-cell lymphoma with almost unique histologic morphology characterized by two predominant cell populations: epitheloid cells and T lymphocytes, mainly of T helper/inducer phenotype [2].

However other benign or malignant conditions can partly mimic this picture [5]. Cytomorphology of this variant of lymphoma has been very rarely described [10]. So we like

to describe the cytologic findings of this variant of peripheral T-cell lymphoma together with diagnostic pitfalls.

Case report

In 1982, a 74 year old diabetic man presented with weight loss, anorexia and fever. Physical examination showed hepatosplenomegaly. Laboratory findings were a Hb: 9.4 g/dl, WBC: 1800/ml, PLT: 180,000, low albumin with normal serum iron. With clinical impression of hypersplenism vs lymphoma, lymph node excisional biopsy and imprint smear were made.

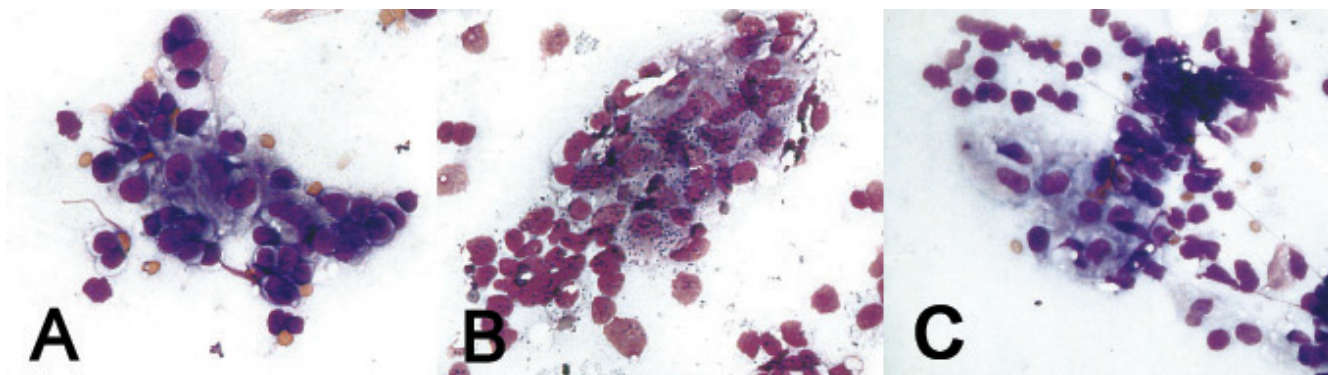


Figure 1
 ABC: Small and large groups and clusters of epithelioid cells intermingled with the lymphocytes (Papanicolaou $\times 400$, $\times 400$, $\times 400$).

Cytologic smears were air-dried and stained by Papanicolaou. Papanicolaou stain is equivalent to Wright-Giemsa/Diff-Quick stain. The smear was cellular and contained mainly (monomorphic) population of lymphocytes with round to oval nucleus and fine, evenly dispersed chromatin. Cytoplasm were light blue to clear. Rare cells with nuclear irregularity were noted. There were also small and large groups and clusters of epithelioid histiocytes intermingled with the lymphocytes (Fig. 1ABC). Epithelioid histiocytes shows oval to bean shaped nucleus with finely dispersed chromatin, twice the size of the lymphocytes with ample grayish granular cytoplasm (Fig. 2). However

no distinct granuloma were noted. Multinucleated giant cell or lymphogranular bodies were not noted.

Histologic sections of the lymph node showed a completely effaced architecture with exuberant proliferation of histiocytes in cluster and sheets, intermingled with small round to oval neoplastic lymphocytes (Fig 3). The final histologic report was "Lennert's lymphoma, with possibility of immunocytoma and epithelioid rich Hodgkins disease, however cytomorphology is against Hodgkins disease" (histologic diagnosis made by K. Lennert in Kiel, Germany, 1982). Immunohistochemical study (markers

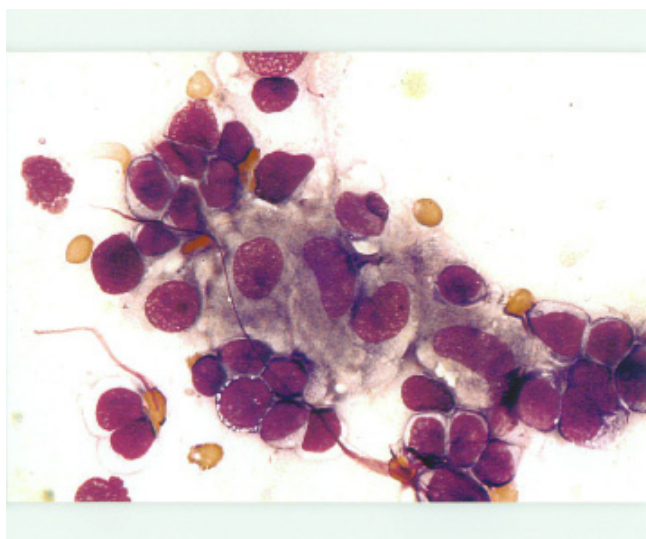


Figure 2
 Epithelioid histiocytes showed oval to bean shaped nucleus with finely dispersed chromatin, twice the size of the lymphocytes with ample grayish granular cytoplasm (Papanicolaou $\times 1000$).

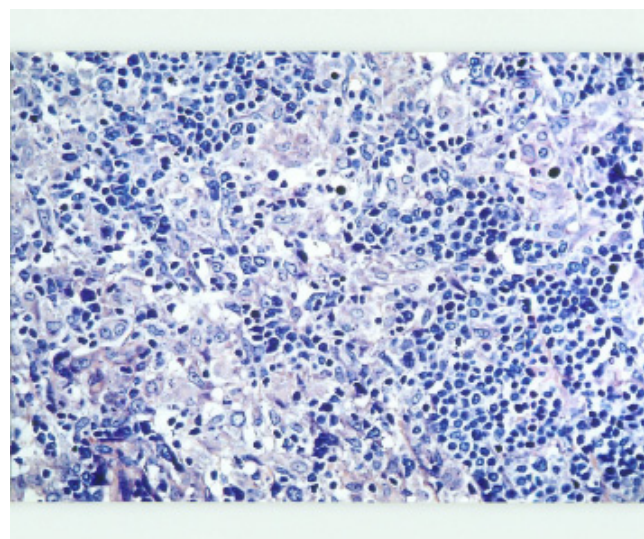


Figure 3
 Sections of the lymph node showed a completely effaced architecture with exuberant proliferation of epithelioid cells in cluster and sheets, intermingled with small round to oval neoplastic lymphocytes (Giemsa, $\times 400$).

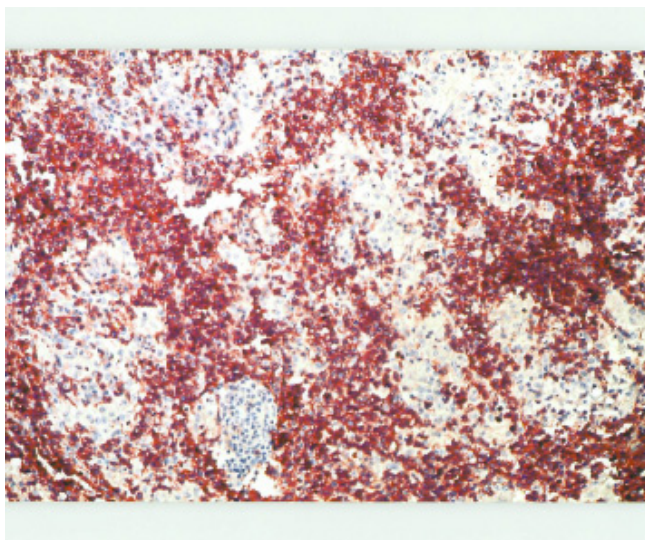


Figure 4
Uniform positivity for CD5 in lymphoid cells (×400).

done not known) was in favor of an epitheloid rich T cell lymphoma. Reanalysis of stored paraffin blocks from 1982 showed an immunophenotype typical of peripheral T cell lymphoma with strong uniform positivity for CD5 and CD4 (Fig. 5) and negative for CD8, CD20. Gene rearrangement for T cell receptor was performed which confirmed a monoclonal process. Bone marrow biopsy was done and reported as extensive infiltration by malignant lymphoma cells with remarkable presence of macrophages and epitheloid cells with fibrosis (histologic diagnosis made by Lutz Dietrich Leder in Kiel, Germany, 1982) which he could not classify but also thought of hairy cell leukemia.

Discussion

Lymphoepitheloid T- cell was first described by Lennert (Habilitation thesis, 1952) and published (1968)[1], and later widely known as Lennert's lymphoma. Older individuals are generally affected. Splenomegaly and lymphadenopathy may be prominent features, with involvement of Waldayer's ring also observed in European cases [7]. However in Revised European-American classification of lymphoid neoplasms (R.E.A.L) and World Health Organization (W.H.O), it is included in the peripheral T-cell lymphoma not otherwise specified (NOS)[4]. Histologically lymphoepitheloid cell variant (Lennert lymphoma) shows diffuse or (more rarely) interfollicular infiltrates consisting predominantly of small cells with only slight nuclear irregularities. Numerous clusters of epitheloid histocytes are present [4]. Clear cells or high endothelial venules are less frequent than in peripheral T- cell lymphomas of angioimmunoblastic or T-zone type. Few Reed-Sternberg-like cells, eosinophils

and plasma cells can be seen [4]. However in our case they were absent on histology and cytology. Another term which should not be confused with this lymphoma is the Lennert's pattern. This is a histologic picture of diffuse scattered epitheloid population throughout the lymph node [5]. Differential diagnosis of Lennert's pattern includes both benign and malignant conditions such as: granulomatous lymphadenitis, tuberculosis, sarcoidosis, abnormal immune response, peripheral T-cell lymphoma, T-cell rich B-cell lymphoma, mixed cellularity Hodgkin lymphoma, nodular lymphocytic and histiocytic Hodgkin's lymphoma and lymphoepithelioma-like carcinoma [5,8]. Cytologically all the mentioned diseases can partly simulate lymphoepitheloid lymphoma. In this case aggregates of epitheloid cell closely mimicked granuloma in which conditions like TB should be considered. However this case showed no multinucleated giant cell or polymorphic background. The monomorphic background can easily rule out sarcoidosis or other reactive or immunologic process. The cytology of natural Killer/T-cell lymphomas show more pleomorphism with irregular chromatin distribution and usually no epitheloid cells [1]. FNA cytology of lymph node involvement by high grade mycosis fungoides with monotonous population of large and small cells can be misinterpreted with our case. However mycosis shows more anisocytosis with cerebriform convoluted nuclei against a background of atypical lymphocytes, and plasma cells [3,6]. Those cases of T- cell rich B- cell lymphoma (TCRBL) which can show also many epitheloid cells and predominance of mature small lymphocytes with few or absent atypical large, immature lymphoid cells should be considered in differential diagnosis [9]. However atypical large lymphoid cells are much more scarce in Lennert's lymphoma and immunocytochemistry can clearly differentiate these cases, which the large cells show B-cell marker and the small lymphocytes does not have aberrant antigen expression. To our knowledge, literature on cytologic findings of lymphoepitheloid lymphoma is sparse[10]. Although final diagnosis of this variant of T cell lymphoma is confirmed by immunohistochemical studies, cytologically the presence of monomorphic lymphoid background with mild to absent atypia with closely intermingled clusters of epitheloid histiocytes help for a correct preliminary working diagnosis.

Acknowledgements

I would like to greatly thank Professor K. Lennert for providing his personal collection of cases of lymphoepitheloid T cell lymphomas referred to him from all parts of world including this case and reading and correcting this paper. I am also greatly indebted to Professor R. Parwaresch for his scientific guidance. Finally I like to acknowledge Professor M. Nadji for his review and comments.

Co-editors of CytoJournal Vinod B. Shidham, MD, FRCPath, FIAC and Barbara F. Atkinson, MD thank: the academic editor Darshana N. Jhala, MD Department of Pathology, University of Alabama at Birmingham, Birmingham-

ham, Alabama, USA djhala@path.uab.edu for organizing and completing the peer-review process for this manuscript.

References

1. Cho EY, Gong G, Khang SK, Kang YK, Huh J: **Fine needle aspiration cytology of CD56-positive natural killer/T-cell lymphoma of soft tissue.** *Cancer* 2002, **96**:344-50.
2. Feller AC, Griesser GH, Mak TW, Lennert K: **Lymphoepithelioid lymphoma (Lennert's lymphoma) is a monoclonal proliferation of helper/inducer T cells.** *Blood* 1986, **68**:663-7.
3. Galindo LM, Garcia FU, Hanau CA, Lessin SR, Jhala N, Bigler RD, Vonderheid EC: **Fine-needle aspiration biopsy in the evaluation of lymphadenopathy associated with cutaneous T-cell lymphoma (mycosis fungoides/Sezary syndrome).** *Am J Clin Pathol* 2000, **113**:865-71.
4. Jaffe ES, Harris NL, Stein H, Vardiman JW, eds: **World Health Organization Classification of Tumors. Pathology and genetics tumors of haematopoietic and lymphoid tissues.** Lyon: IARC Press; 2001.
5. Knowles DM: *Neoplastic hematopathology* Second edition. Lippincott Williams and Wilkins. Philadelphia; 2001:530-531.
6. Laforga JB, Chorda DMC-05-, Sevilla F: **Intramammary lymph node involvement by mycosis fungoides diagnosed by fine needle aspiration biopsy.** *Diagn Cytopathol* 1998, **19**:124-6.
7. Lennert K, Mestdagh J: **Hodgkin's disease with constantly high content of epithelioid cells.** *Virchows Arch A Pathol Pathol Anat* 1968, **344**:1-20.
8. Reich O, Pickel H, Purstner P: **Exfoliative cytology of a lymphoepithelioma-like carcinoma in a cervical smear. A case report.** *Acta Cytol* 1999, **43**:285-8.
9. Tani E, Johansson B, Skoog L: **T-cell-rich B-cell lymphoma: fine-needle aspiration cytology and immunocytochemistry.** *Diagn Cytopathol* 1998, **18**:1-4.
10. Vaillo Vinagre A, Gutierrez Martin A, Perez Barrios A, Alberti Masgrau N, Ruiz Liso JM: **Lymphoepithelioid cell lymphoma (Lennert's lymphoma). Report of a case with fine needle aspiration cytology.** *Acta Cytol* 2004, **48**:234-8.

Publish with **BioMed Central** and every scientist can read your work free of charge

"BioMed Central will be the most significant development for disseminating the results of biomedical research in our lifetime."

Sir Paul Nurse, Cancer Research UK

Your research papers will be:

- available free of charge to the entire biomedical community
- peer reviewed and published immediately upon acceptance
- cited in PubMed and archived on PubMed Central
- yours — you keep the copyright

Submit your manuscript here:
http://www.biomedcentral.com/info/publishing_adv.asp





NextGen CelBloking™ Kits

**Frustrated with your cell blocks?
We have a better solution!**

Nano

Nano NextGen CelBloking™

Cell block kit to process single scattered cell specimens and tissue fragments of **any** cellularity.



PATENT PENDING



Pack #1



Pack #2


Micro

Micro NextGen CelBloking™

For cellular specimens (more than 1 ml concentrated specimen with Tissuecrit more than 50%)



PATENT PENDING



Pack #2