

Quiz Case

A rare and challenging case of uterine mass successfully reported in a cervical smear

Waleed Al Amri, PhD¹, Ishaq Al Salmi, MD², Safia K. Al Nabhani, MD, FRCPath¹, Bushra S. Al Hatrooshi, MD, FIAC, FRCPath¹

¹Department of Laboratory Medicine and Pathology, The Royal Hospital, Muscat, Oman.

²Department of Radiology, The Royal Hospital, Muscat, Oman.

***Corresponding author:**

Dr. Waleed Al Amri,
Department of Laboratory
Medicine and Pathology, The
Royal Hospital, Muscat, Oman.

waleedsaid.alamri@moh.gov.om

Received: 16 September 2022

Accepted: 28 October 2022

Published: 13 September 2023

DOI

10.25259/Cytojournal_37_2022

Quick Response Code:



A 65-year-old postmenopausal woman, gravida 7 and para 5 from a rural hospital, presented with the lower abdominal pain associated with dysuria. A contrast-enhanced computed tomography was done, which showed a mass occupying the uterus and part of the mass is protruding into the upper vagina. A Papanicolaou (Pap) smear test was performed. The images are shown in [Figure 1].

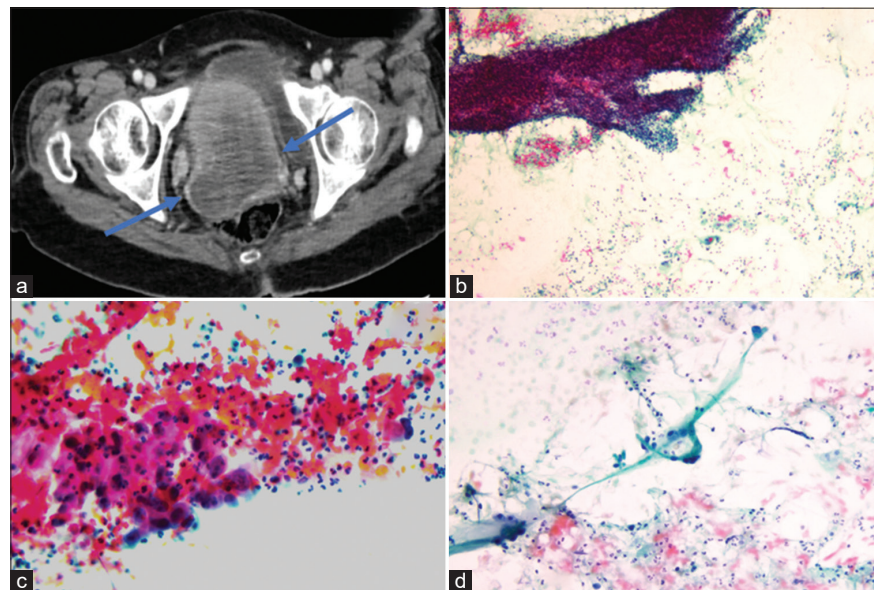


Figure 1: (a) Contrast-enhanced computed tomography scan axial image at the region of the pelvis showed a large heterogeneous enhancing mass occupying the uterus and protruding into the upper vagina (arrows). (b) Cytological cervical smears examination showed tissue fragments of round to oval hyperchromatic nuclei with scant cytoplasm in necrotic debris background (Pap, ×10). (c) Cells with abundant granular to glassy cytoplasm and nuclei with coarse irregularly distributed chromatin and macroprominent nucleoli (Pap, ×40). (d) Large bizarre cells with strap-like, rhabdoid morphology (Pap, ×20).

QUESTION

Q1. What is your diagnosis for the above findings?

- Squamous cell carcinoma.
- Endocervical adenocarcinoma
- Carcinosarcoma
- Neuroendocrine carcinoma.

The answer is (c).

Uterine carcinosarcoma, also known as malignant mixed Mullerian tumor (MMMT), is a rare and aggressive form of corpus uteri tumor. The tumor is composed of two cellular components: Epithelial and mesenchymal. The cervical smear findings showed both cellular components which raised the suspicion of carcinosarcoma. Endocervical adenocarcinoma can be a differential; however, the presence of large rhabdoid cells and tissue fragments of round to oval hyperchromatic nuclei with scant cytoplasm cells excluded adenocarcinoma. Squamous cell carcinoma (SCC) was excluded since the spindle cells that are present in this case look different from pleomorphic cells such as “tadpole” and “fiber” cells that are seen particularly in keratinizing type of SCC. Also, the lack of high-grade squamous intraepithelial lesion which did not favor the diagnosis of SCC. Hence altogether, the final report concluded that carcinosarcoma is the most likely correct diagnosis.

Further workup of the case

The patient underwent total hysterectomy with bilateral salpingo-oophorectomy and right and left lymph node. Gross examination of the resected specimen demonstrated a completely occupied endometrial cavity by a large polypoid soft tan mass. Furthermore, the mass extended through the cervix and protruded from the external cervical OS [Figure 2a]. Histopathological examination of the tumor mass revealed an admixture of spindle cells and epithelioid cells. The spindle cell component showed hyperchromatic pleomorphic nuclei and indistinct cell borders. It was admixed with varying proportions of large polygonal cells and strap-like cells. The epithelioid component was comprised

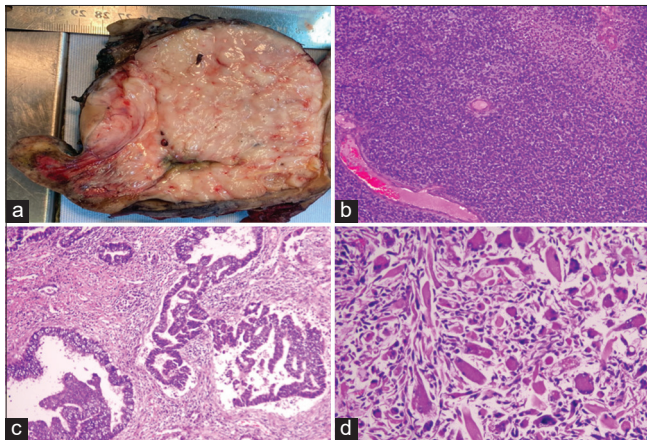


Figure 2: (a) Gross examination of the total hysterectomy specimen showed a completely occupied endometrial cavity by a large polypoid soft tan mass attached to fundus, anterior and posterior wall and also extends through the cervix. (b) Histological sections of resected uterus showed sarcomatous area (H&E, $\times 4$), (c) serous carcinoma (H&E, $\times 10$), and (d) rhabdomyosarcomatous morphology (H&E, $\times 10$).

of sheets of round cells with moderately hyperchromatic pleomorphic nuclei showing brisk mitosis and scattered spiral-like arterioles. Large areas of necrosis and hemorrhage were also seen. Additional sections of posterior uterine wall showed atrophic endometrium with irregular variably sized glands lined by columnar epithelial cells with marked nuclear atypia and prominent nucleoli [Figure 2b-d].

ADDITIONAL QUIZ QUESTIONS

Q2. What are the following immunohistochemistry markers will be positive to confirm the diagnosis of carcinosarcoma?

- CD56, desmin, α -smooth muscle actin (SMA), MyoD-1, AE1/AE3, and tumor protein 53 (P53)
- Synaptophysin, chromogranin, and AE1/AE3
- CEA, vimentin, and ER
- P16, CK5/6, and P63

The answer is (a).

Immunohistochemical markers on sarcomatous components were positive for cluster of differentiation 56, and desmin and focal positivity for α -SMA and MyoD-1 [Figure 3a-d]. In the malignant epithelial components, AE1/AE3 and P53 showed positivity in more than 80% of the cells in keeping with serous carcinoma [Figure 3e].

Q3. All of following are heterologous component of carcinosarcoma, except for?

- Osteosarcomatous
- Liposarcomatous
- Angiosarcomatous
- Leiomyosarcoma

The answer is (d).

BRIEF REVIEW OF THE TOPIC

MMMT, also known as carcinosarcoma, is a rare and aggressive form of corpus uteri tumor. The tumor is composed of two cellular components: Epithelial and mesenchymal which commonly arise from the endometrial cavity.^[1] Despite carcinosarcoma cases currently comprising $<5\%$ of all uterine tumors,^[2] there is an evidence to suggest that there is an increase in the incidence of carcinosarcomas.^[3] Hence, it becomes increasingly important for cytologists to be aware of the cytological features for diagnosing this form of tumor. Our cytological findings showed highly atypical epithelial and spindle cells, suggestive of a biphasic tumor type. In addition, a tumor diathesis is reported to be characteristic features of carcinosarcoma in cytological cervical smears.^[4,5]

Our cytological features overlapped with previously described reports,^[4-6] indicating that carcinosarcoma should always be considered in cases where malignant epithelial and spindle cells are found on a dirty background, especially

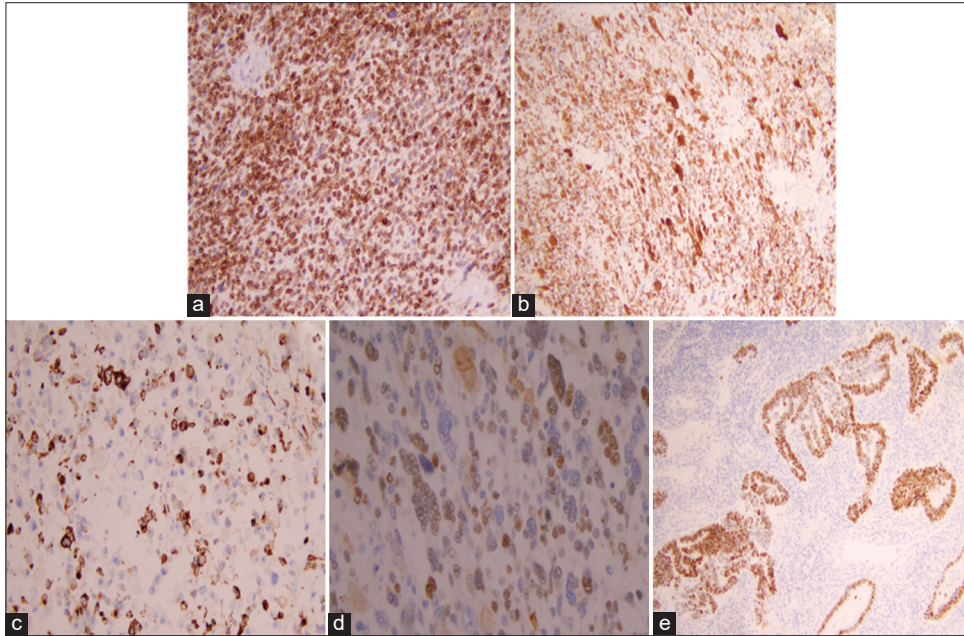


Figure 3: Immunohistochemical analysis of uterine carcinosarcoma. (a) The sarcomatous component showed positive for CD56 ($\times 20$), (b) Desmin ($\times 10$), and (c) partially positive α -Smooth Muscle Actin (α -SMA) muscle actin ($\times 20$), and (d) MyoD-1 ($\times 40$). (e) The carcinomatous component stained positive for P53 ($\times 10$).

in women presenting with postmenopausal bleeding.^[7] In contrary, other studies have indicated that sarcomatous components are rare findings in cytological smears which make diagnosis of carcinosarcoma difficult.^[6,8] A study by Hanley *et al.* showed that around 72.5% of carcinosarcoma patients had an abnormal Pap smear; however, the majority lacked cytological features consistent with a sarcomatous component.^[9] In addition, a study showed that Pap smear test has low overall sensitivity (41.8%), but higher specificity (60.8%) for detecting uterine glandular lesions, which suggest that cytological findings should be confirmed by histological and immunochemical markers.^[10]

Uterine carcinosarcoma is a malignancy of two components; epithelial (carcino-) and mesenchymal (-sarcoma), and it can be classified as homologous or heterologous types. The homologous type involves a sarcomatous component of intrauterus such as fibrosarcoma, endometrial stromal sarcoma, and leiomyosarcoma, whereas heterologous component involves cells of extrauterine connective tissues such as rhabdomyosarcoma and chondrosarcoma.^[11] In the present case, the malignant epithelial components are positive for P53 and p16 in keeping with serous carcinoma. While the sarcomatous component with rhabdoid differentiation was positive for MyoD-1 and desmin and negative for h-caldesmon, demonstrating a heterologous uterine carcinosarcoma, consistent with previously reported case.^[12]

This case was challenging since the Pap smear request was received from a peripheral hospital with limited clinical and

radiological details. Furthermore, this tumor commonly occurs in postmenopausal women, with one of the most frequent clinical manifestations being postmenopausal bleeding. However, in this case, the patient presented with the lower abdominal pain and dysuria. Nevertheless, the presence of all the classic cytological features of carcinosarcoma enabled a successful diagnosis of this rare tumor in a Pap smear.

SUMMARY

Carcinosarcoma of the uterine wall may extend to cervix and present in cytological cervical (Pap) smears. Awareness of the possibility facilitates an optimal diagnosis and appropriate management.

Acknowledgment

The authors would like to express their thanks to Stacey Jones, MPharm, MBChB, MRCS, MD, for revising the manuscript.

COMPETING INTEREST STATEMENT BY ALL AUTHORS

The authors of this manuscript declare no conflicts of interest.

AUTHORSHIP STATEMENT BY ALL AUTHORS

WSAA planned, designed, collected data, and wrote the manuscript. BAH provided images, supervised, and edited

the manuscript. SAS and SKAN provided images and revised the manuscript.

ETHICS STATEMENT BY ALL AUTHORS

Ethical approval was obtained from the institutional scientific research committee to publish this case report (SRC#CR14/2022).

LIST OF ABBREVIATIONS (In alphabetic order)

CD56 – Cluster of differentiation 56

CT – Computed tomography

MMMT – Malignant mixed Mullerian tumor

Pap – Papanicolaou

P53 or TP53 – Tumor protein 53

SMA – Smooth muscle actin

SCC – Squamous cell carcinoma

EDITORIAL/PEER-REVIEW STATEMENT

To ensure the integrity and highest quality of CytoJournal publications, the review process of this manuscript was conducted under a **double-blind model** (authors are blinded for reviewers and *vice versa*) through automatic online system.

REFERENCES

1. Akahira JI, Tokunaga H, Toyoshima M, Takano T, Nagase S, Yoshinaga K, *et al.* Prognoses and prognostic factors of carcinosarcoma, endometrial stromal sarcoma and uterine leiomyosarcoma: A comparison with uterine endometrial adenocarcinoma. *Oncology* 2006;71:333-40.
2. Matsuo K, Ross MS, Machida H, Blake EA, Roman LD. Trends of uterine carcinosarcoma in the United States. *J Gynecol Oncol* 2018;29:e22.
3. Liao CI, Caesar MA, Lee D, Chan A, Darcy KM, Tian C, *et al.* Increasing incidence of uterine carcinosarcoma: A United States cancer statistics study. *Gynecol Oncol Rep* 2022;40:100936.
4. Costa MJ, Tidd C, Willis D. Cervicovaginal cytology in carcinosarcoma [malignant mixed mullerian (mesodermal) tumor] of the uterus. *Diagn Cytopathol* 1992;8:33-40.
5. Casey MB, Caudill JL, Salomão DR. Cervicovaginal

(papanicolaou) smear findings in patients with malignant mixed müllerian tumors. *Diagn Cytopathol* 2003;28:245-9.

6. Gupta N, Dudding N, Smith JH. Eight cases of malignant mixed müllerian tumor (carcinosarcoma) of the uterus: Findings in SurePath™ cervical cytology. *Diagn Cytopathol* 2014;42:165-9.
7. Bongiovanni M, Vitale VA, Grassi P, Mazzucchelli L. Malignant mixed müllerian tumor with an extensive squamous-cell carcinomatous component: A potential pitfall in liquid-based cervical cytology. *Acta Cytol* 2014;58:413-8.
8. Snyder MJ, Robboy SJ, Vollmer RT, Dodd LG. An abnormal cervicovaginal cytology smear in uterine carcinosarcoma is an adverse prognostic sign: Analysis of 25 cases. *Am J Clin Pathol* 2004;122:434-9.
9. Hanley KZ, Oprea-Ilie G, Ormenisan C, Seydafkan S, Mosunjac MB. Atypical findings on cervicovaginal smears correlate with cervical involvement by malignant mixed müllerian tumors of the uterus. *Acta Cytol* 2015;59:319-24.
10. Bansal B, Gupta P, Gupta N, Rajwanshi A, Suri V. Detecting uterine glandular lesions: Role of cervical cytology. *Cytojournal* 2016;13:3.
11. Adachi Y, Nonogaki H, Minamiguchi S, Li M, Ikehara S. Carcinosarcoma of the uterus: A case report. *Mol Clin Oncol* 2016;4:571-3.
12. Seow DY. Liquid-based papanicolaou smear: Unusual cytological features of a uterine mass. *Cytojournal* 2020;17:2.

How to cite this article: Al Amri W, Al Salmi I, Al Nabhani SK, Al Hatrooshi BS. A rare and challenging case of uterine mass successfully reported in a cervical smear. *CytoJournal* 2023;20:35.

The **FIRST Open Access** cytopathology journal

Publish in *CytoJournal* and **RETAIN** your *copyright* for your intellectual property

Become Cytopathology Foundation Member to get all the benefits
Annual membership fee is nominal US \$ 50 (US \$ 1000 for life)

In case of economic hardship it is free

For details visit <https://cytojournal.com/cf-member>

PubMed indexed

FREE world wide **open access**

Online processing with rapid turnaround time.

Real time dissemination of time-sensitive technology.

Publishes as many **colored high-resolution images**

Read it, cite it, bookmark it, use RSS feed, & many----



CYTOJOURNAL

www.cytojournal.com

Peer-reviewed academic cytopathology journal





NextGen CelBloking™ Kits

**Frustrated with your cell blocks?
We have a better solution!**

Nano

Nano NextGen CelBloking™

Cell block kit to process single scattered cell specimens and tissue fragments of **any** cellularity.



PATENT PENDING



Pack #1



Pack #2

Micro

Micro NextGen CelBloking™

For cellular specimens (more than 1 ml concentrated specimen with Tissuecrit more than 50%)



PATENT PENDING



Pack #1



Pack #2