



Quiz Case

Rapid on-site evaluation of a solitary lung nodule in a patient with remote history of hysterectomy: Cytologic findings and diagnostic challenges

Tricia Rood Lowrey¹, Venetia Rumnong Sarode¹

¹Department of Pathology, UT Southwestern Medical Center, Dallas, Texas, United States.



***Corresponding author:**

Venetia Rumnong Sarode,
Department of Pathology, UT
Southwestern Medical Center,
Dallas, Texas, United States.

venetia.sarode@utsouthwestern.edu

Received : 13 August 2022
Accepted : 31 October 2022
Published : 05 August 2023

DOI
10.25259/Cytojournal_29_2022

Quick Response Code:



A 75-year-old female patient was referred to our institution with chronic upper gastrointestinal symptoms. A computed tomography (CT) scan of the abdomen and chest revealed a well-demarcated, ovoid nodule in the right, lower lobe of the lung measuring 17 mm. She had a remote history of hysterectomy for endometrial sarcoma 26 years ago. A transbronchial fine needle aspiration biopsy and rapid on-site assessment of smears were performed. The smears were moderately cellular comprising very uniform population of small, round to oval cells with very scant cytoplasm disposed as single cells and occasional clusters associated with occasional metachromatic matrix [Figure 1a and b]. The Papanicolaou stain showed cells with moderately hyperchromatic nuclei with evenly distributed chromatin and inconspicuous nucleoli. The cell block showed groups of small cells arranged around thin-walled vessels and eosinophilic and hyaline matrix. There were no mitoses, necrosis, or hemorrhage [Figure 1c and d].

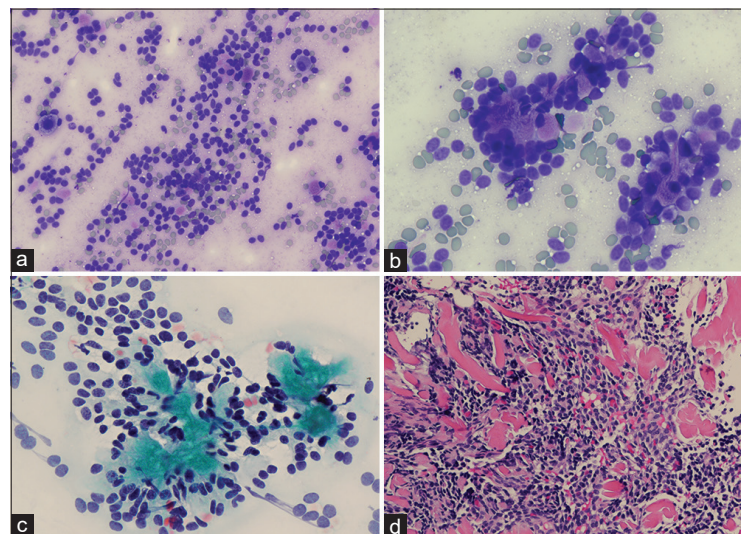


Figure 1: (a) Cytologic smear of lung nodule on rapid on-site assessment (Diff Quik, ×200). (b) Discrete and clusters of cells with pale matrix (Diff Quik, ×400). (c) Papanicolaou stain showing monotonous small round to oval cells ×400. (d) Cell block showing sheets of small cells with hyperchromatic nuclei (H and E ×200).

Q1. What is the most likely diagnosis?

- a. Lung hamartoma
- b. Non-Hodgkin lymphoma
- c. Small cell carcinoma
- d. Carcinoid tumor
- e. Metastatic low-grade endometrial stromal sarcoma (ESS)

Answer to Q1: Option e

Explanation: The cytologic features of lung hamartoma are characterized by paucicellular smears, prominent chondroid matrix, bronchial epithelial cells, sheets of small round cells, and occasionally fat cells.^[1] In our case, there were no bronchial cells, cartilage, or adipose tissue. The small round cells with hyperchromatic nuclei mimicked a non-Hodgkin lymphoma. However, the presence of cohesive cell groups and absence of lymphoglandular bodies make this diagnosis unlikely. Small cell carcinoma was ruled out by the absence of nuclear molding, chromatin smearing, necrosis, and mitoses.

Metastatic ESS lacks any characteristic features on cytology and is frequently mistaken for a benign lesion or carcinoid tumor. A history of hysterectomy 26 years ago in our patient is an important clue to the diagnosis. The cytology smears were characterized by small, round to oval cells with no visible cytoplasm and no definite pattern of the arrangement of the tumor cells. Spindle cells were not evident and necrosis, mitoses, and hemorrhage were absent.

ESS is a very rare tumor of the endometrium comprising 1.0% of all uterine malignancies.^[2] The current World Health Organization classifies these groups of neoplasms into four distinct categories: Endometrial stromal nodule, low-grade ESS, high-grade ESS, and undifferentiated uterine sarcoma. Low-grade ESS accounts for 86% of all ESS^[2] and usually affects perimenopausal women. The tumor is characterized by tongue like invasion into the myometrium. Microscopically, the tumor resembles proliferative phase endometrium with small to oval cells surrounding blood vessels and low mitotic index. Late recurrence and metastasis can occur even in early-stage disease requiring long-term follow-up.^[2] Distant metastasis to the lung is typically in the form of multiple nodules.

Q2. Which immunohistochemical panel would be best to confirm the diagnosis of low-grade ESS?

- Chromogranin, synaptophysin, CK5/6, INSM1, and ki67
- CK7, TTF1, Napsin A, p63, and p40
- CD10, ER, PR, WT1, AR, and interferon-induced transmembrane protein 1 (IFITM1)
- P16, desmin, SMA, and beta-catenin

Answer: c

Explanation: There is no single marker that is specific for low-grade-ESS; the use of a panel of immunohistochemical markers can help in making the diagnosis besides detailed clinical history. The tumor is typically positive for CD10, ER, PR, WT1, AR, and IFITM1. The neuroendocrine and smooth muscle markers were negative in our case [Figure 2].

Q3. What is the most common cytogenetic abnormality associated with low-grade ESS?

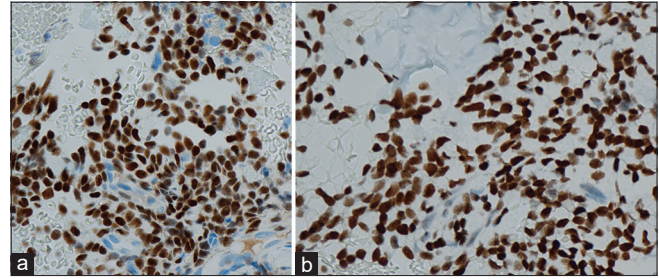


Figure 2: (a) Immunohistochemical stain for CD10 $\times 200$. (b) Immunohistochemical stain for WT1 $\times 200$.

- t(7;17) (p16;q21)
- t(6;7) (p21;p15)
- t(10;17) (q22;p13)
- t(x;17)(p21-p11;q23)

Answer: a

Explanation: Different types of chromosomal abnormalities have been described in low-grade ESS and cytogenetic analyses have been used to confirm the diagnosis. Different types of translocation have been reported with t(7;17) translocation being the most distinctive cytogenetic hallmark of low-grade ESS with fusion of two genes *JAZF1* and *SUZ12* (2, 3).

Q4 What is the most common site of metastasis of low-grade ESS besides lung?

- Bone
- Kidney
- Brain
- Abdomen

Answer: d

Explanation: The lung and abdomen are the most frequent sites of metastasis and recurrence.

Our case was discussed at the multidisciplinary conference for further management. Due to her age and oligo metastatic disease, the patient opted for close follow-up, and anti-hormonal therapy was recommended.

BRIEF REVIEW OF THE TOPIC

Endometrial stromal tumors are rare tumors that arise from the endometrial stroma. Low-grade ESS typically occurs in perimenopausal women and has a very indolent course with excellent prognosis.^[3] Distant metastasis can develop many decades after the initial diagnosis.^[3] Pulmonary metastasis from low-grade ESS usually manifests as multiple nodules.^[4-6] Very rarely, however, it can present as a solitary lesion, which can pose significant diagnostic dilemma. Due to its rarity and bland appearance, low-grade ESS has been mistaken for benign lesions or inflammatory processes.^[4,6-9] The diagnostic

dilemma is even more challenging in cytology specimen and small biopsies.^[5]

The cytologic features of metastatic low-grade ESS have rarely been described in the literature since it is rarely subjected to fine-needle aspiration.^[4,8-10] In the lung, it has been mistaken for carcinoid tumor, hamartoma, and endometriosis.^[4,5,9] A predominance of bland spindle cells can also be mistaken for leiomyoma and other benign spindle cell neoplasms.^[5,7,8]

The diagnostic challenges of low-grade ESS in cytology have been emphasized by others, and in most case reports of metastatic low-grade ESS, a definite diagnosis was achieved only after performing molecular studies. Zaharopoulos *et al.*^[10] first described a case of ESS that metastasized to the lung. The fine-needle aspiration biopsy of the lung lesion revealed small cells with scant cytoplasm and low mitosis. An ultrastructural study was performed which confirmed the diagnosis of metastatic ESS. Satoh *et al.*^[9] emphasized the diagnostic dilemma of metastatic low-grade ESS in transbronchial fine-needle aspiration (FNA) cytology where the initial diagnosis was thought to be a non-neoplastic lesion. On surgical resection, a diagnosis of pulmonary endometriosis was considered due to the presence of bland and round to oval cells with positive expression for ER and PR. There was no previous history of gynecologic malignancy; however, a cytogenetic and FISH analysis demonstrated a t(7;17) translocation, which confirmed the diagnosis of ESS.

Ronen *et al.*^[5] reported a case of metastatic ESS in a patient who presented with multiple lung nodules. The FNA smears showed bland, oval to spindle cells with moderate cytoplasm, and delicate vessels, but no matrix component. The differential diagnosis included carcinoid tumor and diffuse neuroendocrine hyperplasia; however, the IHC stains for neuroendocrine markers were negative, and CD10 was positive. A definitive diagnosis could not be rendered because of the limited nature of the cytology specimen. The nodule was subsequently resected, and histology revealed tumor cells with smooth muscle differentiation and positive staining for ER, PR, and desmin. On further clinical investigation, a history of recent hysterectomy for fibroids at another hospital was obtained. On re-review of slides from the hysterectomy specimen, a small focus of low-grade ESS with similar morphology to the lung metastasis was noted confirming the diagnosis.

Mindiola-Romero *et al.*^[8] described a similar clinical scenario of low-grade ESS metastatic to the lung in a patient who presented with multiple lung nodules. A CT-guided core biopsy with rapid on-site assessment demonstrated cells with oval and spindle nuclei with mild-to-moderate atypia and scant matrix component. The core biopsy demonstrated bland spindle cells. Immunohistochemical workup for spindle cell neoplasms was performed using markers for

desmin, S100, STAT6, CD34, and SOX-10 which were all negative. This prompted a molecular analysis that detected a fusion between exon3 of *JAZF1* and exon 2 of *SUZ12* supporting the diagnosis of low-grade ESS. Subsequently, immunohistochemical stains for ER, PR, and CD10 were positive corroborating the diagnosis. On further clinical investigation, the patient had a history of hysterectomy 25 years ago for ESS.

Metastatic low-grade ESS presenting as a solitary lung nodule as observed in our case is very rare. The predominance of small, round to oval cells with bland nuclei was thought to be consistent with a carcinoid tumor. Negative expression for neuroendocrine markers prompted review of the previous clinical history and additional IHC workup. Positive expression for ER, PR, CD10, and WT1 markers and a remote history of hysterectomy 26 years ago for endometrial sarcoma facilitated in making the right diagnosis. It must be emphasized that none of the above markers are specific for ESS; however, positive staining for WT1 has been shown to be a useful marker for differentiating extrauterine ESS from other potential mimics.^[11] IFITM1 is a novel marker for endometrial stroma cells with a higher specificity than CD10.^[12]

SUMMARY

This report highlights the diagnostic pitfall of metastatic LGESS in cytology specimens. The importance of clinical history and appropriate use of ancillary tests cannot be overemphasized. Awareness of the various cytomorphologic features and potential mimics is important.

COMPETING INTEREST STATEMENT BY ALL AUTHORS

The authors declare no competing interest.

AUTHORSHIP STATEMENT BY ALL AUTHORS

All authors contributed equally to the writing of this quiz.

ETHICS STATEMENT BY ALL AUTHORS

The quiz was written without patient identifier and institutional review board approval was not required.

LIST OF ABBREVIATIONS (In alphabetic order)

ESS - Endometrial stromal sarcoma

LGESS - Low grade endometrial stromal sarcoma.

EDITORIAL/PEERREVIEW STATEMENT

To ensure the integrity and highest quality of CytoJournal publications, the review process of this manuscript was

conducted under a **double-blind model** (authors are blinded for reviewers and vice versa) through automatic online system.

REFERENCES

- Hughes JH, Young NA, Wilbur DC, Renshaw AA, Mody DR, Cytopathology Resource Committee CoAP. Fine-needle aspiration of pulmonary hamartoma: A common source of false-positive diagnoses in the college of American pathologists interlaboratory comparison program in nongynecologic cytology. *Arch Pathol Lab Med* 2005;129:19-22.
- Capozzi VA, Monfardini L, Ceni V, Cianciolo A, Butera D, Gaiano M, *et al.* Endometrial stromal sarcoma: A review of rare mesenchymal uterine neoplasm. *J Obstet Gynaecol Res* 2020;46:2221-36.
- Chiang S, Oliva E. Recent developments in uterine mesenchymal neoplasms. *Histopathology* 2013;62:124-37.
- Aubry MC, Myers JL, Colby TV, Leslie KO, Tazelaar HD. Endometrial stromal sarcoma metastatic to the lung: A detailed analysis of 16 patients. *Am J Surg Pathol* 2002;26:440-9.
- Ronen S, Narula N, Koizumi JH, Hunt B, Giorgadze T. Low-grade endometrial stromal sarcoma presenting as multiple pulmonary nodules: A potential pitfall in fine needle aspiration and core biopsy specimens—a cytological-pathological correlation. *Ann Diagn Pathol* 2018;36:38-43.
- Satoh Y, Ishikawa Y, Miyoshi T, Mukai H, Okumura S, Nakagawa K. Pulmonary metastases from a low-grade endometrial stromal sarcoma confirmed by chromosome aberration and fluorescence *in-situ* hybridization approaches: A case of recurrence 13 years after hysterectomy. *Virchows Arch* 2003;442:173-8.
- Mahadeva R, Stewart S, Wallwork J. Metastatic endometrial stromal sarcoma masquerading as pulmonary lymphangiomyomatosis. *J Clin Pathol* 1999;52:147-8.
- Mindiola-Romero AE, Liu X, Dillon JL, Talarico M, Smith G, Zhang L, *et al.* Metastatic low-grade endometrial stromal sarcoma after 24 years: A case report and review of recent molecular genetics. *Diagn Cytopathol* 2021;49:E99-105.
- Satoh Y, Ishikawa Y, Furuta N, Tsuzuku M. Difficulty of cytodagnostic approaches to pulmonary metastases from a case of low grade endometrial stromal sarcoma. *Acta Cytol* 2003;47:1140-1.
- Zaharopoulos P, Wong JY, Lamke CR. Endometrial stromal sarcoma: Cytology of pulmonary metastasis including ultrastructural study. *Acta Cytol* 1982;26:49-54.
- Sumathi VP, Al-Hussaini M, Connolly LE, Fullerton L, McCluggage WG. Endometrial stromal neoplasms are immunoreactive with WT-1 antibody. *Int J Gynecol Pathol* 2004;23:241-7.
- Zhao W, Cui M, Zhang R, Shen X, Xiong X, Ji X, *et al.* IFITM1, CD10, SMA, and h-caldesmon as a helpful combination in differential diagnosis between endometrial stromal tumor and cellular leiomyoma. *BMC Cancer* 2021;21:1047.

How to cite this article: Lowrey TR, Sarode VR. Rapid on-site evaluation of a solitary lung nodule in a patient with remote history of hysterectomy: Cytologic findings and diagnostic challenges. *CytoJournal* 2023;20:15.

HTML of this article is available FREE at:
https://dx.doi.org/10.25259/Cytojournal_29_2022

The FIRST Open Access cytopathology journal

Publish in *CytoJournal* and RETAIN your copyright for your intellectual property

Become **Cytopathology Foundation Member** to get all the benefits

Annual membership fee is nominal US \$ 50 (US \$ 1000 for life)

In case of economic hardship it is free

For details visit <https://cytojournal.com/cf-member>

PubMed indexed

FREE world wide open access

Online processing with rapid turnaround time.

Real time dissemination of time-sensitive technology.

Publishes as many colored high-resolution images

Read it, cite it, bookmark it, use RSS feed, & many---



CYTOJOURNAL

www.cytojournal.com

Peer-reviewed academic cytopathology journal





NextGen CelBloking™ Kits

**Frustrated with your cell blocks?
We have a better solution!**

Nano

Nano NextGen CelBloking™

Cell block kit to process single scattered cell specimens and tissue fragments of **any** cellularity.



PATENT PENDING



Pack #1



Pack #2

Micro

Micro NextGen CelBloking™

For cellular specimens (more than 1 ml concentrated specimen with Tissuecrit more than 50%)



PATENT PENDING



Pack #2