

Quiz Case

Cervical lymphadenopathy with dual pathology: Interesting finding

Shruti Gupta, MD¹, Pawan Kumar, MD¹, Niraj Kumari, MD¹, Annanya Soni, MS²

Departments of ¹Pathology and ²Otolaryngology, AIIMS, Raebareli, Uttar Pradesh, India.



***Corresponding author:**

Shruti Gupta,
Department of Pathology,
AIIMS, Raebareli,
Uttar Pradesh, India.

drshrutimlb@gmail.com

Received: 11 November 2022

Accepted: 11 December 2022

Published: 01 September 2023

DOI

[10.25259/Cytojournal_52_2022](https://doi.org/10.25259/Cytojournal_52_2022)

Quick Response Code:



A 48-year-old male presented with a rapidly enlarging painless firm to hard, mobile, and non-tender lymph node approximately 2 cm deep in the left level II cervical region. Fine needle aspiration of the lymph node was performed (Figure 1).

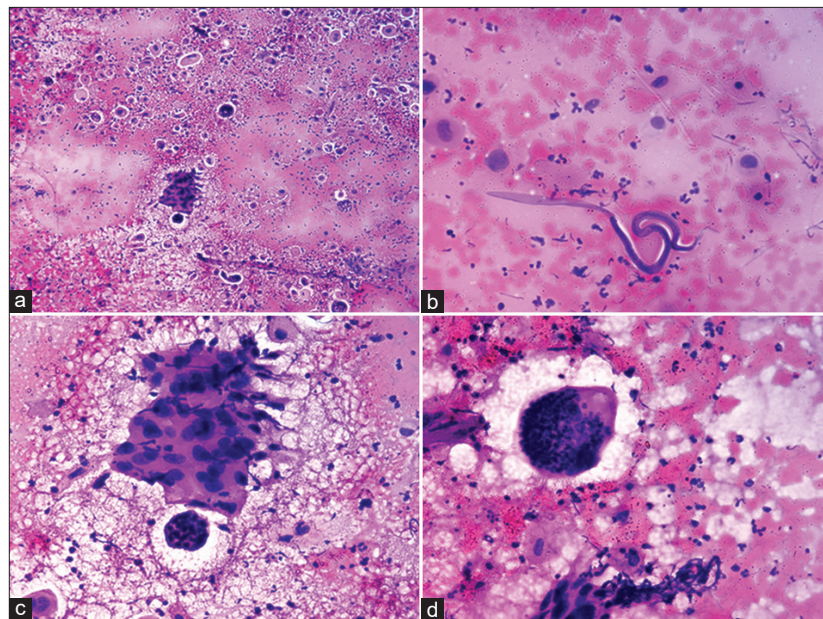


Figure 1: (a) Cellular smear showing discrete population of round to polygonal cells with pyknotic nuclei and dense cytoplasm with smoothly curved filarial worm covered with a hyaline sheath and a pointed tail. (b) Higher magnification showing worm along with tumour cells with squamoid differentiation. (c) Cellular smear showing discrete population of tumor cells having squamoid appearance and of transverse section of gravid female worm with numerous ovoid eggs. (d) Higher magnification of smoothly curved worm covered with a hyaline sheath and a pointed tail, devoid of nuclei. (a) MGG $\times 10$, (b) MGG $\times 40$, (c) H&E $\times 10$, (d) H&E $\times 40$.

Q1. What is your interpretation?

- Metastatic squamous cell carcinoma with microfilaria of *Wuchereria bancrofti*
- Metastatic adenocarcinoma with microfilaria of *W. bancrofti*
- Metastatic squamous cell carcinoma with microfilaria of *Brugia malayi*
- Metastatic adenocarcinoma with microfilaria of *B. malayi*

Answer: a. Metastatic squamous cell carcinoma with microfilaria of *Wuchereria bancrofti*

The cytological findings are consistent with metastatic squamous cell carcinoma with accompanying microfilaria in a necro-haemorrhagic background. The filarial worm is smoothly curved, covered with a hyaline sheath and a pointed tail. The body has multiple discrete evenly spaced nuclei with no terminal nuclei in the tail. The microfilaria is identified as *Wuchereria bancrofti* owing to characteristic smoothly curved worm with pointed tail, devoid of nuclei (Figure 1)

Table 1 elaborates the key differentiating features of commonly occurring sheathed filarial nematodes.

Table 1: Key differentiating features of commonly occurring sheathed filarial nematodes.			
Nematode	<i>Wuchereria bancrofti</i>	<i>Brugia malayi</i>	<i>Loa loa</i>
Length	244–296 μ	177–230 μ	231–250 μ
Cephalic space	Short	Long	Short
Tail	Pointed tail, devoid of nuclei	Two distinct nuclei on tail tip	Continuous discrete row of nuclei at the tail tip
Periodicity	Nocturnal	Nocturnal	Diurnal

Q2. Which of the following is not a characteristic feature of *W. bancrofti*?

- Pointed tail, devoid of nuclei
- Two distinct nuclei on tail tip
- Cephalic space is short
- Length of microfilaria ranges from 244 to 296 μ .

Answer: b

Q3. What could be the possible reason for lodgement of filaria in the metastatic sites?

- Increased vascularity of the tissues
- Transmigration of microfilaria along with metastatic tumor emboli
- Decreased host immune response
- All of the above.

Answer: d

BRIEF REVIEW OF THE TOPIC

Filariasis is a vector borne public health issue and is endemic all over India. In India, *W. bancrofti* accounts for majority of the total filarial infections.^[1] Filarial nematodes can be detected in peripheral blood, body fluids, urine, sputum, lymph node, thyroid, parotid, scrotum, and subcutaneous tissues along with a wide variety of metastatic

sites.^[2-4] Causative agents of human filariasis include *W. bancrofti*, *B. malayi*, *Brugia timori*, *Loa loa*, *Mansonella perstans*, *Mansonella ozzardi*, *Mansonella streptocerca*, and *Onchocerca volvulus*. Of all of the human filarial nematodes, *W. bancrofti* has the widest geographic distribution.^[5] The existence of filarial nematodes in association with metastatic deposits could be coincidental or may involve a different pathogenetic mechanisms. Filarial parasites exert profound immunoregulatory effects on the host immune system with both parasite-antigen specific and more generalized levels of immune modulation.^[6] The immune-modularity effects of microfilaria can be responsible for delayed post-operative healing after neck dissection.

Few authors have speculated that increased vascularity of the tissues and transmigration of microfilaria along with metastatic tumor emboli, decreased host immune response could be a possible reasons for lodgement of filarial in the metastatic sites.^[3,7,8]

SUMMARY

This case highlights the importance of diligent screening of all cytology smears in endemic regions as the occurrence of microfilaria in cervical nodes of patients with oral cavity malignancy requiring neck dissection can have different implications in post-operative healing.

COMPETING INTEREST STATEMENT BY ALL AUTHORS

The authors declare that they have no competing interests.

AUTHORSHIP STATEMENT BY ALL AUTHORS

Each author has participated sufficiently in the work and takes public responsibility for appropriate portions of the content of this article. All authors read and approved the final manuscript. Each author acknowledges that this final version was read and approved.

ETHICS STATEMENT BY ALL AUTHORS

This study protocol was reviewed and approved by the Institutional ethics committee AIIMS, Raebareli. The approval number is F. 8/BIOETHICS/AIIMS-RBL/COMM/OTH/2021/1 dated 03.07.2022.

LIST OF ABBREVIATIONS (In alphabetic order)

B. malayi – *Brugia malayi*
 H&E – hematoxylin & eosin
 MGG – May Grunwald Giemsa
W. bancrofti – *Wuchereria bancrofti*

EDITORIAL/PEERREVIEW STATEMENT

To ensure the integrity and highest quality of CytoJournal publications, the review process of this manuscript was conducted under a **double-blind model** (the authors are blinded for reviewers and vice versa) through automatic online system.

REFERENCES

1. Park K. Epidemiology of communicable diseases. In: Park's Textbook of Preventive and Social Medicine. 26th ed. Jabalpur, India: Bhanot Publishers; 2021.
2. Kishore M, Kumar V, Kaushal M, Gomber A. Cytology of achylous hematuria: A clue to an underlying uncommon clinical scenario. Cytojournal 2018;15:30.
3. Pantola C, Kala S, Agarwal A, Khan L. Microfilaria in cytological smears at rare sites coexisting with unusual pathology: A series of seven cases. Trop Parasitol 2012;2:61-3.
4. Rekhi B, Kane SV. Microfilariae coexisting with a follicular lesion in thyroid aspirate smears in an uncommon case of a retrosternal thyroid mass, clinically presenting as malignancy. Cytojournal 2011;8:4.
5. Mathison BA, Couturier MR, Pritt BS. Diagnostic Identification and differentiation of microfilariae. J Clin Microbiol 2019;57:e00706-19.
6. Babu S, Nutman TB. Immunology of lymphatic filariasis. Parasite Immunol 2014;36:338-46.
7. Vij M, Kumari N, Krishnani N. Microfilaria in liver aspiration

cytology: An extremely rare finding. Diagn Cytopathol 2011;39:521-2.

8. Gahine R, Das A, Jain VK, Agrawal A. Rare association of microfilaria with poorly differentiated mucin-secreting metastatic carcinoma in liver aspirate cytology. BMJ Case Rep 2019;12:e231618.

How to cite this article: Gupta S, Kumar P, Kumari N, Soni A. Cervical lymphadenopathy with dual pathology: Interesting finding. CytoJournal 2023;20:25.

HTML of this article is available FREE at:
https://dx.doi.org/10.25259/Cytojournal_52_2022

The FIRST Open Access cytopathology journal

Publish in CytoJournal and **RETAIN** your *copyright* for your intellectual property

Become Cytopathology Foundation Member to get all the benefits

Annual membership fee is nominal US \$ 50 (US \$ 1000 for life)

In case of economic hardship it is free

For details visit <https://cytojournal.com/cf-member>

PubMed indexed

FREE world wide open access

Online processing with rapid turnaround time.

Real time dissemination of time-sensitive technology.

Publishes as many **colored high-resolution images**

Read it, cite it, bookmark it, use RSS feed, & many----



CYTOJOURNAL

www.cytojournal.com

Peer-reviewed academic cytopathology journal





NextGen CelBloking™ Kits

**Frustrated with your cell blocks?
We have a better solution!**

Nano

Nano NextGen CelBloking™

Cell block kit to process single scattered cell specimens and tissue fragments of **any** cellularity.



PATENT PENDING



Pack #1



Pack #2

Micro

Micro NextGen CelBloking™

For cellular specimens (more than 1 ml concentrated specimen with Tissuecrit more than 50%)



PATENT PENDING



Pack #1



Pack #2