

Quiz Case

Granulomas on cervical Pap smear: “Forget me not”

Akriti Jindal, MD¹, Gargi Kapatia, MD, DNB, PDCC¹, Manjit Kaur Rana, MD¹, Lajya Devi Goyal, MS²

Departments of ¹Pathology and ²Gynecology and Obstetrics, AIIMS, Bathinda, Punjab, India.



***Corresponding author:**

Gargi Kapatia,
Department of Pathology,
AIIMS, Bathinda, Punjab,
India.

drgekapatia@gmail.com

Received: 27 October 2022

Accepted: 17 July 2023

Published: 01 September 2023

DOI

10.25259/Cytojournal_49_2022

Quick Response Code:



A 62-year-old female presented with the complaints of heaviness in the lower abdomen for 1 year. She was post-menopausal from the past 15 years. No prior history of fever or cough was present. On gynecological examination, her uterus was anteverted and cervix showed mild erosion. Routine Papanicolaou test was done and stained smears showed features as shown in Figure 1.

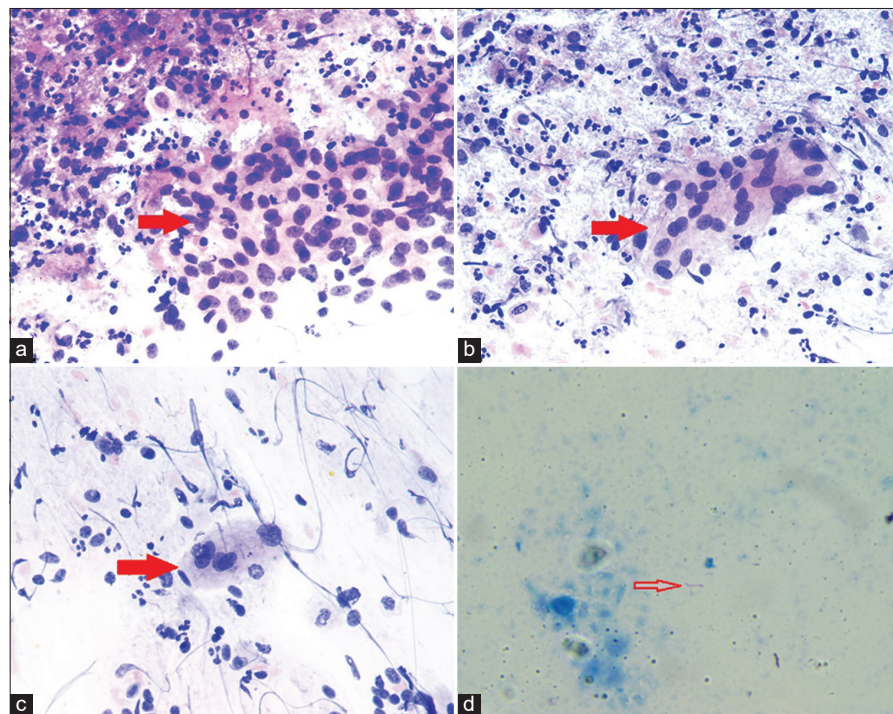


Figure 1: (a and b) Smears show well-formed collection of epithelioid cells forming granulomas (red arrow). The adjacent area shows parabasal cells and inflammation comprising of neutrophils and lymphocytes. ($\times 100$, Papanicolaou [PAP] stain); (c) Smear shows a multinucleated giant cell (red arrow) ($\times 100$, PAP stain); (d) Smear shows a beaded rod-shaped acid-fast bacillus (red arrow) ($\times 1000$ oil immersion, Ziehl Neelson stain).

1. What is your probable diagnosis?
 - a) Sarcoidosis
 - b) Granuloma Inguinale
 - c) Tuberculosis
 - d) Syphilis.

Answer to Question 1: (c)

The granulomas [Figure 1a and b] and multinucleated giant cell [Figure 1c] can be seen in all of the above conditions; however, positive acid-fast bacilli on Ziehl Neelson stain (ZN) are a characteristic feature of *Mycobacterium tuberculosis*.

Tuberculous bacilli are seen as a pink rod shaped slender bacilli on ZN stain [Figure 1d].

2. What is the mode of spread for cervical tuberculosis?
 - a) Hematogenous spread
 - b) Lymphatic spread
 - c) Primary infection
 - d) All of the above.

Answer to Question 2: (d)

Cervical tuberculosis (TB) can spread by any route – Hematogenous spread, lymphatic spread, or direct extension from the primary focus in the body. Rarely, primary route can be the cause of infection introduced by the male partner suffering from TB of genitourinary tract.

3. Which stain is used for the confirmation of TB infection?
 - a) Periodic Acid Schiff stain
 - b) Ziehl Neelson stain – 20%
 - c) Ziehl Neelson stain – 05%
 - d) Ziehl Neelson stain – 01%.

Answer to Question 3: (b)

The concentration of sulfuric acid varies in the ZN stain. About 20% of acid is used for *M. tuberculosis*, 5% of acid is used for *Mycobacterium leprae*, and 1% of acid is used for actinomyces and nocardia.

REVIEW OF THE TOPIC

TB is a significant cause of high morbidity and mortality and is more common in developing countries. TB of the female genital tract is a rare disease and more commonly involves the upper genital tract (fallopian tubes and endometrium) as compared to lower genital tract.^[1,2] TB of cervix is very rare as the stratified squamous epithelium is resistant to the tubercular bacilli.^[3] Cervical TB accounts for 0.1–0.65% of all the TB cases and 5–24% of the genital tract TB cases.^[1,2] The incidence of TB is on rise.^[1] It can occur at any age but commonly affects women of reproductive age group.^[4,5] The two common organisms responsible for genital TB are *M. tuberculosis* or *Mycobacterium bovis*.^[1] Genital tract TB usually occurs from the hematogenous spread of infection from the primary focus. Cervical TB almost always occur secondary to TB of fallopian tube or endometrium and is typically associated with pulmonary TB.^[1,2] It can occur by either hematogenous spread, lymphatic spread, or by direct extension from the primary focus.^[1,6,7] Rarely, primary route can be the cause of infection introduced by the partner suffering from TB of genitourinary tract.^[2,4] Chowdhury

suggested that sputum may also be source of infection when it is used as a sexual lubricant.^[4] The symptoms of genital TB can range from constitutional symptoms to infertility.^[1,2] The common presentations include abdominal pain, menstrual irregularities, discharge per vaginum, postmenopausal bleeding, etc.^[2] Grossly TB can present as papillary or vegetative growth, multiple tiny nodules or ulcer, and on imaging studies (hysterosalpingography or ultrasonography) of cervix, there can be seen diverticular outpouching of cervix with feathery appearance or cervical distortion etc.^[1,3] These features can be easily misinterpreted as cervical carcinoma.^[1] Microscopic examination of a cervical biopsy is characterized by well-formed epithelioid cell granulomas which may be associated with multinucleated Langhans type giant cell reaction and caseation necrosis. Lymphoplasmacytic infiltrates are seen at the rim of granulomas.^[2] TB of cervix needs to be differentiated from other granulomatous diseases, for example, lymphogranuloma venereum, sarcoidosis, schistosomiasis, amoebiasis, brucellosis, foreign body granuloma due to suture, crystal or cotton, and carcinoma cervix.^[2,8-11] The confirmation can be done by demonstration of acid fast bacilli of TB on ZN staining or isolation of mycobacterium.^[2] However, ZN stain and culture may be negative in one-third of the cases. In these cases, identification of typical granulomas is sufficient for the diagnosis of TB, if other causes of granulomatous cervicitis are excluded from the study.^[1,2] Newer diagnostic techniques such as enzyme linked immunosorbent assay or polymerase chain reaction may aid in the diagnosis of TB.^[8,9] The treatment includes anti tubercular therapy. The granulomas disappear after the treatment; however, fertility is low in patients even after the treatment due to subsequent healing by fibrosis and adhesions.^[4,5] The best method of preventing TB is Bacillus of Calmette Guerin vaccination and healthy lifestyle.^[5]

SUMMARY

Genital TB is a chronic disease in females with low-grade symptoms. It commonly involves fallopian tubes and endometrium. Cervix is an uncommon location for genitourinary TB. The gross appearance and imaging studies of cervical TB may mislead as cervical carcinoma. Therefore, microscopic examination and positive ZN stain and culture are diagnostic. TB may lead to fibrosis and adhesion and is a major cause of infertility among females. Therefore, screening for genital TB must be a part while evaluating for the menstrual irregularities or infertility. Early diagnosis and further treatment are the key to avoid the complications associated with TB.

Data availability statement

The data that support the findings of this study are available on request from the corresponding author. The data are not publicly available due to privacy or ethical restrictions.

COMPETING INTEREST STATEMENT BY ALL AUTHORS

There is no conflict of interest in this paper.

AUTHORSHIP STATEMENT BY ALL AUTHORS

Each author has participated sufficiently in the work and takes public responsibility for appropriate portions of the content of this article. All authors read and approved the final manuscript. Each author acknowledges that this final version was read and approved.

ETHICS STATEMENT BY ALL AUTHORS

As this is case without identifiers, our institution does not require approval from the Institutional Review Board (IRB).

LIST OF ABBREVIATIONS (In alphabetic order)

AFB – Acid Fast Bacilli
 ATT – Anti tubercular therapy
 BCG – Bacillus of Calmette Guerin
 ELISA – Enzyme linked immunosorbent assay
 PAP – Papanicolaou
 PCR – Polymerase chain reaction
 TB – Tuberculosis
 ZN – Ziehl Neelson.

EDITORIAL/PEERREVIEW STATEMENT

To ensure the integrity and highest quality of CytoJournal publications, the review process of this manuscript was conducted under a **double-blind model** (the authors are blinded for reviewers and vice versa) through automatic online system.

REFERENCES

1. Paprikar M, Biswas M, Bhattacharyav S, Sodhi B, Mukhopadhyay I. Tuberculosis of cervix. Med J Armed Forces India 2008;64:297-8.
2. Singh S, Gupta V, Modi S, Rana P, Duhan A, Sen R. Tuberculosis of uterine cervix: A report of two cases with variable clinical

- presentation. Trop Doct 2010;40:125-6.
3. Lamba H, Byrne M, Goldin R, Jenkins C. Tuberculosis of the cervix: Case presentation and a review of the literature. Sex Transm Infect 2002;78:62-3.
4. Chowdhury NN. Overview of tuberculosis of the female genital tract. J Indian Med Assoc 1996;94:345-6, 361.
5. Lester CW. Tuberculosis of uterine cervix. Am J Surg 1936;33:574-80.
6. Gupta B, Shree S, Rajaram S, Goel N. Genital tuberculosis: Unusual presentations. Int J Mycobacteriol 2016;5:357-9.
7. Moussa B, Valentin K, Adama O, Aziz DA, Idrissa Z, Gombri LO. Tuberculosis of the uterine cervix: About a case and literature review. Open J Obstet Gynecol 2016;6:734-9.
8. Grace GA, Devaleenal DB, Natrajan M. Genital tuberculosis in females. Indian J Med Res 2017;145:425-36.
9. Kesharwani H, Mohammad S, Pathak P. Tuberculosis in the female genital tract. Cureus 2022;14:e28708.
10. Kamal MM. The Pap smear in inflammation and repair. Cytojournal 2022;19:29.
11. Gupta D, Kaushal M, Jain S. Epithelioid cell granulomas in urine cytology smears: A diagnostic approach. Cytojournal 2022;19:34.

How to cite this article: Jindal A, Kapatia G, Rana MK, Goyal LD. Granulomas on cervical Pap smear: "Forget me not." CytoJournal 2023;20:24.

HTML of this article is available FREE at:
https://dx.doi.org/10.25259/Cytojournal_49_2022

The FIRST Open Access cytopathology journal
 Publish in CytoJournal and **RETAIN** your *copyright* for your intellectual property
Become Cytopathology Foundation Member to get all the benefits
 Annual membership fee is nominal US \$ 50 (US \$ 1000 for life)
In case of economic hardship it is free
For details visit <https://cytojournal.com/cf-member>

PubMed indexed
FREE world wide open access
Online processing with rapid turnaround time.
Real time dissemination of time-sensitive technology.
 Publishes as many **colored high-resolution images**
 Read it, cite it, bookmark it, use RSS feed, & many----

CYTOJOURNAL
www.cytojournal.com
 Peer-reviewed academic cytopathology journal





NextGen CelBloking™ Kits

**Frustrated with your cell blocks?
We have a better solution!**

Nano

Nano NextGen CelBloking™

Cell block kit to process single scattered cell specimens and tissue fragments of **any** cellularity.



PATENT PENDING



Pack #1



Pack #2

Micro

Micro NextGen CelBloking™

For cellular specimens (more than 1 ml concentrated specimen with Tissuecrit more than 50%)



PATENT PENDING



Pack #1



Pack #2