



Case Series

Metastases to pancreas diagnosed by endoscopic ultrasound-guided fine-needle aspiration: A case series and review of imaging and cytologic features

Valeria Caballero Malacara, MD¹, Claudia Gabriela Luna Limón, MD¹, Oralia Barboza Quintana, MD, PhD¹, Gabriela Sofía Gómez Macías, MD, PhD¹

¹Department of Anatomía Patológica y Citopatología, Hospital Universitario Dr. José Eleuterio González, Monterrey, Mexico.



***Corresponding author:**

Gabriela Sofía Gómez Macías,
Department of Anatomía Patológica y Citopatología,
Hospital Universitario Dr. José Eleuterio González, Monterrey, Mexico.

bpositivo66@hotmail.com

Received : 20 November 2022

Accepted : 06 April 2023

Published : 09 August 2023

DOI

[10.25259/Cytojournal_55_2022](https://doi.org/10.25259/Cytojournal_55_2022)

Quick Response Code:



ABSTRACT

Fine-needle aspiration (FNA) is ideal for the diagnosis of pancreatic neoplasms with high precision. We described five cases of metastases to the pancreas, highlighting the importance of clinical data, imaging features and the use of immunocytochemistry to lead the diagnosis. We retrospectively searched our archives for metastatic neoplasm to the pancreas diagnosed with FNA performed with endoscopic ultrasound, over a 5-year period. Furthermore, we reviewed the literature for imaging and cytologic features. We described five cases of metastatic neoplasms, a renal cell carcinoma, a breast carcinoma, one leiomyosarcoma, a hepatocellular carcinoma, and ovarian serous carcinoma. All of them has history of primary malignancy and were confirmed with immunostains. All the patients were asymptomatic and identified the metastasis during the follow-up, except for the ovarian serous carcinoma were the patient had acute abdominal pain, and the most common imaging feature were the irregular borders. Although the metastases to pancreas are rare, its important to always have the history of the patient, imaging features, and the suspicion at the moment of the evaluation of the smears and cell-block, because the management and prognostic its different compared to primary malignancies.

Keywords: Fine-needle aspiration-endoscopic ultrasound, Cytology, Metastases, Breast carcinoma, Renal cell carcinoma, Leiomyosarcoma, Hepatocellular carcinoma, Ovarian cell carcinoma

INTRODUCTION

Fine-needle aspiration (FNA) biopsy performed by endoscopic ultrasound (EUS) is a minimally invasive high-precision procedure, ideal for the diagnosis of pancreatic neoplasms due to their location.^[1,2] The pancreatic neoplasms most frequently diagnosed with this study are ductal adenocarcinoma, while metastases constitute <5% of malignant neoplasms.^[3] Due to the low frequency of the latter (metastases), the role of ultrasound-guided biopsy is not well described.^[4] In this article, we report a series of cases of pancreatic metastases diagnosed with EUS-guided FNA biopsies of patients from our institution.

CASE REPORT

Case 1

A 50-year-old female with a history of retroperitoneal leiomyosarcoma in 2009 treated with surgery and radiotherapy; the patient remained asymptomatic until 2020, when a tumor in thigh

was detected. Multiple imaging studies were performed, and a pancreatic tumor was evidenced. EUS was performed to take a biopsy, in which the neoplasm is well-defined, located in the neck and body of the pancreas, measuring 4.2×2.6 cm, hypoechoic and with irregular edges [Figure 1a]. The smears showed cohesive and spiculated cell groups, suspected recurrent leiomyosarcoma [Figure 1b]. The fresh clot fragments were fixed in 10% formalin to obtain the cell block, fascicles of cells with the same characteristics were observed in the sections. [Figure 1c], H-caldesmon immunohistochemical marker was performed [Figure 1d], which was positive, showing its muscular origin.

Case 2

Asymptomatic 65-year-old female with diagnosis of invasive breast carcinoma of not otherwise specified (NOS) in 2007, treated with hormonal therapy and surgery; on follow-up magnetic resonance a pancreatic tumor is seen so an EUS-guided FNA biopsy was performed. A neoplasm was observed in the head and body of the pancreas, measuring 2.9×2.1 cm, with irregular borders and no infiltration data [Figure 2a]. The FNA revealed malignancy, with cell groups and single cells with hyperchromatic and prominent nucleoli were observed in the smears [Figure 2b]. The fresh clot fragments were fixed in 10% formalin to obtain the cell block, cell nests with some lumens are observed in the cell-block section, with nuclear variability, hyperchromasia, so an adenocarcinoma was suspected [Figure 2c]. GATA3 immunohistochemical marker was performed [Figure 2d] and was interpreted as positive, which supports the diagnosis of metastatic breast carcinoma.

Case 3

A 53-year-old female diagnosed with moderately differentiated hepatocellular carcinoma in February 2021. An imaging study was performed to assess the extent of the disease and a tumor in the pancreas was observed, so an EUS-guided FNA biopsy was performed. Ultrasound revealed a 4.5×4.1 cm tumor in the tail of the pancreas, hyperechoic, and with irregular borders [Figure 3a and b]. FNA cytology smears showed groups of polygonal cell and granular cytoplasm [Figure 3c]. The fresh clot fragments were fixed in 10% formalin to obtain the cell block, in the sections, sheets of cells were observed with hyperchromatic nuclei rejected to the periphery [Figure 3d]. Immunohistochemical marker was made based on Glypican 3 [Figure 3e], which was positive, corroborating its hepatic origin.

Case 4

A 53-year-old female in follow-up care due to prior history of high grade serous ovarian carcinoma, treated with surgery

and chemotherapy; six years later is admitted to the emergency room due to abdominal pain and ascites. Imaging studies were performed, and a pancreatic tumor was observed, so an EUS-guided FNA biopsy was performed. The tumor was in the head and neck of the pancreas, measuring 3.9×3.8 cm, being hyperechoic, heterogeneous, and with irregular borders [Figure 4a and b]. The FNA aspiration smears showed cell groups with papillary architecture [Figure 4c]. The fresh clot fragments were fixed in 10% formalin to obtain the cell block, in the sections, the same characteristics were observed: Papillary architecture, hyperchromatic nuclei, and scant cytoplasm [Figure 4d]. Given the suspicion of a metastatic

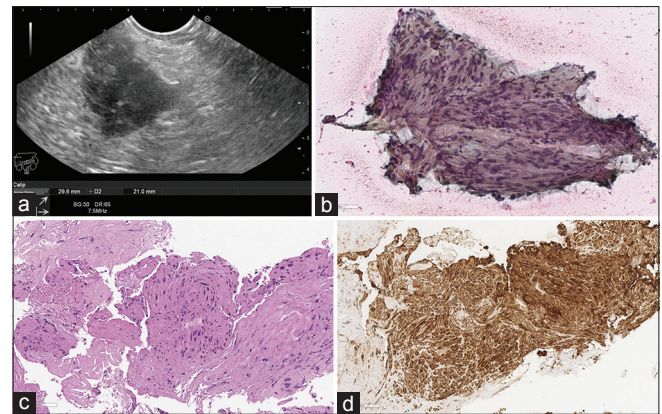


Figure 1: Endoscopic ultrasound image, conventional cytology, cell block, and immunohistochemistry of a metastatic leiomyosarcoma to the pancreas; (a) hypoechoic tumor with sharply delineated margins. (b) Cytology smear showing pleomorphic spindle cells, Papanicolaou $\times 200$. (c) Cell block section showing fascicles of spindle cells, cell-block, H&E $\times 200$. (d) Malignant cells positive for H-caldesmon, immunohistochemistry on cell-block, $\times 200$.

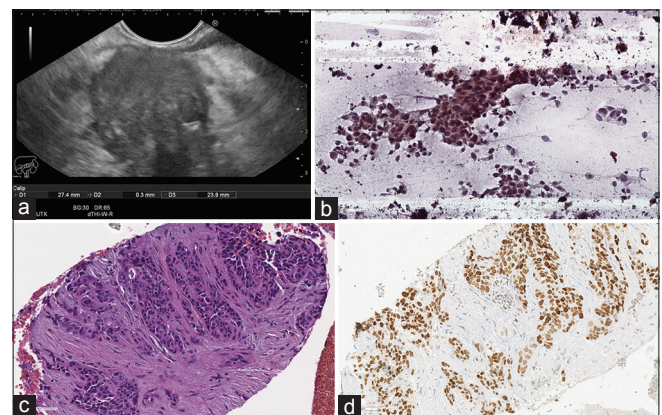


Figure 2: Endoscopic ultrasound image, conventional cytology, cell block, and immunohistochemistry of a metastatic breast carcinoma to the pancreas, (a) tumor with irregular margins. (b) Clusters and single cells, with increased nuclear to cytoplasmic ratio, Papanicolaou $\times 200$. (c) Nest of malignant cells with some glandular lumens, cell-block. H&E $\times 200$. (d) Malignant cells positive for GATA 3, block-cell immunohistochemistry $\times 200$.

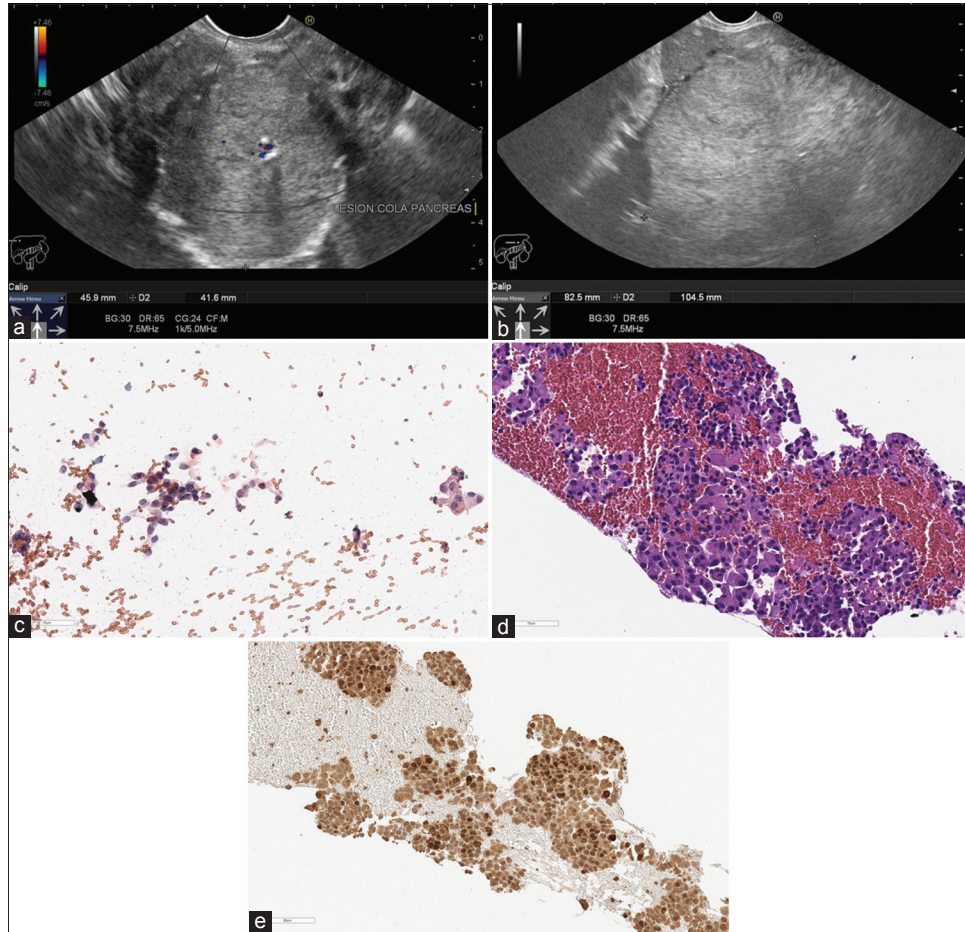


Figure 3: Endoscopic ultrasound image, conventional cytology, cell block and immunohistochemistry of a metastatic hepatic carcinoma to the pancreas, (a and b) hypoechoic tumor with well-defined borders. (c) Clusters of malignant cells with increased nuclear to cytoplasmic ratio and granular cytoplasm, Papanicolaou $\times 200$. (d) Malignant cells with hyperchromatic nuclei, in nests and trabecular architecture, cell-block H&E $\times 200$. (e) Malignant cells positive for Glypican 3, immunohistochemistry on cell-block, $\times 200$.

serous carcinoma, immunohistochemical markers, PAX8 [Figure 4e] and WT1 [Figure 4f], were requested, which were positive, supporting the diagnosis of metastasis.

Case 5

A 60-year-old female with hematuria and recurrent urinary tract infections, a CT is performed and a renal tumor with metastasis to the lung and pancreas is visualized, a nephrectomy is performed, where a clear cell renal cell carcinoma is diagnosed; chemotherapy is given without regression of metastatic lesions in the CT follow-up, so an EUS-guided FNA biopsy of the pancreatic neoplasms was performed. EUS showed two tumors, one in the body measuring 10.6×10.95 mm and the other one in the tail of the pancreas, measuring 17.9×14.3 mm, both hypoechoic and heterogeneous [Figure 5a and b]. In the FNA cytology smear, cohesive groups with pale and granular cytoplasm

were observed [Figure 5c]. The fresh clot fragments were fixed in 10% formalin to obtain the cell block, in the sections, the same cell nests with clear cytoplasm were observed [Figure 5d]; immunohistochemistry on cell-block revealed CD10 and PAX8 positivity [Figure 5e and f], thus confirming the diagnosis of metastasis of a clear cell variety renal cell carcinoma.

RESULTS

We report five metastatic tumors to the pancreas with a known primary neoplasm, identified mainly with computed tomography as a follow-up study in asymptomatic patients, except the patient with the metastatic ovarian serous carcinoma with acute abdominal pain. Four of the five cases were single masses, only one presented two tumors. The individual characteristics of the cases are listed in [Table 1]. A PubMed search was conducted on case series

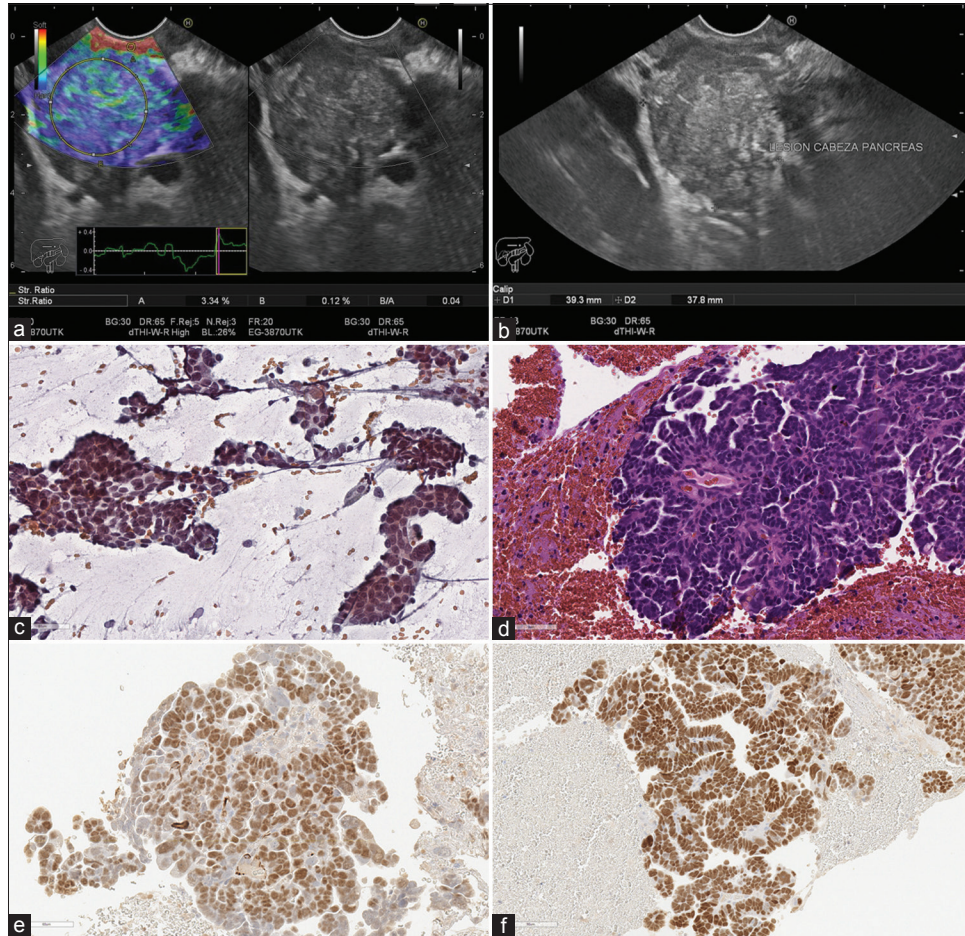


Figure 4: Endoscopic ultrasound image, conventional cytology, cell block and immunohistochemistry of a metastatic serous carcinoma to the pancreas, (a and b) hyperechoic tumor with irregular margins. (c) Clusters of malignant cells with papillary architecture, Papanicolaou $\times 200$. (d) Cells with hyperchromatic nuclei in hierarchical papillae with fibrovascular core, cell-block, H&E $\times 200$. Malignant cells positive for PAX8 (e) and WT1 (f), immunohistochemistry on cell-block, $\times 200$.

of pancreatic metastases using EUS-guided FNA biopsy as a diagnostic method, [Table 2] describes the main clinical characteristics, primary sites of neoplasia, as well as imaging findings.

DISCUSSION

Pancreatic metastases are very rare and defining the primary origin just by observing the morphology of the cells can be a challenge for the pathologist; for this reason, it is extremely important to carry out a comprehensive diagnosis that considers history, imaging studies, and morphology and thus choose a short immunohistochemical panel to confirm the primary origin.

It has been reported that patients around 60 years of age are the group with the highest risk of presenting pancreatic metastases without predilection of gender.^[5] The age of our patients coincides with that reported in the literature, since

the average age is 56 years; however, the female gender is was predominant.

On the other hand, the symptoms that occur most frequently in pancreatic metastases are non-specific: abdominal pain, malaise, and digestive tract bleeding in descending order.^[5,6] However, in some cases, the detection is made during the staging of the disease or on follow-up imaging studies.^[7] In our case series, the latter was the most common, except for one patient with acute abdominal pain and ascites.

The most common sites of primary neoplasms that metastasise to the pancreas are kidney, lung, breast, colon and skin (in descending order)^[8,9] and if the diagnosis is made on the metastasis, it gives it a worse prognosis.^[7] The head of the pancreas is the most common site and usually presents as a single mass which could cause confusion with a primary tumor, especially in patients without history of prior malignancy.^[10,11] The imaging feature in four of our five cases

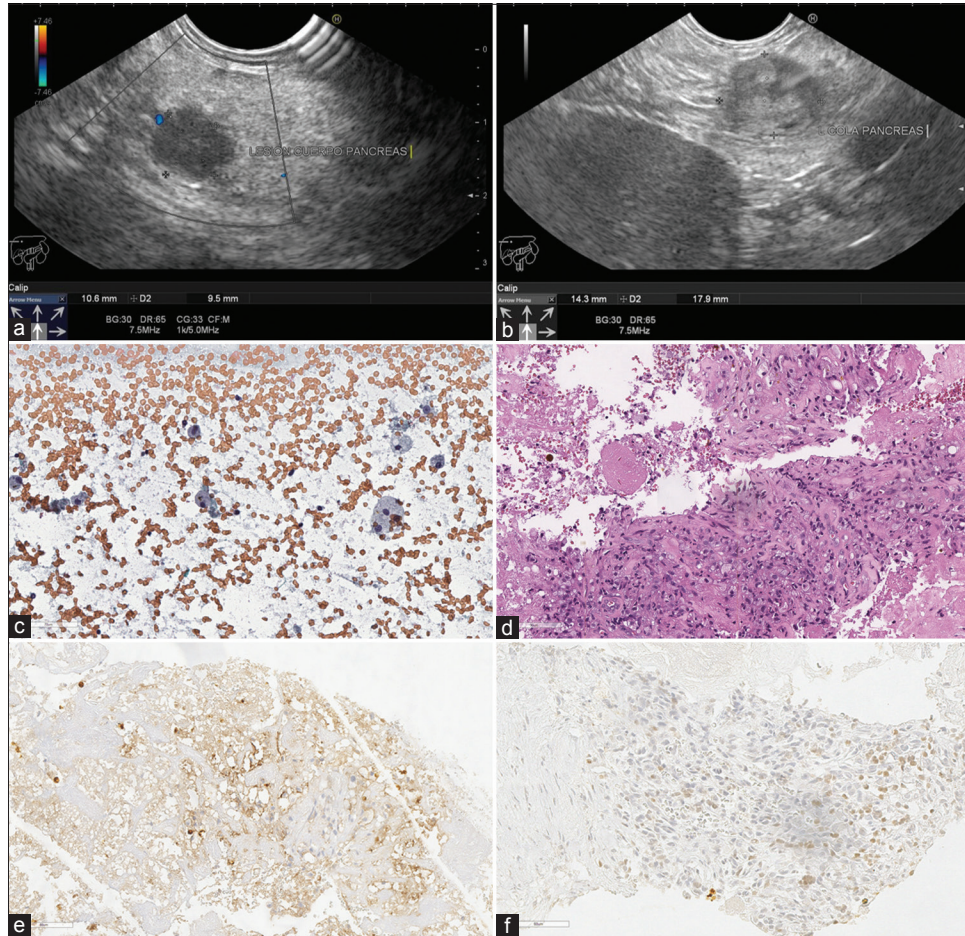


Figure 5: Endoscopic ultrasound image, conventional cytology, cell block and immunohistochemistry of a metastatic renal cell carcinoma to the pancreas. Tumor in head (a) and tail (b) of pancreas, hypoechoic and irregular margins. (c) Single cells with abundant clear cytoplasm, Papanicolaou $\times 200$. (d) Cell nests with hyperchromatic nuclei and clear vacuolated cytoplasm, cell-block H&E $\times 200$. Malignant cells positive for CD10 (e) and PAX8 (f), immunohistochemistry on cell-block, $\times 200$.

Table 1: Summary of the main clinical, imaging and immunohistochemistry findings of the metastases to pancreas diagnosed by EUS-FNA.

	Age	Previous history of malignancy	Site	Size of the tumor	Endoscopic ultrasound characteristics	Immunohistochemistry
Femenine (Case 1)	50	Retroperitoneal leiomyosarcoma in 2009	Neck and body	4.2 \times 2.6 cm	Hypoechoic and irregular borders	H-caldesmon (+)
Femenine (Case 2)	65	Breast carcinoma in 2007	Head and body	2.9 \times 2.1 cm	Irregular borders	Gata3 (+)
Femenine (Case 3)	53	Hepatocellular carcinoma in February 2021	Tail	4.5 \times 4.1 cm	Hyperechoic and irregular borders Invasion to splenic vein	Glypican-3 (+) Ck 7 (-)
Femenine (Case 4)	53	Ovarian high grade serous carcinoma in 2015	Head and neck	3.9 \times 3.8 cm	Hyperechoic and irregular borders Invasion to pancreatic duct and distal common bile duct	PAX8 (+) WT1 (+)
Femenine (Case 5)	60	Renal cell carcinoma in 2020	Two tumors, one in body and one in the tail	1 \times 1 cm 1.7 \times 1.4 cm	Hypoechoic and regular borders	PAX8 (+) CD10 (+)

Table 2: Literature review of the clinical and imaging features in metastases to the pancreas diagnosed by EUS-FNA.

Author	Previous history of cancer	Symptoms at diagnosis	Focality	Site	EUS Imaging features	Primary cancer
Ioakim <i>et al.</i> ^[2]	All patients had prior history of primary malignancy.	No referred	Unifocal 3/7 Multifocal 3/7	Head and tail 6/7 Body 1/7	Mean size 2 cm Solid 6/7	Renal cell carcinoma (3) Lung adenocarcinoma (1) Colon adenocarcinoma (1) Adrenal leiomyosarcoma (1) Small cell carcinoma of the bladder (1)
El Hajj <i>et al.</i> ^[5]	In 44 patients had prior history of primary malignancy, just in 5 cases the diagnosis was made in the metastases.	Abdominal pain 24/49 Abdominal pain and weight lost 12/49 Weight lost 2/49 Painless jaundice and weight lost 3/49 Painless icteric 2/49 Upper gastrointestinal bleeding 1/49 Asymptomatic 5/49	Unifocal 38/49 Multifocal 11/49	Head 28/49 Neck 6/49 Body 8/49 Tail 7/49	Mean size 3.4 cm Solid lesions 39/49 Solid-cystic 9/49 Cystic 1/49 Hypoechoic 39/49 Mixed 7/49 Hyperechoic 2/49 Anechoic 1/49	Kidney 21/49 Lung 8/49 Skin 6/49 Colon 4/49 Breast 3/49 Small bowel 2/49 Stomach 2/49 Ovary 1/49 Bladder 1/49
Sekulic, <i>et al.</i> ^[6]	In 23 patients had prior history of primary malignancy, 2 cases the first diagnosis was made in the metastases	Abdominal pain 13/25 Nausea and vomiting 2/25 Jaundice 1/25 Weight loss 1/25 Asymptomatic 8/25	Unifocal 17/25 Multifocal 8/25	Head 17 Body 11 Tail 9	Mean size 1.5 cm Hypoechoic 24/25 Mixed (hypoechoic e hyperechoic) 1/25 Irregular borders 2/25 Well-defined borders 14/25	Kidney 10/25 Colon 4/25 Ovary 3/25 Lung 2/25 Breast 1/25 Esophageal 1/25 Head and neck 2/25 Vulva 1/25 Soft tissue 1/25
Ardengh <i>et al.</i> ^[10]	In 29 patients had prior history of primary malignancy and in 6 cases the diagnosis was made first in the metastasis.	Abdominal pain 11/37 Abdominal pain and weight loss 6/37 Jaundice 5/37 Acute pancreatitis 2/37 Asymptomatic 13/37	Unifocal 34/37	Head 21/37 Tail 4/37 Neck 1/37 Body-tail 1/37 Head-body-tail 1/37	Mean size 4.2 cm Hypoechoic 34/37 Hyperechoic 2/37 Well-defined borders 23/37	Lymphoma 6/37 Colon 4/37 Kidney 4/37 Lung 3/37 Breast 2/37 Leiomyosarcoma 2/37 Stomach 1/37 Esophageal 1/37 Gallbladder 1/37 Liver 1/37 Mesothelioma 1/37 Myeloma 1/37 Ovary 1/37 Rhabdomyosarcoma 1/37 Melanoma 1/37

was a single mass coinciding with what was reported in the literature.

There are no typical ultrasonographic features in metastases to the pancreas, but the most frequent description is heterogeneous masses with well-defined edges,^[7] in our case series, most of the lesions were heterogeneous with irregular edges. So when patients are asymptomatic and have single masses, we have to confirm their malignancy and histological lineage.^[7]

In EUS-guided FNA biopsies, clinical information and diagnostic suspicion were asked to evaluate the smears. An average of three punctures was taken to ensure enough material, like reported case series, in which they vary from three to four punctures per patient.^[12] It should be noted that, in each case, a cellblock was obtained in which immunohistochemistry markers were performed to support the diagnosis.

A proper processing of the cellblock is important: poor fixation or the use of alcohol media can affect the results of immunohistochemistry and lead to an erroneous diagnosis. Unfixed cytology specimens which are later fixed in 10% formaldehyde allow the use of immunohistochemistry, having similar results as formaldehyde-fixed biopsies or surgical specimens. A disadvantage of this procedure is the random distribution of cells; sometimes, the number of diagnostic cells in each paraffin block might be scarce.^[13]

To diagnose metastasis to the pancreas by cytology, it is necessary to observe the morphology in the smears, as well as having a cell block to perform immunohistochemistry markers;^[12] which are needed to clarify if it is a primary tumor or a metastasis, because both clinical and surgical management are different.^[14]

The clinical management after diagnosis is variable because it is necessary to consider the personal characteristics of each patient: such as age, physical condition, tumor burden, and classification of the neoplasm among other factors. Pancreatic metastasis translates to an advanced state of the disease, in which there is spread of neoplasia, multiple tumors which make surgical treatment not an ideal option. However, there are few cases reported in the literature, in which surgical treatment is described, although the prognosis remains unfavorable.^[11,12]

The EUS-guided FNA biopsy is an appropriate method to make an histological diagnosis using immunohistochemistry markers to differentiate between a primary neoplasm or metastasis, because surgical approach and chemotherapy are different.

SUMMARY

Although metastases are rare, they should be considered as a diagnostic possibility in single and solid pancreatic

neoplasms, especially if the patient has prior history of malignancy. The ideal is to make a comprehensive diagnosis where the EUS-guided FNA biopsy, cytology, and immunohistochemistry confirm it to make the best therapeutic decision.

Acknowledgment

We thank to Dr. Joel Jaquez, Dr. Teresa Ruiz Siller, Dr. Raquel Garza Guajardo, Dr. Juan Pablo Flores, for your contribution in this work.

COMPETING INTEREST STATEMENT BY ALL AUTHORS

The authors declare that they have no competing interests.

AUTHORSHIP STATEMENT BY ALL AUTHORS

All listed authors contributed meaningfully to the writing of this paper.

ETHICS STATEMENT BY ALL AUTHORS

As this is a case series made retrospectively and without identifiers, our institution does not require approval from Institutional Review Board or its equivalent.

LIST OF ABBREVIATIONS (In alphabetic order)

CT – Computed tomography
EUS – Endoscopic ultrasound
FNA – Fine-needle aspiration
H&E – Hematoxylin and eosin
NOS – Not otherwise specified
RCC – Renal cell carcinoma.

EDITORIAL/PEERREVIEW STATEMENT

To ensure the integrity and highest quality of CytoJournal publications, the review process of this manuscript was conducted under a **double-blind model** (authors are blinded for reviewers and *vice versa*) through automatic online system.

REFERENCES

1. Smith AL, Odronic SI, Springer BS, Reynolds JP. Solid tumor metastases to the pancreas diagnosed by FNA: A single-institution experience and review of the literature. *Cancer Cytopathol* 2015;123:347-55.
2. Ioakim KJ, Sydney GI, Michaelides C, Sepsa A, Psarras K, Tsiotos GG, *et al.* Evaluation of metastases to the pancreas with fine needle aspiration: A case series from a single centre with review of the literature. *Cytopathology* 2020;31:96-105.

3. Shee K, Strait AM, Liu X. Biomarkers to diagnose metastatic breast carcinoma to the pancreas: A case report and update. *Diagn Cytopathol* 2019;47:912-7.
4. El Hajj II, Leblanc JK, Sherman S, Al-Haddad MA, Cote GA, McHenry L, *et al.* Endoscopic ultrasound-guided biopsy of pancreatic metastases: A large single-center experience. *Pancreas* 2013;42:524-30.
5. Song SW, Cheng JF, Liu N, Zhao TH. Diagnosis and treatment of pancreatic metastases in 22 patients: A retrospective study. *World J Surg Oncol* 2014;12:299.
6. Béchade D, Palazzo L, Desramé J, Duvic C, Hérody M, Didelot F, *et al.* Pancreatic metastasis of renal cell carcinoma: Report of three cases. *Rev Med Interne* 2002;23:862-6.
7. Ardengh JC, Lopes CV, Kemp R, Venco F, de Lima-Filho ER, dos Santos JS. Accuracy of endoscopic ultrasound-guided fine-needle aspiration in the suspicion of pancreatic metastases. *BMC Gastroenterol* 2013;13:63.
8. Romanini SG, Serrano JP, de Castro JS, Torres IT, Ingold A, Borini AL, *et al.* EUS-FNA diagnosis with core biopsy of pancreatic metastases from primary breast cancer. *Case Rep Gastrointest Med* 2020;2020:7136897.
9. El Jurdi K, Taleb A, Choucair K, Salyers W. An unusual case of urothelial cell carcinoma with metastasis to the pancreas. *Cureus* 2021;13:e14851.
10. Okasha HH, Pawlak KM, Zorniak M, Wiechowska-Kozłowska A, Naga YM, Elhusseiny R. EUS in the evaluation of metastatic lesions to the pancreas. *Endosc Ultrasound* 2020;9:147-50.
11. Woo SM, Park JW, Han SS, Choi JI, Lee WJ, Park SJ, *et al.* Isolated pancreatic metastasis of hepatocellular carcinoma after curative resection. *World J Gastrointest Oncol* 2010;2:209.
12. Sekulic M, Amin K, Mettler T, Miller LK, Mallery S, Stewart J Rd. Pancreatic involvement by metastasizing neoplasms as determined by endoscopic ultrasound-guided fine needle aspiration: A clinicopathologic characterization. *Diagn Cytopathol* 2017;45:418-25.
13. Shidham VB. CellBlockistry: Chemistry and art of cell-block making-a detailed review of various historical options with recent advances. *Cytojournal* 2019;16:12.
14. DeWitt J, Jowell P, Leblanc J, McHenry L, McGreevy K, Cramer H, *et al.* EUS-guided FNA of pancreatic metastases: A multicenter experience. *Gastrointest Endosc* 2005;61:689-96.

How to cite this article: Caballero Malacara V, Luna Limón CG, Barboza Quintana O, Gómez Macías GS. Metastases to pancreas diagnosed by endoscopic ultrasound-guided fine-needle aspiration: A case series and review of imaging and cytologic features. *Cytojournal* 2023;20:18.

HTML of this article is available FREE at:
https://dx.doi.org/10.25259/Cytojournal_55_2022

The FIRST Open Access cytopathology journal

Publish in *Cytojournal* and **RETAIN** your *copyright* for your intellectual property

Become Cytopathology Foundation Member to get all the benefits
 Annual membership fee is nominal US \$ 50 (US \$ 1000 for life)
In case of economic hardship it is free
For details visit <https://cytojournal.com/cf-member>

PubMed indexed
FREE world wide open access
Online processing with rapid turnaround time.
Real time dissemination of time-sensitive technology.
 Publishes as many **colored high-resolution images**
 Read it, cite it, bookmark it, use RSS feed, & many----


CYTOJOURNAL
www.cytojournal.com
Peer-reviewed academic cytopathology journal




NextGen CelBloking™ Kits

**Frustrated with your cell blocks?
We have a better solution!**

Nano

Nano NextGen CelBloking™

Cell block kit to process single scattered cell specimens and tissue fragments of **any** cellularity.



PATENT PENDING



Pack #1



Pack #2

Micro

Micro NextGen CelBloking™

For cellular specimens (more than 1 ml concentrated specimen with Tissuecrit more than 50%)



PATENT PENDING



Pack #2