



Research Article

Diagnostic clues for hyalinizing trabecular tumor on fine needle aspiration cytology

Lone Nielsen, MD,¹ Ana María Colino Gallardo, MD,¹ Pablo Pérez Alonso, MD,¹ Luis Ortega Medina, PhD,¹ Esthefania Latorre García, MD,² Cristina Díaz del Arco, MD,¹ Reyes Bergillos Jiménez, MD,¹ Lorenzo Alarcón García, MD,¹ Marta Cruz Blanco, MD,¹ Jesús Vega González, MD,¹ Montserrat De la Torre Serrano, MD,¹ María Jesús Fernández Aceñero, PhD,¹

¹Department of Pathology, Hospital Clínico San Carlos, Madrid, ²Department of Pathology, Hospital General Universitario Nuestra Señora del Prado, Talavera de la Reina, Spain.



***Corresponding author:**
Ana María Colino Gallardo,
Department of Pathology,
Hospital Clínico San Carlos,
Madrid, Spain.

amcolinog@gmail.com

Received: 18 May 2023
Accepted: 22 June 2023
Published: 29 August 2023

DOI
10.25259/Cytojournal_34_2023

Quick Response Code:



ABSTRACT

Objectives: The hyalinizing trabecular tumor (HTT) is a rare benign neoplasm of the thyroid gland. This neoplasm has overlapping cytological features with Papillary Thyroid Carcinoma, Medullary Carcinoma and Follicular Neoplasm with Nuclear Features of Papillary Carcinoma. This can lead to misdiagnosis of malignancy in fine needle aspiration (FNA) cytology specimens with unnecessary total thyroidectomy. The aim of this study is to determine if there are some cytological features that could help us to suspect HTT on FNA specimens and avoid radical surgery.

Material and Methods: With this purpose we have collected 6 cases diagnosed of HTT in Hospital Clínico San Carlos of Madrid (Spain) in the last 10 years and reviewed the cytological specimens.

Result: We conclude that the presence of hyaline material in FNA specimens of HTT is a constant feature being a diagnostic clue. We must be cautious not to confuse it with dense colloid or amyloid material, the latter seen in Medullary Carcinoma. Papillary architecture and fibrovascular cores are not present in a HTT. Special stains as ki-67, calcitonin and Congo Red staining could help us in achieving the correct diagnosis.

Conclusion: We feel the cytopathologists must be aware of the distinguishing features of this lesion, mainly the typical hyaline material to achieve a proper diagnosis and be able to reduce unnecessary aggressive management of these patients.

Keywords: Hyalinizing trabecular tumor, Hyaline material, Fine needle aspiration, Colloid, Nuclear pseudoinclusions

INTRODUCTION

Hyalinizing trabecular tumor (HTT) is a distinct rare benign neoplasm of the thyroid gland, first described in 1987 by Carney *et al.*^[1]

This neoplasm arises from the follicular cells of the thyroid. It shows some architectural features that mimic malignancy on the fine needle aspiration (FNA) cytology specimens, including papillary thyroid carcinoma (PTC), medullary thyroid carcinoma (MTC), and non-invasive follicular thyroid neoplasm with papillary-like nuclear features. Therefore, it is estimated that FNA only reaches the right diagnosis in 8% of the cases.^[2] This 92% false positive results rate can lead to an unnecessary partial or total thyroidectomy with the subsequent risks to the patients' health and undue costs.^[3-13]

The aim of this report is to review the cases of HTT diagnosed in our hospital in the past 10 years, emphasizing the cytologic features that can lead to a correct diagnosis and avoid an unnecessary total thyroidectomy.

MATERIAL AND METHODS

This is a retrospective case series from Hospital Clínico San Carlos in Madrid (Spain). Hospital Clínico is a large tertiary hospital with a population over 360,000 people and has a busy thyroid gland pathology outpatient clinic with dedicated head-and-neck radiologists and cytologists. All FNA cytologies are performed under ultrasonographic control with rapid on-site evaluation of the samples to increase diagnostic reliability.

We have performed a retrospective search of all thyroid gland resection specimens diagnosed as HTT and recorded in the electronic records (PAT-WIN) of the Pathology Department in the past 10 years.

The keywords used in the search were “hyalinizing” and “trabecular,” performing both searches separately. All cases found ($n = 6$) had a preoperative FNA, so we could include all the cases in the study.

The adequacy criteria for cytology samples were based on The Bethesda System for Reporting Thyroid Cytology as were the diagnosis categories employed for diagnostic classification of the cytology specimens.

In all the cases we had air-dried and alcohol fixed cytological specimens. A Papanicolaou stain had been performed at the time of diagnosis in the alcohol fixed specimens and a Diff-Quick stain in the air-dried ones. All patients had consented to their procedure following the institutional guidelines.

For the aim of this study, we only reviewed the original slides and did not perform either immunocytochemistry or molecular techniques in any of the cytologic samples.

The study has been reviewed and approved by the hospital institutional review board.

RESULTS

Our results are summarized in [Table 1]. In a 10-year period, we have diagnosed six cases of histology-proven HTT in our Hospital. We have a predominance of female gender with five females and one male. All patients were over 50 years of age, with a mean age of 61.3 years (range 52–68 years). Half of our lesions involved the isthmus of the thyroid. Two cases (33.3%) involved the left lobe and only one case the right lobe. The tumor size ranged from 0.7 cm to 4 cm. Most of the lesions were not larger than 2 cm (66.6%). Analyzing the ultrasonographic features, all the lesions were solid and hypoechoic. Two of them showed microcalcifications. Only one case had a

Table 1: Clinicopathological features of HTT in our series.

Features	Number (n)
Sex	
Women	5
Men	1
Mean age	61.3 (range: 52–68)
Laterality of lesions	
Left lobe	2
Right lobe	1
Isthmus	3
Tumor size	
≤1 cm	1
>1–≤2 cm	3
>2 cm	2
Ultrasonographic features	
Hypoechoic solid nodule	6
Microcalcifications	2
Heterogeneous	1
Bethesda cytological diagnostic categories	
II	1
III	0
IV	2
V	1
VI	2
Thyroidectomy	
Total	5
Partial	1
None	0
Associated thyroid pathologies	
MNG	3
LT	2
MNG+LT	1
Previous FNA	
Yes	3
No	3
HTT: Hyalinizing trabecular tumor, MNG: Multinodular Goiter, LT: Lymphocytic thyroiditis, FNA: Fine needle aspiration	

heterogeneous ultrasonographic pattern. In one case, the radiologists described a high intratumoral vascularity. Five of the six cases were diagnosed as suspicious of Follicular/Hürthle Cell Neoplasm (category IV), suspicious of PTC (category V), or positive for malignancy consistent with PTC (category

VI). Only one of the cases was diagnosed as benign. In this case, the cytopathologist added a comment indicating that the cytological specimen was rich in Hürthle cells. None of them fell into the category of atypia of undetermined significance (Bethesda III). All of our patients underwent thyroidectomy and only one of them was partial. Two of these patients developed a postoperative hypothyroidism refractory to treatment with thyroid hormones. All the patients have other histologically-proven thyroid pathologies associated with the HTT. Three of them have multinodular goiter; two patients had lymphocytic thyroiditis (LT), and one patient has both pathologies. Before the diagnosis of HTT, three patients had undergone previous FNA and all of these cases had been diagnosed as category III of atypia of undetermined significance.

Cytological findings

[Table 2] summarizes the cytological features of our cases. All the samples showed a bloody background with little or no colloid and the smears were hyper to moderately cellular. Only one case shows little dense colloid, resembling the chewing-gum aspect of PTC associated colloid. A thorough retrospective review of the slides revealed the presence of an extracellular hyaline material in all the cases [Figure 1]. In two of them, it was abundant and in the other four cases, it was more subtle. This material is diffusely distributed through the slides and it is frequently seen around the cell groups in a small quantity. This material was overlooked at the time of diagnosis, probably misinterpreted as dense colloid [Figures 1 and 2]. Two of the cases show psammomatous calcifications [Figure 2]. None of the cases have a papillary architecture, fibrovascular cores, or abundant discohesive cells. The cells are mainly arranged in large monolayered sheets or large to small cohesive groups. The cells present an ample polygonal/fusiform cytoplasm with no clear-cut cell borders. The nucleus is central or eccentrically placed with a low nucleus to cytoplasmic ratio. None of the cases present a nuclear clearing. Three of the cases present pseudoinclusions and nuclear grooves [Figures 3 and 4]. We identified nucleoli in all cases. In two of the cases, this finding was prominent.

DISCUSSION

HTT is a rare benign lesion that occurs between the fourth and seventh decade of life with a marked female predilection.^[2]

The elongated or polygonal morphology of the cells together with the nuclear grooves and pseudoinclusions may lead to a misdiagnosis of PTC or FNNFPTC. The background hyaline material can be confused with MTC.^[2,14-18]

HTT shows a distinctive cell membrane and cytoplasmic positivity for Ki-67, but only when clone MIB-1 is used and the reaction is performed at room temperature. It has been described both in cytological and histology specimens. If these peculiarities are not taken into account, it could

Table 2: Cytological features of the six cases of HTT in our series.

Features	Number (n)
Background	
Bloody	6
Others	0
Cellularity	
High/moderate cellularity	6
Low cellularity	0
Colloid	
Abundant	0
Moderate	0
Scant	1
Hyaline material	
Abundant/moderate	2
Scant	4
Calcifications	
Present	2
None	4
Architecture	
Papillary	0
Fibrovascular cores	0
Discohesive cells	0
Other (large sheets, macro, and microfollicles, trabecular sheets)	6
Cytoplasmic features	
Elongated/polygonal cells	6
Other	0
Nuclear to cytoplasmic ratio	
High	0
Low	6
Nuclear features	
Pseudoinclusions/grooves	3
Chromatin clearing	0
Nuclei	
Macronucleoli	2
Micronucleoli	4
Absent	0
HTT: Hyalinizing trabecular tumor	

result in a low-grade nuclear positivity and will lead to a misdiagnosis.^[19] HTTs are also positive for thyroglobulin and thyroid transcription factor 1, although their staining

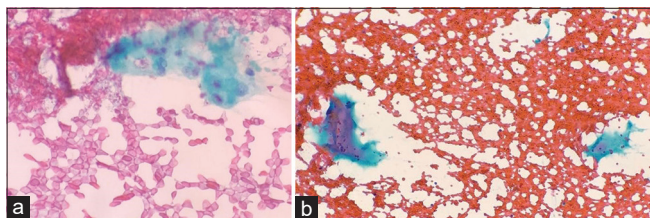


Figure 1: Hyaline material (a) with intermingled discohesive cells, one of them showing an intranuclear pseudoinclusion, in a bloody background. We must differentiate this material from the dense colloid (b) with a more homogeneous aspect, without intermingled cells and more blunt and sharp edges.

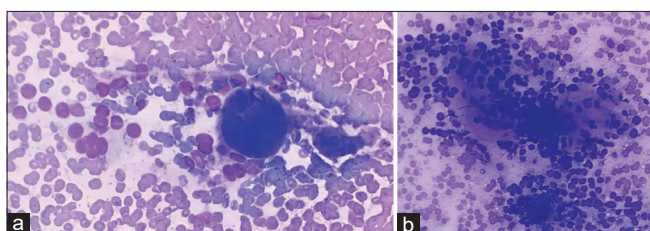


Figure 2: (a and b) Hyaline material between small groups of polygonal/fusocellular shaped cells.

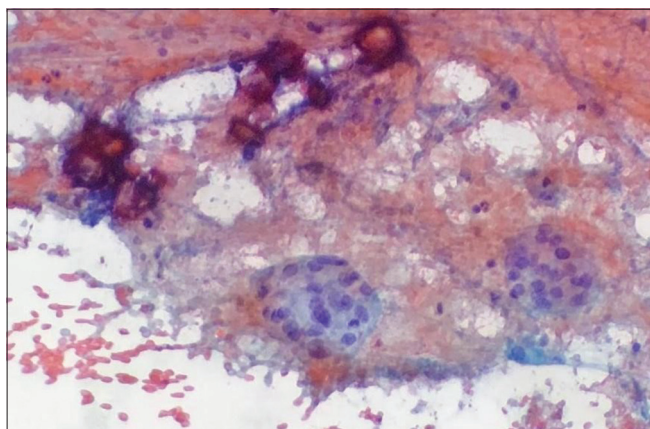


Figure 3: Psammomatous calcifications.

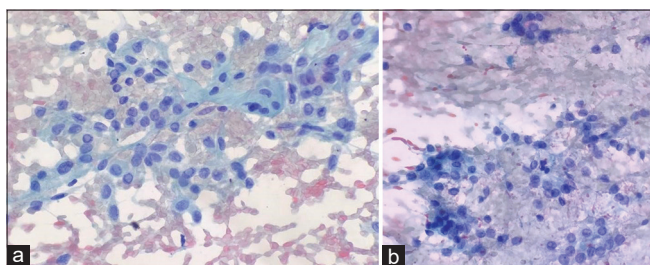


Figure 4: (a and b) Discohesive sheets of elongated cells with nuclear grooves and nuclear pseudoinclusions and scant hyaline material in the bloody background. The elongated features of the cells can lead to a misdiagnosis of medullary thyroid carcinoma.

are focal and weak with hector battifora mesothelial-1 and galectin. They are usually negative for cytokeratins, chromogranin, and calcitonin.

Recently, a rearrangement of PAX8-GLIS3, and less frequently PAX8-GLS1, has been discovered. This is a particular molecular alteration seen only in HTT and not in PTC. It could be a useful tool to distinguish between both entities.^[20] All HTT demonstrated a BRAF wild-type phenotype. A BRAF mutation would exclude this entity favoring a PTC.^[21-24] The immunohistochemical characteristics and molecular alterations of HTT and PTC are summarized in [Table 3].

In our series of cases, imaging studies (ultrasonography, US) are not always a helpful tool in distinguishing a HTT from a PTC, due to the overlapping radiological features, such as microcalcifications.

However, in a recent review published by Scaglietti *et al.*,^[2] they suggest that we have to keep in mind the diagnosis of HTT when the US suggest benignancy but the cytology specimen is suggestive for PTC.

A hypercellular or moderate cytology sample with scant or no colloid, the absence of papillary or fibrovascular structures

Table 3: Comparative table of immunochemical and molecular features between HTT and PTC.

Entities	HTT	PTC
Immunochemical features		
Thyroglobulin	Positive	Positive
TTF1	Positive	Positive
PAX8	Positive	Positive
HBME1	Positive (focal and weak)	Positive (diffuse)
Galectin-3	Positive (focal and weak)	Positive (diffuse)
Ki67 (MIB-1 clone)	Positive (membranous)	Positive (nuclear)
CK19	Negative	Positive
Molecular alterations		
BRAF V600E mutation	-	Present
PAX8-GLIS3 rearrangement	Present (most frequent)	-
PAX8-GLS1 rearrangement	Present (less frequent)	-

HTT: Hyalinizing trabecular tumor, PTC: Papillary thyroid carcinoma, TTF1: Thyroid transcription factor 1, HBME1: Hector battifora mesothelial-1

with or without nuclear pseudoinclusions that does not fit in an exact Bethesda Category requires a careful search for the presence of hyaline material.

This hyaline material may be arranged in central cores surrounded by neoplastic cells or in the background of the sheets, like Scaglietti *et al.* reported.

We have to be careful not to misinterpret the hyaline material as colloid or amyloid. The latter is an acellular amorphous irregular fragment with scalloped or pointed edges, that stains eosinophilic with Papanicolaou stain and deep blue with Diff-Quick stain. To identify it on cytological specimens, we suggest the possibility to perform Congo Red Staining.^[25] Distinction between hyaline material and colloid is exclusively morphological. The main problem is to distinguish dense colloid from the hyaline material. Colloid has net blunt edges as droplets and often shows glass-cracking appearance without fibrillary borders in contrast with the hyaline material of HTT. Colloid stains dark-blue with Diff-Quick Stain and orange-pink with Papanicolaou stain.

It could be helpful to perform immunochemistry with Ki-67 and molecular testing of mutations in BRAF. Even if we do not perform immunochemistry and molecular testing and we find some structures that suggest hyaline material, we could leave a note reporting that the cytology specimen has features of categories IV, V, or VI of Bethesda System, but we cannot exclude with certainty that the lesion is not a HTT. This leaves the surgeon a chance to evaluate the possibility of performing a partial thyroidectomy instead of a total thyroidectomy.

The presence of other concomitant thyroid pathologies may contribute to make the correct diagnosis more difficult and the coexistence with LT may push the cytopathologist to give a diagnosis of suspicious of PTC. It is recommended to keep in mind the high frequency of concomitant pathology in HTT.

This article has some limitations. First its retrospective nature and being based on histopathological diagnosis of this entity. We cannot be sure that some cases of this entity received a different diagnosis. In our hospital, the cytology reports did not use the Bethesda System until 2013. We have reclassified the prior cases based on the description made in the report. On the other hand, we have not full access to the radiological images, have not reviewed the cases and have only relied on the radiological report, so it is possible that we have missed some important radiological information.

CONCLUSION

HTT is a rare entity, frequently misdiagnosed in cytological samples. After reviewing our cases, we feel that the cytopathologists must be aware of the distinguishing features of this lesion, mainly the typical hyaline material and learn to differentiate it from other kinds of background material.

We feel if we know this entity and its typical features proper diagnosis is possible with cytology and can reduce unnecessary aggressive management of these patients.

COMPETING INTEREST STATEMENT BY ALL AUTHORS

The authors declare no conflicts of interest regarding the publication of this paper.

FUNDING SOURCES

No specific funding was disclosed.

AUTHORSHIP STATEMENT BY ALL AUTHORS

All authors declare that they are part of the current work through its ideation, development and revision.

ETHICS STATEMENT BY ALL AUTHORS

Study approval statement

This study protocol was reviewed and approved by Comité de Ética para la Asistencia Sanitaria (CEAS) of Hospital Clínico San Carlos, approval number [22-001].

Consent to publish statement

This study has informed consent for the use of data and images, which likewise are not linked to the patients in any way.

Data availability statement

The data used in this work are not available as they are in the private file of the Hospital Clínico San Carlos.

LIST OF ABBREVIATIONS (In alphabetic order)

FNA - Fine needle aspiration
 FNNFPTC - Follicular neoplasm with nuclear features of papillary thyroid carcinoma
 HBME1 - Hector battifora mesothelial-1
 HTT - Hyalinizing trabecular tumor
 LT - Lymphocytic thyroiditis
 MNG - Multinodular goiter
 MTC - Medullary thyroid carcinoma
 PTC - Papillary thyroid carcinoma
 TTF1 - Thyroid transcription factor 1.

EDITORIAL/PEERREVIEW STATEMENT

To ensure the integrity and highest quality of CytoJournal publications, the review process of this manuscript was conducted under a **double-blind model** (the authors are blinded for reviewers and vice versa) through automatic online system.

REFERENCES

- Carney JA, Ryan J, Goellner JR. Hyalinizing trabecular adenoma of the thyroid gland. *Am J Surg Pathol* 1987;11:583-91.
- Scaglietti C, Piana S, La Rosa S, Bongiovanni M. Hyalinizing trabecular tumour of the thyroid: Fine-needle aspiration cytological diagnosis and correlation with histology. *J Clin Pathol* 2017;70:641-7.
- Kim T, Oh YL, Kim KM, Shin JH. Diagnostic dilemmas of hyalinizing trabecular tumours on fine needle aspiration cytology: A study of seven cases with BRAF mutation analysis. *Cytopathology* 2011;22:407-13.
- Howard BE, Gnagi SH, Ocal IT, Hinni ML. Hyalinizing trabecular tumor masquerading as papillary thyroid carcinoma on fine-needle aspiration. *ORL J Otorhinolaryngol Relat Spec* 2014;75:309-13.
- Jang H, Park CK, Son EJ, Kim EK, Kwak JY, Moon HJ, *et al.* Hyalinizing trabecular tumor of the thyroid: Diagnosis of a rare tumor using ultrasonography, cytology, and intraoperative frozen sections. *Ultrasonography* 2016;35:131-9.
- Jones DJ, Kieliszak CR, Patel SS, Selinsky CR. Hyalinizing trabecular tumor of the thyroid gland and its significant diagnostic issue. *Thyroid Res* 2017;10:7.
- Rhee YY, Jung HK, Kim SH, Kim SH. Hyalinizing trabecular tumor of the thyroid gland, a diagnostic challenge in fine-needle aspiration cytology: Case report. *J Pathol Transl Med* 2018;52:252-6.
- Arena S, Latina A, Marturano I, Muscia V, Manusia M, Italia S, *et al.* Cytological diagnosis difficulties in hyalinizing trabecular adenoma of the thyroid. *J Endocrinol Invest* 2011;34:887-8.
- Akin MR, Nguyen GK. Fine-needle aspiration biopsy cytology of hyalinizing trabecular adenomas of the thyroid. *Diagn Cytopathol* 1999;20:90-4.
- Baloch ZW, Puttaswamy K, Brose M, LiVolsi VA. Lack of BRAF mutations in hyalinizing trabecular neoplasm. *Cytojournal* 2006;25:17.
- Kuma S, Hirokawa M, Miyauchi A, Kakudo K, Katayama S. Cytologic features of hyalinizing trabecular adenoma of the thyroid. *Acta Cytol* 2003;47:399-404.
- Bondeson L, Bondeson AG. Clue helping to distinguish hyalinizing trabecular adenoma from carcinoma of the thyroid in fine-needle aspirates. *Diagn Cytopathol* 1994;10:25-9.
- Goellner JR, Carney JA. Cytologic features of fine-needle aspirates of hyalinizing trabecular adenoma of the thyroid. *Am J Clin Pathol* 1989;91:115-9.
- Ali S, Cibas ES. *The Bethesda System for Reporting Thyroid Cytopathology*. 2nd ed. Berlin, Germany: Springer; 2018.
- Nikiforov YE, Sethala RR, Tallini G, Baloch ZW, Basolo F, Thompson LD, *et al.* Nomenclature revision for encapsulated follicular variant of papillary thyroid carcinoma: A paradigm shift to reduce overtreatment of indolent tumors. *JAMA Oncol* 2016;2:1023-9.
- Howitt BE, Chang S, Eslinger M, Paschke R, Drage MG, Krane JF, *et al.* Fine-needle aspiration diagnoses of noninvasive follicular variant of papillary thyroid carcinoma. *Am J Clin Pathol* 2015;144:850-7.
- Bizzarro T, Martini M, Capodimonti S, Straccia P, Lombardi CP, Pontecorvi A, *et al.* Young investigator challenge: The morphologic analysis of noninvasive follicular thyroid neoplasm with papillary-like nuclear features on liquid-based cytology: Some insights into their identification. *Cancer Cytopathol* 2016;124:699-710.
- Faquin W, Wong L, Afrogheh A, Ali SZ, Bishop JA, Bongiovanni M, *et al.* Impact of reclassifying noninvasive follicular variant of papillary thyroid carcinoma on the risk of malignancy in the Bethesda System for Reporting Thyroid Cytopathology. *Cancer Cytopathol* 2016;24:181-7.
- Leonardo E, Volante M, Barbareschi M, Cavazza A, Dei Tos AP, Bussolati G, *et al.* Cell membrane reactivity of MIB-1 antibody to Ki67 in human tumors: Fact or artifact? *Appl Immunohistochem Mol Morphol* 2007;15:220-3.
- Nikiforova MN, Nikitski AV, Panebianco F, Kaya C, Yip L, Williams M, *et al.* GLIS rearrangement is a genomic hallmark of hyalinizing trabecular tumor of the thyroid gland. *Thyroid* 2019;29:161-73.
- Sheu SY, Vogel E, Worm K, Grabellus F, Schwertheim S, Schmid KW. Hyalinizing trabecular tumour of the thyroid-differential expression of distinct miRNAs compared with papillary thyroid carcinoma. *Histopathology* 2010;56:632-40.
- Gaffney RL, Carney JA, Sebo TJ, Erickson LA, Volante M, Papotti M, *et al.* Galectin-3 expression in hyalinizing trabecular tumors of the thyroid gland. *Am J Surg Pathol* 2003;27:494-8.
- Hino R, Motoi N, Toda K, Ebina A, Yamada K, Higuchi M, *et al.* Stromal tiny black dots, like “sugarcoated”, of von Kossa stain is a diagnostic clue to hyalinizing trabecular tumor of the thyroid gland. *Pathol Int* 2018;68:176-82.
- Lenggenhager D, Maggio EM, Moch H, Rössle M. HBME-1 expression in hyalinizing trabecular tumours of the thyroid gland. *Histopathology* 2013;62:1092-7.
- Michael CW, Naylor B. Amyloid in cytologic specimens. Differential diagnosis and diagnostic pitfalls. *Acta Cytol* 1999;43:746-55.

How to cite this article: Nielsen L, Colino Gallardo AM, Pérez Alonso P, Ortega Medina L, Latorre García E, Díaz del Arco C, *et al.* Diagnostic clues for hyalinizing trabecular tumor on fine needle aspiration cytology. *CytoJournal* 2023;20:19.

HTML of this article is available FREE at:
https://dx.doi.org/10.25259/Cytojournal_34_2023

The FIRST **Open Access** cytopathology journal

Publish in *CytoJournal* and **RETAIN** your *copyright* for your intellectual property

Become Cytopathology Foundation Member to get all the benefits

Annual membership fee is nominal US \$ 50 (US \$ 1000 for life)

In case of economic hardship it is free

For details visit <https://cytojournal.com/cf-member>

PubMed indexed

FREE world wide open access

Online processing with rapid turnaround time.

Real time dissemination of time-sensitive technology.

Publishes as many **colored high-resolution images**

Read it, cite it, bookmark it, use RSS feed, & many---



CYTOJOURNAL

www.cytojournal.com

Peer-reviewed academic cytopathology journal





NextGen CelBloking™ Kits

**Frustrated with your cell blocks?
We have a better solution!**

Nano

Nano NextGen CelBloking™

Cell block kit to process single scattered cell specimens and tissue fragments of **any** cellularity.



PATENT PENDING



Pack #1



Pack #2

Micro

Micro NextGen CelBloking™

For cellular specimens (more than 1 ml concentrated specimen with Tissuecrit more than 50%)



PATENT PENDING



Pack #2