




Research Article

# Usefulness of the human papillomavirus DNA chip test as a complementary method for cervical cytology

Rae-Young Lee, PhD,<sup>1</sup> Joo-Yeon Koo, MD,<sup>1</sup> Nah-Ihm Kim, MD, PhD,<sup>1</sup> Sung-Sun Kim, MD, PhD,<sup>1</sup> Jong-Hee Nam, MD, PhD,<sup>1</sup> Yoo-Duk Choi, MD, PhD,<sup>1</sup>

<sup>1</sup>Department of Pathology, Chonnam National University Medical School, Gwangju, South Korea.



**\*Corresponding author:**

Yoo-Duk Choi, MD., PhD  
Department of Pathology,  
Chonnam National University  
Medical School, Gwangju,  
South Korea.

drydchoi@jnu.ac.kr

Received: 15 June 2020

Accepted: 08 May 2022

Published: 04 September 2023

**DOI**

10.25259/Cytojournal\_40\_2020

**Quick Response Code:**



## ABSTRACT

**Objectives:** As a convenient and economical method of screening cervical cancer and precancerous pathologies, the Papanicolaou smear (Pap smear) has been most widely used. Nevertheless, it requires cytological changes for making diagnoses and reportedly has a high false-negative rate. In this study, the usefulness of the human papillomavirus (HPV) DNA chip test as a complementary method that can compensate for the defect of the Pap smear was investigated.

**Material and Methods:** Of the 6516 patients who simultaneously underwent a Pap smear and an HPV DNA chip test at Chonnam National University Hospital between January 2015 and December 2016, 1897, an initial PAP smear-negative patients who had undergone an additional Pap smear during their 2-year follow-up period were selected for this study. Of the subject patients, 281 underwent a cervical biopsy.

**Results:** The Pap smear follow-up of an initial Pap smear-negative subjects showed 53 (75.7%) HPV high-risk positive cases in the cytology low-grade lesion group (70 cases) and 46 (97.8%) HPV high-risk positive cases in the cytology high-grade lesion group (47 cases). The 281 biopsy cases included 67 biopsy low-grade lesion cases and 74 biopsy high-grade lesion cases, of which there were 45 (67.2%) and 67 (90.5%) HPV high-risk positive cases, respectively. The follow-up cytology on the high-risk HPV-positive subjects showed that the ratio of their high-grade lesions was 260.8 times greater than that of the high-risk HPV-negative subjects (OR = 260.8 and 95% CI: 36.1 and 1886.1); and their biopsy showed that the ratio of their high-grade lesions was 102.7 times greater than that of the HPV-negative subjects (OR = 102.7 and 95% CI: 14.0 and 753.3).

**Conclusion:** The complementary use of the HPV DNA chip test may be useful in increasing the accuracy of screening examinations for the early diagnosis of uterine cervix cancer when combined with the Pap smear.

**Keywords:** Biopsy, Cervix uteri, Human papillomavirus, Papanicolaou test

## INTRODUCTION

Cervical cancer course begins with dysplasia of a precancerous lesion, followed by carcinoma *in situ* and invasive carcinoma, which lasts more than 15 years.<sup>[1]</sup> Therefore, unlike other malignant tumors, cervical cancer can be diagnosed early due to its precancerous lesions and its development into invasive carcinoma can be prevented.<sup>[2]</sup>

A Pap smear is the most widely used method of screening cervical cancer and precancerous lesions early.<sup>[3]</sup> In particular, it can be used to detect the positive lesions in the area surrounding the cervical cancer. Despite these advantages, a Pap smear requires a limitation for its diagnosis,

and it has low sensitivity and a high false-negative rate. These problems are mostly caused by errors in the specimen collection, slide preparation, and reading.<sup>[4,5]</sup>

Since the high-risk human papillomavirus (HPV) has been confirmed as one of the independent and most important causative agents of cervical lesions, the International HPV Society reported that in Pap smear-negative and non-HPV-infected women, cervical diseases did not develop for 3 years. The society also suggested that the HPV test is a useful screening test for cervical cancer.<sup>[6,7]</sup>

In this study, the usefulness of the HPV test as a complementary method to a Pap smear in the screening of cervical cancer was investigated, targeting subjects who underwent a Pap smear and an HPV test simultaneously.

## MATERIAL AND METHODS

### Study subjects

Of the 6516 patients who simultaneously underwent a Pap smear and a HPV DNA chip test at Chonnam National University Hospital between January 2015 and December 2016, 2801 patients with positive cytology result were excluded from the study. Of remaining 3715 cases, 1779 patients without an additional cytology during follow-up period were also excluded from the study. One thousand nine hundred and thirty-six Pap smear-negative patients who had undergone an additional Pap smear during their follow-up period were included for this study. To make the investigation unambiguous, 39 cases of uncertain cytological findings such as atypical squamous cells of undetermined significance and atypical glandular cells of undetermined significance in the follow-up results were excluded from this study, and finally, 1897 cases were selected for this study. Among them, 281 subjects underwent a cervical biopsy during their follow-up period. The follow-up period was conducted over 6–24 months [Figure 1]. This study was approved by the Institutional Review Board of our hospital (CNUH 2016-311).

To compare the results of the cytology and biopsy and to investigate the HPV-positive rate and the distribution of the HPV subtypes, the following classification was used: “Pap normal group” for cases of normal and inflammation findings in the follow-up cytology; “Pap low-grade lesion group” for cases of low-grade squamous intraepithelial lesion in the follow-up cytology; “Pap high-grade lesion group” for cases of high-grade squamous intraepithelial lesion, adenocarcinoma *in situ* (AIS), and invasive carcinoma in the follow-up cytology; “biopsy normal group” for cases of normal and cervicitis findings in the follow-up biopsy; “biopsy low-grade lesion group” for cases of cervical squamous intraepithelial lesion (CIN) 1 in the follow-up biopsy; and “biopsy high-grade lesion group” for cases of CIN 2, CIN 3, AIS, invasive squamous cell carcinoma, and invasive adenocarcinoma in the follow-up biopsy.

## Methods

### Pap smear

Using a cervical brush, cells were collected from the transformation zone of cervix, and they were fixed in a PreservCyt solution bottle. Then, slides were prepared using the ThinPrep 2000 system. The prepared slides were smeared in 20 mm diameter circles before Papanicolaou staining was conducted. The 2014 Bethesda System was used for the cytologic reading.

### Cervical biopsy

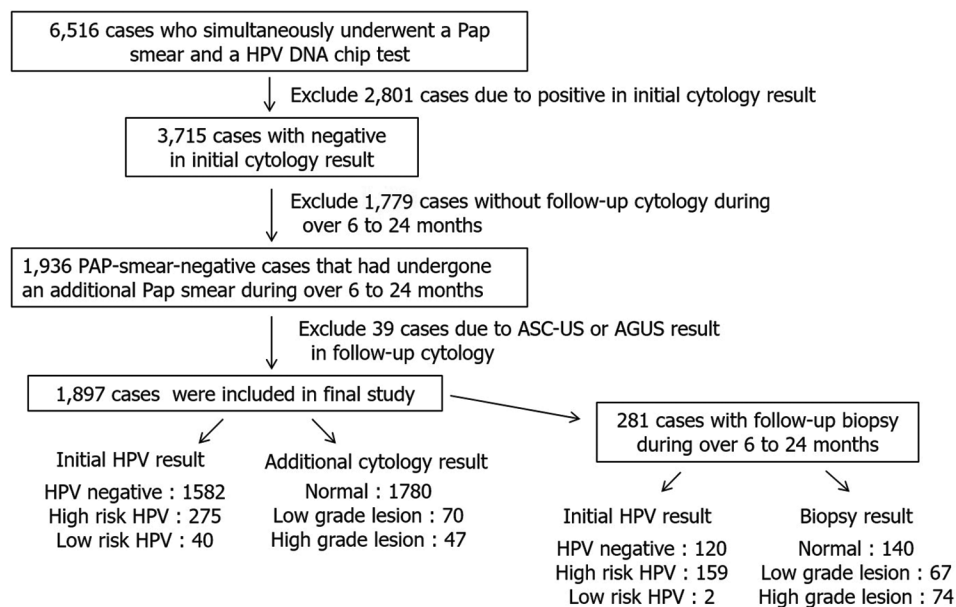
A pathologist received the biopsy specimen and cut it into appropriately sized pieces while it was still fresh. Then, the specimen was fixed using a 10% formalin solution. Hematoxylin and eosin staining is representative methods of preparing tissues specimens.

### HPV DNA chip test

Using a sterilized brush for cell collection, the exfoliated cells were collected from the cervical membrane, fixed in a vessel that contained a buffer solution, and washed twice using a 10-time diluted washer solution that was included in the MyGene HPV DNA chip. After the supernatant was removed, 200 µl of a buffer solution for DNA extraction was added to the cells, their reaction was allowed for more than 3 h in a 50°C water bath and the solution was boiled at 100°C in a heating block for 20 min and then centrifuged at 14,000 rpm for 10 min to allow the use of the supernatant as a DNA.

Polymerase chain reaction (PCR) is a nested PCR. Using MY09/MY11 primer (5'-GCM CAG GGW CAT AAY AAT GG-3' 5'-CGT CCM ARR GGA WAC TGA TC-3'), the L1 region that was an HPV target DNA was amplified, and then, the L1 region was amplified one more time using GP5+/GP6+ primer (5'-TTT GTT ACT GTG GTA GAT ACT AC-3', 5'-Cy5-GAA AAA TAA ACT GTA AAT CAT ATT C-3') that was attached with fluorescent materials. As a DNA control factor, β-globin primer (5'-GGT TGG CCA ATC TAC TCC CAG G-3', 5'-TGG TCT CCT TAA ACC TGT CTT G-3') was used for the first PCR amplification. The 25 µl DNA recombinant composition for the first amplification of each specimen included: 7.0 µl each of Premix I and Premix III, which were included in 12.7 µl of the third distilled water and the kit; 0.3 µl of Taq polymerase; and 5.0 µl of DNA. The reaction was performed at 50°C for 3 min for one cycle, at 95°C for 30 s, at 55°C for 30 s, at 72°C for 30 s for 35 cycles, and at 72°C for 3 min for one cycle, and then finished at 4°C.

The 25 µl DNA recombinant composition for the second amplification of each specimen included: 16.5 µl of the third distilled water; 6.5 µl of Premix II, which was included in the kit; 0.3 µl of Taq polymerase; and 2.0 µl of the first DNA. The



**Figure 1:** Flowchart of the study group. PAP, Papanicolaou smear; HPV, human papillomavirus; ASC-US, atypical squamous cells of undetermined significance; AGUS, atypical glandular cells of undetermined significance.

reaction was performed at 95°C for 5 min for one cycle, at 95°C for 30 s, at 50°C for 40 s, at 72°C for 30 s for 20 cycles, and at 72°C for 3 min for one cycle, and then finished at 4°C.

After the DNA amplifications were completed, 10 µl of DNA was denatured at 95°C for 5 min; mixed with the 30 µl buffer solution that was heated at 43°C; and divided into the holes of the high integration HPV DNA chip microarray to which were attached the oligonucleotide probes that were specific to the 24 subtypes of the HPV genotype in appropriate concentrations. Then, a hybridization reaction was performed in a dark, moist box at 43°C for 1 h. The remaining amplified DNA was mixed with 2.5% agarose gel and 5 µl of bromophenol blue and divided into the holes with a TBE buffer (×0.5), after which a 100 bp DNA-sized marker was divided before electrophoresis was conducted at 150 V for 15 min. After the electrophoresis was completed, the DNA of the agarose was stained with 0.5 µg/ml of ethidium bromide, and the DNA band was observed under UV. In the HPV-positive case at the first PCR reaction, the DNA band was observed at 450 bp; and at the second PCR reaction, at 150 bp. In terms of β-globin, the DNA band was observed at 250 bp.

After the hybridization reaction was completed, the DNA chip slides were washed twice for 5 min each in a horizontal shaker at 300 rpm using washer buffer Solution I (2 × SSC, 0.1% SDS), twice for 5 min each using washer buffer Solution II (0.2 × SSC), and once for 5 min using washer buffer Solution III (0.1 × SSC). Then, the washer solution was removed and the slides were analyzed with a microarray scanner to confirm the presence of 20 HPV

genotypes according to two subtypes: The high-risk and low-risk groups. Types 6, 11, 40, 43, 54, and 70 were classified under the low-risk group, and Types 16, 18, 31, 33, 35, 39, 45, 51, 52, 53, 56, 58, 66, and 68 under the high-risk group.

### Statistical analysis

Based on the results of the biopsy and Pap smear after the follow-up, the resulting infections and subtypes that were obtained from the initial HPV DNA chip test were compared. The HPV results of the DNA chip test, biopsy, and cytology were analyzed using a Chi-square test. In the HPV-positive subjects, regarding the risk of developing high-risk lesions, the odds ratio and the 95% confidence interval were calculated based on the low-risk lesions. For the statistical processing, IBM SPSS Statistics 24.0 was used. Statistical significance was set at  $P < 0.05$ .

## RESULTS

### Pap smear results after the follow-up

The number of “Pap normal group” was 1780 (93.8%); with Pap low-grade lesion group, 70 (3.7%); and with Pap high-grade lesion group, 47 (2.5%). The sensitivity of the HPV DNA test for Pap high-grade lesion group was 97.9% and its specificity was 87.6%, positive predictive value (PPV) was 16.7%, and negative predictive value (NPV) was 99.9%. According to the results of the follow-up cytology on the high-risk HPV-positive subjects, the ratio of their high-grade

lesions was 260.8 times greater than that of the high-risk HPV-negative subjects [Table 1].

### Biopsy results after the follow-up

Of the 281 subjects who underwent a biopsy, 140 (49.8%) were diagnosed as normal and inflammation (biopsy normal group), of which 67 (23.8%) were biopsy low-grade lesion group and 74 (26.3%) biopsy high-grade lesion group. The sensitivity of the HPV DNA test for biopsy high-grade lesion group was 98.6% and its specificity was 58.5%, PPV was 45.9%, and NPV was 99.2%. The results of the biopsy follow-up confirmed that the high-risk HPV-positive subjects were had 102.7 times greater high-risk lesions than the high-risk HPV-negative subjects [Table 2].

### HPV infection rate and subtype distribution

Of the 1897 subjects who underwent an initial Pap smear and an HPV DNA chip test, 1582 (83.3%) had HPV-negative results and 317 (16.7%) had HPV-positive results. Of the 317 HPV-positive subjects, 275 (64.7% or 14.5% of the 1897

subjects) were high-risk HPV-positive, 42 were low-risk HPV positive. Of the 275 high-risk HPV-positive cases, 212 had an individual infection and 63 had multiple infections. Of the 63 multiple infection subjects, 35 were observed to have had two high-risk subtypes; three had three high-risk subtypes; and one had four high-risk subtypes; and 24 had high- and low-risk subtypes. Total sum of all high-risk HPVs in individual or multiple infection was 319. Of all the subtypes that caused multiple infections, the most common high-risk subtypes were HPV-16 (73/319, 22.9%), HPV-58 (47/319, 14.7%), HPV-53 (43/319, 13.4%), HPV-18 (34/319, 10.6%), HPV-31 (29/319, 9.1%), HPV-66 (18/319, 5.6%), HPV-56 (17/319, 5.3%), and HPV-33 (14/319, 4.4%), in that order. The remaining 40 individual infections were caused by the low-risk subtype and the most common subtype was HPV-70 (24/40, 60.0%), followed by HPV-54 (13/40, 32.5%), HPV-6 (3/40, 7.5%), and HPV-40 (2/40, 5.0%).

### High-risk HPV-positive rate and subtype distribution according to the results of the follow-up cytology and biopsy

#### High-risk HPV-positive rate and high-risk HPV subtype distribution according to the results of the follow-up cytology

Of the 1780 Pap normal group, 176 (9.9%) were high-risk HPV positive; of the 70 Pap low-grade lesion group, 53 (75.7%); and of the 47 Pap high-grade lesion group, 46 (97.9%). The Pap low-grade lesion group showed a higher high-risk HPV-positive rate ( $P < 0.001$ ) than the Pap normal group, and the Pap high-grade lesion group showed a significantly higher high-risk HPV-positive rate than the Pap low-grade lesion group ( $P = 0.002$ ) [Table 3].

In all the groups, the most common high-risk HPV subtype was HPV 16, which was observed in 35 subjects (2.0% or 20.6% of the 170 high-risk HPV-positive subjects) of the 1780 Pap normal group subjects, 14 (20.0% or 26.4% of the 60 high-risk HPV-positive subjects) of the 70 Pap low-grade lesion subjects, and 24 (51.1% or 52.1% of the 46 HPV-positive subjects) of the 47 Pap high-risk lesion subjects. In the PAP high-grade lesion group, HPV 16 was significantly more frequently observed than the other high-risk HPV subtypes ( $P = 0.004$ ). However, HPV 53 was less frequently observed than other high-risk HPV subtypes in the PAP high-grade lesion group ( $P = 0.004$ ) [Table 4].

#### High-risk HPV-positive rate and high-risk HPV subtype distribution according to the results of the follow-up biopsy

Of the 281 biopsy subjects, 159 (56.6%) were high-risk HPV positive; of the 140 biopsy normal subjects, 31 (22.1%); of the 67 biopsy low-grade lesion group, 55 (82.1%); and of the 74 biopsy high-grade lesion group, 73 (98.6%). The biopsy

**Table 1:** Comparison of the follow-up Pap smear and the HPV DNA chip test.

Follow-up Pap/ high-risk HPV	Normal	Positive		OR (95% CI)
		Low-grade lesion	High-grade lesions	
Negative	1604	17	1	260.8 (36.1–1.886.1)
Positive	176	53	46	260.8 (36.1–1.886.1)
Total	1780	70	47	

Pap: Papanicolaou smear, HPV: Human papillomavirus, OR: Odds ratio, CI: Confidence interval

**Table 2:** Comparison of the follow-up biopsy and the HPV DNA chip test.

Follow-up biopsy/ high-risk HPV	Normal	Positive		OR (95% CI)
		Low-grade lesion	High-grade lesion	
Negative	109	12	1	102.7 (14.0–753.3)
Positive	31	55	73	102.7 (14.0–753.3)
Total	140	67	74	

HPV: Human papillomavirus, OR: Odds ratio, CI: Confidence interval

**Table 3:** Prevalence of high-risk HPV in the high-grade lesion group.

Pap	Positive cases/total (%)	Biopsy	Positive cases/total (%)
Pap normal	176/1780 (9.9)	Biopsy normal	31/140 (22.1)
Pap low-grade lesion	53/70 (75.7)	Biopsy low-grade lesion	55/67 (82.1)
Pap high-grade lesion	46/47 (97.9)	Biopsy high-grade lesion	73/74 (98.6)
Total	275/1897 (14.5)	Total	159/281 (56.6)

PAP: Papanicolaou smear

low-grade lesion group showed a higher high-risk HPV-positive rate than the biopsy normal group ( $P < 0.001$ ) and a significantly lower high-risk HPV-positive rate than the biopsy high-grade lesion group ( $P = 0.001$ ) [Table 3]. The most common HPV subtype in the biopsy high-grade lesion group was also HPV-16 [27 of the 74 (36.5%) or 37.0% of the 73 HPV-positive subjects], which showed a significantly higher frequency than the other subtypes ( $P = 0.023$ ). However, HPV 53 was less frequently observed than other high-risk HPV subtypes in the biopsy high-grade lesion group ( $P = 0.004$ ) [Table 5].

## DISCUSSION

Since cervical cancer develops from a precancerous lesion to invasive carcinoma over several decades, its early diagnosis through screening tests is important to reduce its incidence. Despite efforts to prevent cervical cancer, it is still the common type of female cancer in the world.<sup>[8]</sup>

The Pap smear has been used over the past several decades as a method of screening cervical cancer.<sup>[3]</sup> With it, the incidence and morbidity of invasive cervical cancer have consistently decreased. However, the Pap smear still has the drawbacks of low sensitivity and a high false-negative rate.<sup>[9,10]</sup> In this study, the normal Pap smear patients additionally underwent HPV tests, follow-up cytology, or biopsy to compare their results and to confirm if the HPV test could compensate for the defects of the Pap smear.

According to the HPV test results, 317 (16.7%) of the 1897 subjects were HPV positive. According to the results of the follow-up Pap smear, 176 (9.9%) of the 1780 normal group subjects, 53 (75.7%) of the 70 low-grade lesion group subjects, and 46 (97.9%) of the 47 high-grade lesion group subjects had positive results in the initial HPV test. These figures imply that the initial Pap smear results had a high false-negative rate and the HPV test was useful as a complementary method for the Pap smear.

In the previous studies, HPV was observed in the cervixes of a significant number of females who had a sex life.<sup>[11,12]</sup> However, low-risk HPV is a transient infection, so it usually disappears with the passing of time.<sup>[13]</sup> In the case of high-

**Table 4:** Distribution of the HPV high-risk genotypes by HPV DNA chip according to the cervical cytology.

HPV genotype	Number of patients (% in positive cases)			
	Total	Pap normal and LSIL	Pap high-grade lesions	P-value
16	73	49 (22.6)	24 (41.4)	0.004
Non-16	202	168 (77.4)	34 (58.6)	0.004
58	47	38 (17.5)	9 (15.5)	0.720
Non-58	228	179 (82.5)	49 (84.5)	0.720
53	43	41 (18.9)	2 (3.4)	0.004
Non-53	232	176 (81.1)	56 (96.6)	0.004
18	34	26 (12.0)	8 (13.8)	0.710
Non-18	241	191 (88.0)	50 (86.2)	0.710
31	29	20 (9.2)	9 (15.5)	0.165
Non-31	246	197 (80.8)	49 (84.5)	0.165

PAP: Papanicolaou smear, LSIL: Low-grade squamous intraepithelial lesion, HPV: Human papillomavirus

**Table 5:** Distribution of the HPV high-risk genotypes by HPV DNA chip according to the biopsy.

HPV genotype	Number of patients (% in the positive cases)			
	Total	Biopsy normal and LSIL	Biopsy high-grade lesions	P-value
16	44	17 (19.8)	27 (37.0)	0.023
Non-16	115	69 (80.2)	46 (63.0)	0.023
58	22	13 (15.1)	9 (12.3)	0.521
Non-58	137	73 (84.9)	64 (87.7)	0.521
53	15	14 (16.3)	1 (1.4)	0.001
Non-53	144	72 (83.7)	72 (98.6)	0.001
18	20	10 (11.6)	10 (13.7)	0.785
Non-18	139	76 (88.4)	63 (86.3)	0.785
31	16	7 (8.0)	9 (12.3)	0.441
Non-31	143	79 (92.0)	64 (87.7)	0.441

LSIL: Low-grade squamous intraepithelial lesion, HPV: Human papillomavirus

risk HPV, which is associated with cancer, the infection is persistent, and the resulting gradual cytological changes sometimes lead to cervical cancer.<sup>[13-16]</sup> According to multiple epidemiological investigations, the presence of high-risk HPV DNA in the cervical tissues is highly associated with cervical cancer, so high-risk HPV infection can be a prognostic factor of cancer.<sup>[11,17]</sup>

In this study, when the results of the follow-up Pap smear and biopsy were closer to those of the high-grade lesions, the positive rate of the high-risk group HPV increased. This result coincided with that of other studies.<sup>[18]</sup> The distribution of the HPV subtype changed according to the cervical lesion.<sup>[19]</sup> In this study, the HPV 16-positive rates of the Pap smear and biopsy significantly increased when the grade of the lesion increased from low to high grade, unlike with the other subtypes.

The sensitivity of the HPV DNA test for the subjects who underwent the follow-up Pap smear was 97.9%, and its PPV was comparatively very low at 16.7%. This was because they were cured already. In comparison, the sensitivity of the HPV DNA test for the subjects who underwent a biopsy was 90.8%, and their positive predictive rate was 80.5%. This might have been because not all the subjects underwent a biopsy, but only the selected subjects. In addition, their individual characteristics such as their marital status, occupation, health behavior, and sexual behavior were not considered. In this study, 141 subjects (7.4%) who were confirmed normal in its initial cytology were later confirmed to have had low- and high-grade lesions in the follow-up biopsy; and 128 of them (90.7%) were high-risk HPV positive. In the case of the high-risk HPV-positive subjects, their high-grade lesion rate in the follow-up cytology was 260 times greater than that of the high-risk HPV-negative subjects; and their high-grade lesion rate in the biopsy, 102 times greater. These mean that the high-risk HPV test showed a high predictive rate for high-grade lesions. Moreover, although the cytology result was normal, a follow-up should be performed if a subject had been exposed to the high-risk HPV group.

Considering the results of this study, the specificity of HPV testing is lower, so depending on the management protocol that is used, there may be more unnecessary biopsies, not less, although this may be a reasonable trade-off for the greater sensitivity of the HPV test. The use of the HPV DNA test as a complementary test to the Pap smear has additional costs.<sup>[20]</sup> When only cytology is conducted as a screening test for cervical cancer, a significant number of high-grade lesions may be overlooked due to the high false-negative rate. When the HPV DNA test is conducted as a complementary method of high-risk HPV detection, fast and appropriate treatments may be available, and accordingly, the incidence of cervical cancer may decrease.

## CONCLUSION

The HPV test was confirmed as useful complementary method for diagnosing high-grade cervical lesions. When the HPV test is combined with the Pap smear, the false-negative rate of the Pap smear is expected to decrease.

## COMPETING INTEREST STATEMENT BY ALL AUTHORS

The authors declare that they have no competing interest.

## AUTHORSHIP STATEMENT BY ALL AUTHORS

Sung-Sun Kim: Contributions to design  
Joo-Yeon Koo, Nah-Ihm Kim: Acquisition of data  
Rae-Young Lee, Jong-Hee Nam: Drafting the article and revising it critically for important intellectual content  
Yoo-Duk Choi: Analysis and interpretation of data and final approval of the version.

## ETHICS STATEMENT BY ALL AUTHORS

This study was conducted with approval from Institutional Review Board (IRB) (CNUH 2016-311).

## LIST OF ABBREVIATIONS (IN ALPHABETIC ORDER)

AGUS – Atypical glandular cells of undetermined significance  
AIS – Adenocarcinoma in situ  
ASCUS – Atypical squamous cells of undetermined significance  
CIN – Cervical squamous intraepithelial lesion  
DNA – Deoxyribonucleic acid  
HPV – Human papillomavirus  
HSIL – High grade squamous intraepithelial lesion  
LSIL – Low grade squamous intraepithelial lesion  
NPV – Negative predictive value  
Pap – Papanicolau smear  
PPV – Positive predictive value  
TBS – The Bethesda System.

## EDITORIAL/PEER-REVIEW STATEMENT

To ensure the integrity and highest quality of CytoJournal publications, the review process of this manuscript was conducted under a **double-blind model** (the authors are blinded for reviewers and vice versa) through automatic online system.

## REFERENCES

1. Bosch FX, de Sanjosé S. Chapter 1: Human papillomavirus and cervical cancer-burden and assessment of causality. *J Natl*

- Cancer Inst Monogr 2003;31:3-13.
2. Ferlay J, Shin HR, Bray F, Forman D, Mathers C, Parkin DM. Estimates of worldwide burden of cancer in 2008: GLOBOCAN 2008. *Int J Cancer* 2010;127:2893-917.
  3. Koss LG. The Papanicolaou test for cervical cancer detection. A triumph and a tragedy. *JAMA* 1989;261:737-43.
  4. Soost HJ, Lange HJ, Lehmacher W, Ruffing-Kullmann B. The validation of cervical cytology. Sensitivity, specificity and predictive values. *Acta Cytol* 1991;35:8-14.
  5. Cuzick J, Sasieni P, Davies P, Adams J, Normand C, Frater A, *et al.* A systematic review of the role of human papilloma virus (HPV) testing within a cervical screening programme: Summary and conclusions. *Br J Cancer* 2000;83:561-5.
  6. Smith RA, Cokkinides V, Brooks D, Saslow D, Shah M, Brawley OW. Cancer screening in the United States, 2011: A review of current American Cancer Society guidelines and issues in cancer screening. *CA Cancer J Clin* 2011;61:8-30.
  7. Wright TC Jr., Schiffman M, Solomon D, Cox JT, Garcia F, Goldie S, *et al.* Interim guidance for the use of human papillomavirus DNA testing as an adjunct to cervical cytology for screening. *Obstet Gynecol* 2004;103:304-9.
  8. Khazaei Z, Sohrabivafa M, Mansori K, Neemi H, Goodarzi E. Incidence and mortality of cervix cancer and their relationship with the human development index in 185 countries in the world: An ecology study in 2018. *Adv Hum Biol* 2019;9:222-7.
  9. Coppleson LW, Brown B. Estimation of the screening error rate from the observed detection rates in repeated cervical cytology. *Am J Obstet Gynecol* 1974;119:953-8.
  10. Fetherston WC. False-negative cytology in invasive cancer of the cervix. *Clin Obstet Gynecol* 1983;26:929-37.
  11. Bosch FX, Lorincz A, Muñoz N, Meijer CJ, Shah KV. The causal relation between human papillomavirus and cervical cancer. *J Clin Pathol* 2002;55:244-65.
  12. Cogliano V, Baan R, Straif K, Grosse Y, Secretan B, El Ghissassi F, *et al.* Carcinogenicity of human papillomaviruses. *Lancet Oncol* 2005;6:204.
  13. Sherman ME, Lorincz AT, Scott DR, Wacholder S, Castle PE, Glass AG, *et al.* Baseline cytology, human papillomavirus testing, and risk for cervical neoplasia: A 10-year cohort analysis. *J Natl Cancer Inst* 2003;95:46-52.
  14. McLachlin CM. Human papillomavirus in cervical neoplasia. Role, risk factors, and implications. *Clin Lab Med* 2000;20:257-70.
  15. Kjaer S, Høgdall E, Frederiksen K, Munk C, van den Brule A, Svare E, *et al.* The absolute risk of cervical abnormalities in high-risk human papillomavirus-positive, cytologically normal women over a 10-year period. *Cancer Res* 2006;66:10630-6.
  16. Khan MJ, Castle PE, Lorincz AT, Wacholder S, Sherman M, Scott DR, *et al.* The elevated 10-year risk of cervical precancer and cancer in women with human papillomavirus (HPV) type 16 or 18 and the possible utility of type-specific HPV testing in clinical practice. *J Natl Cancer Inst* 2005;97:1072-9.
  17. Chua KL, Hjerpe A. Human papillomavirus analysis as a prognostic marker following conization of the cervix uteri. *Gynecol Oncol* 1997;66:108-13.
  18. Ronco G, Giorgi-Rossi P, Carozzi F, Confortini M, Dalla Palma P, Del Mistro A, *et al.* Efficacy of human papillomavirus testing for the detection of invasive cervical cancers and cervical intraepithelial neoplasia: A randomised controlled trial. *Lancet Oncol* 2010;11:249-57.
  19. de Sanjosé S, Diaz M, Castellsagué X, Clifford G, Bruni L, Muñoz N, *et al.* Worldwide prevalence and genotype distribution of cervical human papillomavirus DNA in women with normal cytology: A meta-analysis. *Lancet Infect Dis* 2007;7:453-9.
  20. Naucler P, Ryd W, Törnberg S, Strand A, Wadell G, Elfgren K, *et al.* Human papillomavirus and Papanicolaou tests to screen for cervical cancer. *N Engl J Med* 2007;357:1589-97.

**How to cite this article:** Lee R, Koo J, Kim N, Kim S, Nam J, Choi Y. Usefulness of the human papillomavirus DNA chip test as a complementary method for cervical cytology. *CytoJournal* 2023;20:34.

**The FIRST Open Access cytopathology journal**  
 Publish in *CytoJournal* and **RETAIN** your *copyright* for your intellectual property  
**Become Cytopathology Foundation Member** to get all the benefits  
 Annual membership fee is nominal US \$ 50 (US \$ 1000 for life)  
**In case of economic hardship it is free**  
**For details visit <https://cytojournal.com/cf-member>**

**PubMed indexed**  
**FREE world wide open access**  
**Online processing** with rapid turnaround time.  
**Real time dissemination** of time-sensitive technology.  
 Publishes as many **colored high-resolution images**  
 Read it, cite it, bookmark it, use RSS feed, & many----

**CYTOJOURNAL**  
**[www.cytojournal.com](http://www.cytojournal.com)**  
 Peer-reviewed academic cytopathology journal





# NextGen CelBloking™ Kits

**Frustrated with your cell blocks?  
We have a better solution!**

**Nano**

## Nano NextGen CelBloking™

Cell block kit to process single scattered cell specimens and tissue fragments of **any** cellularity.



**PATENT PENDING**



**Pack #1**



**Pack #2**


**Micro**

## Micro NextGen CelBloking™

For cellular specimens (more than 1 ml concentrated specimen with Tissuecrit more than 50%)



**PATENT PENDING**



**Pack #2**