

Commentary

Open Access

## Aspergillosis with pulmonary echinococcosis

Nalini Gupta\*<sup>1</sup>, Julie Arora<sup>2</sup>, Raje Nijhawan<sup>3</sup>, Ritesh Aggarwal<sup>4</sup> and Anupam Lal<sup>5</sup>

Address: <sup>1</sup>Assistant Professor, Department of Cytopathology, Postgraduate Institute of Medical Education and Research, Chandigarh, INDIA, <sup>2</sup>Senior Resident, Department of Radiodiagnosis, Postgraduate Institute of Medical Education and Research, Chandigarh, INDIA, <sup>3</sup>Additional Professor, Department of Cytopathology, Postgraduate Institute of Medical Education and Research, Chandigarh, INDIA, <sup>4</sup>Assistant Professor, Department of Pulmonary Medicine Postgraduate Institute of Medical Education and Research, Chandigarh, INDIA and <sup>5</sup>Associate Professor, Department of Radiodiagnosis, Postgraduate Institute of Medical Education and Research, Chandigarh, INDIA

Email: Nalini Gupta\* - nalini203@rediffmail.com; Julie Arora - julie12@yahoo.com; Raje Nijhawan - rajenijhawan@hotmail.com; Ritesh Aggarwal - ritesh3@yahoo.co.in; Anupam Lal - anupamlal@yahoo.com

\* Corresponding author

Published: 30 March 2006

Received: 01 April 2005

CytoJournal2006, 3:7 doi:10.1186/1742-6413-3-7

Accepted: 30 March 2006

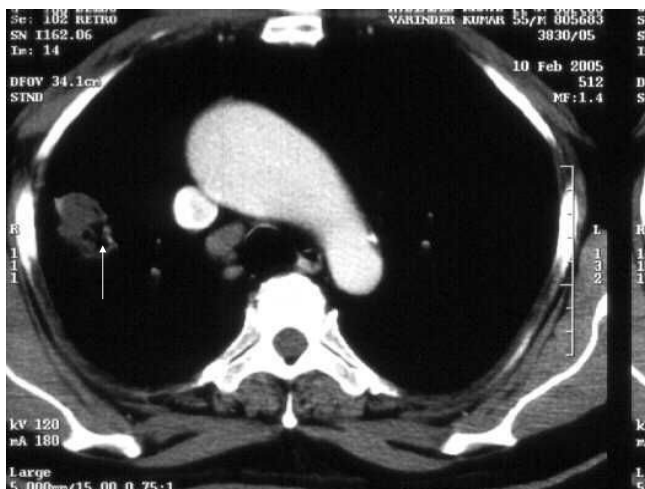
This article is available from: <http://www.cytojournal.com/content/3/1/7>

© 2006 Gupta et al; licensee BioMed Central Ltd.

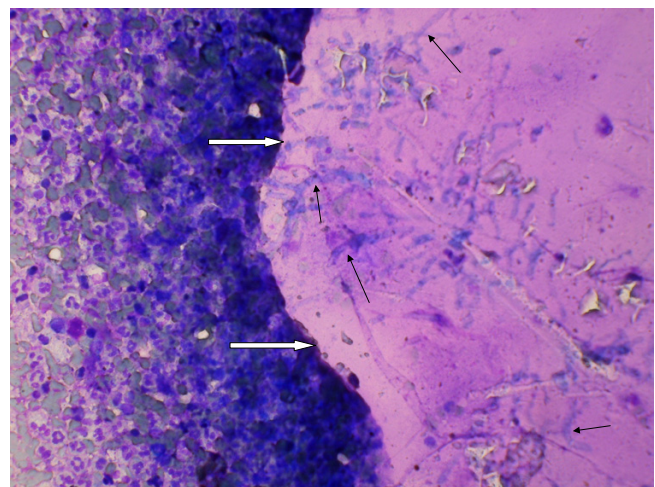
This is an Open Access article distributed under the terms of the Creative Commons Attribution License (<http://creativecommons.org/licenses/by/2.0>), which permits unrestricted use, distribution, and reproduction in any medium, provided the original work is properly cited.

Pulmonary echinococcal hydatid cysts have been reported coexistent with cryptococcosis and other saprophytic mycosis on histopathological examination of the affected lung tissues [1-3]. Similar findings have not been reported in Fine needle aspiration (FNA) samples. The authors describe a similar case diagnosed on FNA material.

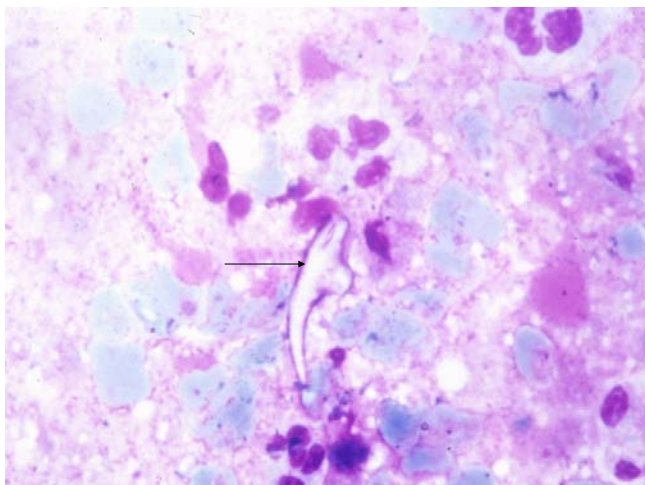
A 53-year-old male, known diabetic for the last five years, presented with history of cough and fever with occasional haemoptysis for the last three months. A chest X-ray showed an oval homogeneous density in the upper lobe of right lung. Results of laboratory investigations such as haemogram, routine urine and stool examinations and sputum examination did not reveal any abnormality. He



**Figure 1**  
CT scan showing a solitary pulmonary nodule (arrow) with focal areas of cavitation and spiculated margins in right lung.



**Figure 2**  
Microphotograph showing septate branching fungal hyphae (black arrows) embedded on the laminated ectocyst of echinococcus (Thick white arrows) (MGG × 512).



**Figure 3**  
Microphotograph showing a hooklet of hydatid (arrow)  
(MGG  $\times$  1375).

was non-reactive for Human Immunodeficiency Virus (HIV). Computed Tomography (CT) scan showed a solitary pulmonary nodule measuring about  $2.5 \times 2 \times 1$  cm with focal areas of cavitation and spiculated margins in right lung (Figure 1). CT guided fine needle aspiration (FNA) was performed from this solitary pulmonary nodule. The material aspirated was blood mixed pus like material. The smears were cellular and composed of sheets of polymorphs and histiocytes. There were scattered fragments of acellular homogenous laminated membranous structures representing laminated ectocyst of echinococcus. Also fungal hyphae, which were of uniform width, septate and branching morphologically consistent with Aspergillus were identified. These hyphae were seen embedded on the laminated ectocyst (Figure 2). The smears also showed many scattered hooklets of hydatid (Figure 3) along with few multinucleated giant cells. Therefore, he was diagnosed to have concurrent Aspergillus with pulmonary Echinococcosis by CT guided FNA from pulmonary nodule. The fungal culture of the aspirated material was not done in the present case.

Coexistence of fungi with pulmonary echinococcal hydatid cysts has occasionally been reported in the English literature, but similar findings have not been reported in FNA samples. The fungus in these cases can invade the outer aspect of the laminated membrane and can grow in the cavity of the pericyst. Coexistence of fungi with pulmonary hydatid cyst is seen more commonly in immunocompromised patients. In the present case, the patient was a known diabetic and was taking oral hypoglycemic drugs for the last five years. This case demonstrates (on FNA material) invasion of the laminated membrane (ectocyst) of hydatid by a fungus seen as hyphae branching dichoto-

mously at acute angles morphologically consistent with Aspergillus. The same has not been reported in the English literature previously. The aim of this communication is also to highlight the atypical clinical presentation, radiological findings and importance of CT guided FNA to arrive at an accurate diagnosis. The last point merits underscoring from the viewpoint of the immunocompromised patient, in whom, hydatid disease may coexist with other pathogens, such as fungi and these pathogens need to be accurately identified in radiologically guided FNA. It is also important to bear in mind that rarely, hydatid fluid can incite an anaphylactic reaction during the procedure. Adequate emergency measures should be available at hand to circumvent any untoward effects resulting from such a reaction.

### References

1. Dagleish AG: **Concurrent hydatid disease and Cryptococcosis in a 16-year-old girl.** *Medical Journal of Australia* 1981, **2**:144-5.
2. Kini U: **Invasive mycosis of a pulmonary hydatid cyst in a non-immunocompromised host.** *Journal of Tropical Medicine and Hygiene* 1995, **98**:404-6.
3. Date A, Zachariah N: **Saprophytic mycosis with pulmonary echinococcosis.** *Journal of Tropical Medicine and Hygiene* 1995, **98**:416-8.

Publish with **BioMed Central** and every scientist can read your work free of charge

"BioMed Central will be the most significant development for disseminating the results of biomedical research in our lifetime."

Sir Paul Nurse, Cancer Research UK

Your research papers will be:

- available free of charge to the entire biomedical community
- peer reviewed and published immediately upon acceptance
- cited in PubMed and archived on PubMed Central
- yours — you keep the copyright

Submit your manuscript here:  
[http://www.biomedcentral.com/info/publishing\\_adv.asp](http://www.biomedcentral.com/info/publishing_adv.asp)





# NextGen CelBloking™ Kits

**Frustrated with your cell blocks?  
We have a better solution!**

**Nano**

## Nano NextGen CelBloking™

Cell block kit to process single scattered cell specimens and tissue fragments of **any** cellularity.



**PATENT PENDING**



**Pack #1**



**Pack #2**

**Micro**

## Micro NextGen CelBloking™

For cellular specimens (more than 1 ml concentrated specimen with Tissuecrit more than 50%)



**PATENT PENDING**



**Pack #2**