

## Quiz Case

# Inguinal swelling in a young female: An unusual finding

Shruti Gupta, MD<sup>1</sup>, Priyanka Gautam, MD<sup>2</sup>, Pawan Kumar, MD<sup>1</sup>, Niraj Kumari, MD<sup>1</sup>

<sup>1</sup>Department of Pathology, AIIMS, Raebareli, <sup>2</sup>Department of Pathology, AIIMS, Gorkhpur, Uttar Pradesh, India.



A 21-year-old female presented with gradually increasing swelling over right inguinal region for the past 1 month. She denied any history of leg trauma, pain, or fever. On physical examination, a firm, non-tender nodular mass lesion measuring 1 × 0.5 × 0.5 cm was palpable over the right inguinal region. No other lymphadenopathy or nodular swelling was found elsewhere in the body. Fine needle aspiration was performed from the lesion, after informed consent of the patient and smears were prepared [Figures 1 and 2].

### \*Corresponding author:

Shruti Gupta,  
Department of Pathology,  
AIIMS, Raebareli,  
Uttar Pradesh, India.

[drshrutimlb@gmail.com](mailto:drshrutimlb@gmail.com)

Received: 03 February 2023

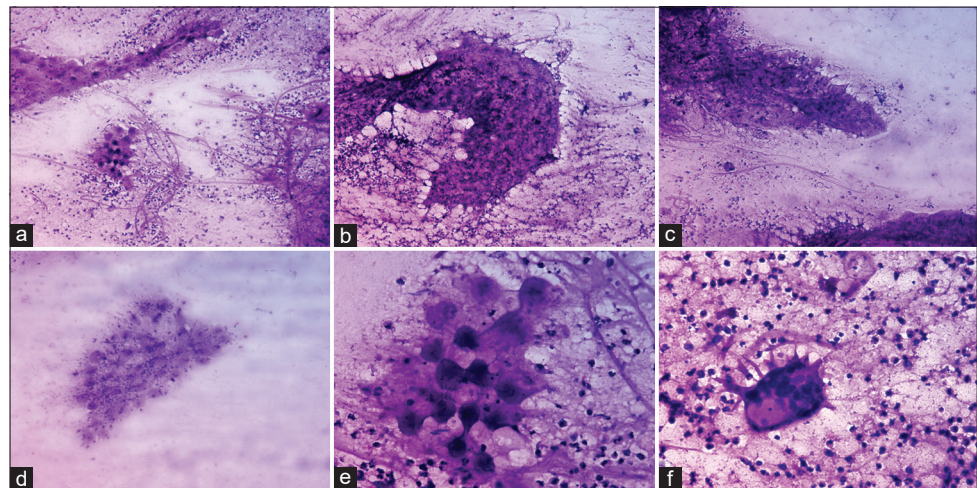
Accepted: 08 June 2023

Published: 01 September 2023

DOI

[10.25259/Cytojournal\\_10\\_2023](https://doi.org/10.25259/Cytojournal_10_2023)

Quick Response Code:



**Figure 1:** Microphotograph panel of smears from the right inguinal swelling are cellular and show (a) large fragments of bladder wall and (b and c) granular fibrillary sheath-like material in a background of histiocytes, scattered eosinophils, neutrophils. (d and e) rounded bladder wall fragments tiny dense pyknotic nuclei. (f) scattered multinucleated giant cell. (a: ×4, b-d: ×10, e and f: ×40) (H&E).

1. What is the interpretation based on the clinical history and findings of fine needle aspiration?
  - a. Hydatidosis
  - b. Cysticercosis
  - c. Spargana
  - d. Filariasis.

**ANSWER**

The correct cytological interpretation is b. Cysticercosis.

**EXPLANATION**

Aspirate was fluidy in this case and the smears showed large fragments of bladder wall identified as fibrillary bluish material woven into rounded multiple subcuticular cells with interspersed tiny blue pyknotic nuclei surrounded by dense inflammatory infiltrate. The background showed sheets of histiocytes, scattered eosinophils, neutrophils, and few multinucleated giant cells [Figures 1 and 2]. These features are characteristic of Cysticercosis. Cysticercosis is caused by larval stage of *Taenia solium*, while adult form causes Taeniasis.

The most common cytologic mimic of cysticercosis is other cestodes including hydatid cyst (*Echinococcus granulosus*), Coenuri and Spargana. The differentiation between these requires careful examination of the bladder wall and hooklets. The bladder wall is thin and membranous in cysticercosis while thick and lamellated in a hydatid cyst. The hooklets of cysticercosis are sized 130–170  $\mu$  while hydatid hooklets range between 22  $\mu$  and 44  $\mu$ .<sup>[1]</sup>

Filariasis (Option D) is another vector borne disease and shows microfilariae. Most common causative agents of human filariasis include *Wuchereria bancrofti*, *Brugia malayi*, *Brugia timori*, and *Loa loa*.

**ADDITIONAL QUIZ QUESTIONS****Q2. What is the mode of transmission of the disease?**

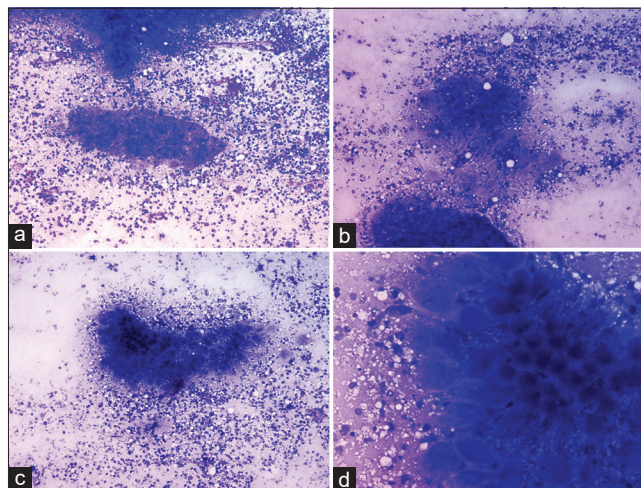
- Feco-oral contamination
- Droplet transmission
- Inhalation
- Sexual contact.

**Q3. All of the following statement are true for cysticercosis, except?**

- Cysticercosis is caused by larval stage of *T. solium*
- Humans cannot be both definitive and intermediate hosts
- Inflammatory response is usually associated with cysticercosis
- Viable cysticerci can persist for several months to years in humans.

**ANSWERS TO THE ADDITIONAL QUIZ QUESTIONS**

Answers: Q2-a, Q3-b.



**Figure 2:** Microphotograph panel of smears (a and b) showing large fragments of bladder wall in a background of dense inflammatory infiltrate (c and d) fibrillary bluish material woven into rounded multiple subcuticular cells with interspersed tiny blue pyknotic nuclei surrounded by dense inflammatory infiltrate. (a-c:  $\times 10$ , d:  $\times 40$ ) (MGG).

**EXPLANATION FOR ADDITIONAL QUIZ QUESTIONS**

The life-cycle of *T. solium* involves two hosts – the intermediate hosts which are most commonly pigs and harbor the larval stage, and the definitive host which are humans, sheltering the adult form. However, humans can become accidental intermediate hosts. The adults tapeworm enters the human body by eating the larval form present in the meat of the intermediate host.<sup>[2]</sup>

**BRIEF REVIEW OF THE TOPIC**

A myriad of parasitic infections continue to pose health issues in tropical climates. In endemic countries, like India, cysticercosis is a common infection. The WHO experts in 2014, ranked *T. solium* as food borne parasite of greatest global concern.<sup>[2]</sup> Cysticercosis can involve skin, subcutaneous tissue, muscles, intermuscular fascia, lymph nodes, brain, and various other organs.

Most subcutaneous cysticerci present as painless nodular or cystic swellings, that are easily amenable to fine needle aspiration. A definitive diagnosis of cysticercosis can be established by cytological examination and identification of the variable morphology in viable and degenerating/calcified lesions. Microscopically, viable cysts demonstrates fragments of the bladder wall of the larva identified as loose granular fibrillary material, often thrown into rounded wavy folds with small round dark subcuticular or tegumental cells with small pyknotic nuclei, refractile claw shaped hooklets, and scolices, while degenerating lesions can demonstrate scattered hooklets and calcareous corpuscles.<sup>[3,4]</sup> Background

consists of inflammatory infiltrate comprising of eosinophils, polymorphs, histiocytes, and giant cell reaction.

*Cysticercus cellulosae* can regulate T-Cell response and interacts with the host immune system by excreting and secreting antigens, thereby escaping the host immune attacks and establish a persistent infection.<sup>[5]</sup>

Serological tests and radiological investigations such as computed tomography scan and magnetic resonance imaging are also sensitive for diagnosing cysticercosis. Lentil lectin glycoprotein enzyme linked immunoelectrotransfer blot assay is the assay of choice for serodiagnosis.<sup>[6]</sup>

## SUMMARY

Cysticercosis is an infection caused due to larval stage of the parasite *T. solium*. The clinical presentation is highly variable ranging from nodules occurring in the skin, subcutis, muscles, intermuscular fascia, and various other organs including the central nervous system. The index case emphasizes the awareness of possibility of parasitic infestation during the evaluation of isolated nodular and cystic swellings yielding fluidy or necrotic material on fine needle aspiration.

## COMPETING INTEREST STATEMENT BY ALL AUTHORS

The authors declare that they have no competing interests.

## AUTHORSHIP STATEMENT BY ALL AUTHORS

Each author has participated sufficiently in the work and takes public responsibility for appropriate portions of the content of this article. All authors read and approved the final manuscript. Each author acknowledges that this final version was read and approved.

## ETHICS STATEMENT BY ALL AUTHORS

Informed and written consent was obtained from the patient. The case was submitted without identifiers.

## LIST OF ABBREVIATIONS (IN ALPHABETIC ORDER)

T. solium: *Taenia solium*

MGG: May Grunwald Giemsa.

## EDITORIAL/PEERREVIEW STATEMENT

To ensure the integrity and highest quality of CytoJournal publications, the review process of this manuscript was conducted under a **double-blind model** (the authors are blinded for reviewers and vice versa) through automatic online system.

## REFERENCES

1. Bhardwaj S, Rather G. Fine needle aspiration cytology of cysticercosis: A study of 30 cases. *J Cytol* 2019;36:18-21.
2. World Health Organization. Multicriteria-based ranking for risk management of food-borne parasites. In: *Microbiological Risk Assessment Series*. Geneva: World Health Organization; 2014. p. 23.
3. Rajwanshi A, Radhika S, Das A, Jayaram N, Banerjee CK. Fine-needle aspiration cytology in the diagnosis of cysticercosis presenting as palpable nodules. *Diagn Cytopathol* 1991;7:517-9.
4. Kala P, Khare P. Fine-needle aspiration cytology as a diagnostic modality for cysticercosis: A clinicocytological study of 137 cases. *J Cytol* 2014;31:68-72.
5. Fan X, Zhang Y, Ouyang R, Luo B, Li L, He W, et al. *Cysticercus cellulosae* regulates T-cell responses and interacts with the host immune system by excreting and secreting antigens. *Front Cell Infect Microbiol* 2021;11:728222.
6. Rodriguez S, Wilkins P, Dorny P. Immunological and molecular diagnosis of cysticercosis. *Pathog Glob Health* 2012;106:286-98.

**How to cite this article:** Gupta S, Gautam P, Kumar P, Kumari N. Inguinal swelling in a young female: An unusual finding. *CytoJournal* 2023;20:27.

HTML of this article is available FREE at:  
[https://dx.doi.org/10.25259/Cytojournal\\_10\\_2023](https://dx.doi.org/10.25259/Cytojournal_10_2023)

The **FIRST Open Access** cytopathology journal

Publish in *CytoJournal* and **RETAIN** your *copyright* for your intellectual property

**Become Cytopathology Foundation Member** to get all the benefits

Annual membership fee is nominal US \$ 50 (US \$ 1000 for life)

**In case of economic hardship it is free**

For details visit <https://cytojournal.com/cf-member>

**PubMed** indexed

**FREE** world wide **open access**

**Online processing** with rapid turnaround time.

**Real time** dissemination of time-sensitive technology.

Publishes as many **colored high-resolution images**

Read it, cite it, bookmark it, use RSS feed, & many----



**CYTOJOURNAL**

[www.cytojournal.com](http://www.cytojournal.com)

Peer-reviewed academic cytopathology journal







# NextGen CelBloking™ Kits

**Frustrated with your cell blocks?  
We have a better solution!**

**Nano**

## Nano NextGen CelBloking™

Cell block kit to process single scattered cell specimens and tissue fragments of **any** cellularity.



**PATENT PENDING**



**Pack #1**



**Pack #2**

**Micro**

## Micro NextGen CelBloking™

For cellular specimens (more than 1 ml concentrated specimen with Tissuecrit more than 50%)



**PATENT PENDING**



**Pack #2**