



Quiz Case

Prominent emperipolesis in breast lesion: A diagnostic challenge

Rishabh Sahai, MD (PATH)¹, Divya Singh, MD (PATH)¹, Vikas Shrivastava, MD (PATH)¹, Mukul Singh, MS (SURGERY)²,
Brijnandan Gupta, MD (PATH)¹

¹Department of Pathology, AIIMS, Gorakhpur, Uttar Pradesh, India.

²Department of Surgery, AIIMS, Gorakhpur, Uttar Pradesh, India.



***Corresponding author:**

Brijnandan Gupta,
Department of Pathology,
AIIMS, Gorakhpur,
Uttar Pradesh, India.

brij9890470@gmail.com

Received: 14 July 2022

Accepted: 12 December 2022

Published: 04 September 2023

DOI

10.25259/Cytojournal_22_2022

Quick Response Code:



A middle-aged woman presented with a lump in her left breast for 8 months. She complained of multiple episodes of intense itching in the lesion along with pus discharge in the past 8 months. May-Grunwald-Giemsa and Papanicolaou stained smears are shown in [Figure 1].

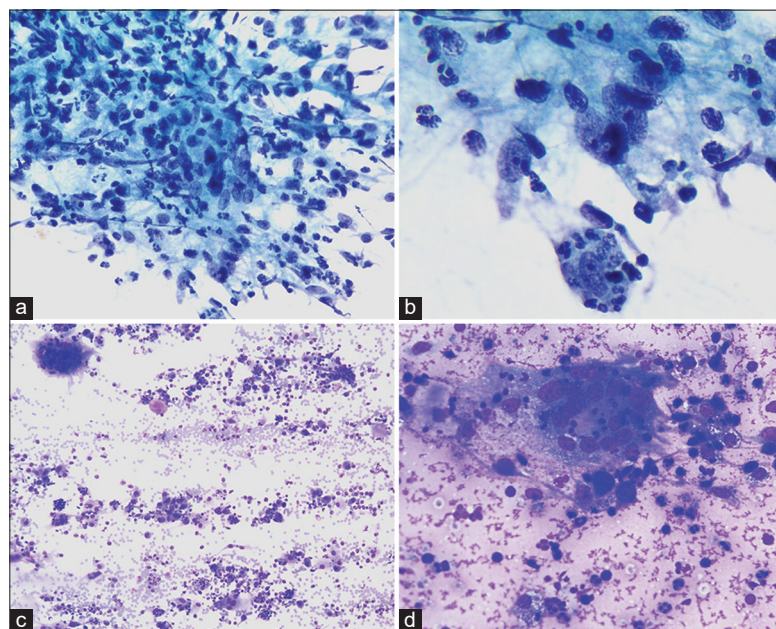


Figure 1: (a) Epithelioid cell granuloma with scattered neutrophils (Papanicolaou ×400), (b) Emperipolesis of neutrophils by histiocyte (lower half) and epithelioid cell granuloma (Papanicolaou ×1000), (c) Giant cell, scattered neutrophils, and histiocytes in the background (MGG ×100), (d) Giant cell and histiocytes (MGG ×400).

QUIZ QUESTIONS

Q1. What is the probable diagnosis?

- A. Tuberculosis
- B. Rosai-Dorfman disease
- C. Idiopathic granulomatous mastitis (IGM)
- D. Sarcoidosis

Answer: C.

Idiopathic granulomatous mastitis (IGM)

Cytological diagnosis of granulomatous mastitis is challenging. Differential diagnoses include tuberculosis, fungal infections, sarcoidosis, and histiocytic disorders including Rosai-Dorfman disease. Cytological features of granulomatous mastitis include the presence of epithelioid cell granulomas, multinucleated giant cells, histiocytes with phagocytosed neutrophils, and numerous neutrophils.

Q2. Which type of cell is phagocytosed by histiocytes in IGM?

- A. Lymphocytes
- B. Neutrophils
- C. Eosinophils
- D. All of the above

Answer: D. Studies have shown that the presence of neutrophils is an important diagnostic clue in diagnosing granulomatous mastitis, as in the present case, where histiocytes showing emperipolesis of neutrophils along with the presence of numerous neutrophils in the background led to the diagnosis in this case. In contrast, Rosai-Dorfman disease shows emperipolesis of lymphocytes. However, in some cases of IGM, lymphocytes and eosinophils have also been seen in the smear or biopsy.

Q3. Based on various studies, which bacteria is associated with IGM?

- A. *Corynebacterium*
- B. *Pseudomonas*
- C. *Atypical mycobacteria*
- D. All of the above

Answer: D. There are many studies which have identified *Corynebacterium* as the dominant bacteria associated with IGM. But *Streptococcus*, *Pseudomonas*, *Atypical Mycobacteria*, and *Actinomyces* have also been identified. Various other etiology of IGM include autoimmunity and abnormal hormonal levels.

Q4. What is the treatment modality for IGM?

- A. Steroid
- B. Immunosuppressive therapy
- C. Surgical excision
- D. All of the above

Answer: D. Patients of IGM have good prognosis with steroids, antibiotics, and immunosuppressive therapy. In some refractory cases, where medical management failed, surgical excision is offered.

BRIEF REVIEW OF THE TOPIC

Granulomatous mastitis is a rare benign inflammatory entity described by Kessler and Wolloch in 1972.^[1] It commonly affects young women of childbearing age usually within a few years of lactation.^[2,3] The most common presentation includes

a painful nodular lump along with induration and redness.^[4] The clinical presentation may mimic malignancy. Cytological diagnosis of the entity remains challenging due to overlapping features with many other conditions including tuberculosis, Rosai-Dorfman disease, and even malignancy.^[1,5]

Various risk factors were studied, but none were specifically related to granulomatous mastitis. Possible etiological factors include an inflammatory response to epithelial damage, *Corynebacterium kroppenstedtii* infection, autoimmune disease, foreign body reaction, and a previous history of antipsychotic medications. In addition, the correlation between granulomatous mastitis and breastfeeding and childbirth was also studied.^[3,4] The radiological features of the entity are non-specific.^[6] The present case did not have a history of medications. She had a history of breastfeeding 8 years ago. Cytological diagnosis of granulomatous mastitis is challenging. Differential diagnoses include tuberculosis, fungal infections, sarcoidosis, and histiocytic disorders including Rosai-Dorfman disease. Cytological features of granulomatous mastitis include the presence of epithelioid cell granulomas, multinucleated giant cells, and numerous neutrophils. The presence or absence of necrosis is not very specific as few studies demonstrated necrosis in all the cases while few studies report necrosis in only a few cases.^[2-5,7] Studies have shown that the presence of neutrophils is an important diagnostic clue in diagnosing granulomatous mastitis, as in the present case where histiocytes showing phagocytosed neutrophils along with the presence of numerous neutrophils in the background led to the diagnosis.^[2,7,8] The prominence of emperipolesis is not a common feature. Apart from infectious causes, the major differential diagnosis considered was Rosai-Dorfman disease of the breast, which also shows an abundance of histiocytes showing emperipolesis. However, the literature search revealed that the type of cells ingested by histiocytes differs in both cases. In the case of Rosai-Dorfman disease, it is the lymphocytes that are being found in the cytoplasm of histiocytes in contrast to neutrophils which are found in granulomatous mastitis.^[8] Other differential diagnoses include sarcoidosis, which shows naked granulomas in the absence of necrosis, which was not the case here. Ziehl-Neelsen stain was performed to rule out tuberculosis, which did not reveal any acid-fast bacilli. Management of granulomatous mastitis includes antibiotics such as doxycycline, corticosteroids with or without surgery, or simple follow-up. Few refractory cases have shown improvement with methotrexate, although consensus on the optimal treatment method is lacking.^[9]

SUMMARY

We discussed a case of granulomatous mastitis presenting in a middle-aged non-lactating woman with no previous history of psychiatric medications, contraceptive pills, or trauma who presented with a nodular lesion. The cytologic diagnosis is based on finding histiocytes with neutrophils, giant cells,

and epithelioid cell granulomas with or without necrosis and excluding other common differential diagnoses such as tuberculosis and fungal infections. As far as IGM is concerned, there is no standard management approach. Therefore, treatment strategies should be tailored to the needs of each patient based on the culture report and response to initial medical management which avoids aggressive management.

COMPETING INTEREST STATEMENT BY ALL AUTHORS

The authors declare that they do not have competing interest.

AUTHORSHIP STATEMENT BY ALL AUTHORS

Each author has participated sufficiently in the work and takes public responsibility for appropriate portions of the content of this article. All authors read and approved the final manuscript. Each author acknowledges that this final version was read and approved.

ETHICS STATEMENT BY ALL AUTHORS

As this is case without identifiers, our institution does not require approval from the Institutional Review Board (IRB).

LIST OF ABBREVIATIONS (In alphabetic order)

IGM - Idiopathic granulomatous mastitis
MGG - May-Grunwald-Giemsa.

EDITORIAL/PEERREVIEW STATEMENT

To ensure the integrity and highest quality of CytoJournal publications, the review process of this manuscript was conducted under a **double-blind model** (the authors are blinded for reviewers and vice versa) through automatic online system.

REFERENCES

1. Kessler E, Wolloch Y. Granulomatous mastitis: A lesion clinically simulating carcinoma. *Am J Clin Pathol* 1972;58:642-6.
2. Al-Khaffaf B, Knox F, Bundred NJ. Idiopathic granulomatous mastitis: A 25-year experience. *J Am Coll Surg* 2008;206:269-73.
3. Johnstone KJ, Robson J, Cherian SG, Cheong JW, Kerr K,

Bligh JF. Cystic neutrophilic granulomatous mastitis associated with *Corynebacterium* including *Corynebacterium kroppenstedtii*. *Pathology* 2017;49:405-12.

4. Wolfrum A, Kümmel S, Theuerkauf I, Pelz E, Reinisch M. Granulomatous mastitis: A therapeutic and diagnostic challenge. *Breast Care (Basel)* 2018;13:413-8.
5. Tse GM, Poon CS, Law BK, Pang LM, Chu WC, Ma TK. Fine needle aspiration cytology of granulomatous mastitis. *J Clin Pathol* 2003;56:519-21.
6. Sripathi S, Ayachit A, Bala A, Kadavigere R, Kumar S. Idiopathic granulomatous mastitis: A diagnostic dilemma for the breast radiologist. *Insights Imaging* 2016;7:523-9.
7. Helal TE, Shash LS, Saad El-Din SA, Saber SM. Idiopathic granulomatous mastitis: Cytologic and histologic study of 65 Egyptian patients. *Acta Cytol* 2016;60:438-44.
8. Rajyalakshmi R, Akhtar M, Swathi Y, Chakravarthi R, Reddy JB, Priscilla MB. Cytological diagnosis of Rosai-Dorfman disease: A study of twelve cases with emphasis on diagnostic challenges. *J Cytol* 2020;37:46-52.
9. Martinez-Ramos D, Simon-Monterde L, Suelves-Piqueres C, Queralt-Martin R, Granel-Villach L, Laguna-Sastre JM, et al. Idiopathic granulomatous mastitis: A systematic review of 3060 patients. *Breast J* 2019;25:1245-50.

How to cite this article: Sahai R, Singh D, Shrivastava V, Singh M, Gupta B. Prominent emperipolesis in breast lesion: A diagnostic challenge. *CytoJournal* 2023;20:32.

HTML of this article is available FREE at:
https://dx.doi.org/10.25259/Cytojournal_22_2022

The FIRST Open Access cytopathology journal

Publish in *CytoJournal* and RETAIN your copyright for your intellectual property

Become **Cytopathology Foundation Member** to get all the benefits

Annual membership fee is nominal US \$ 50 (US \$ 1000 for life)

In case of economic hardship it is free

For details visit <https://cytojournal.com/cf-member>

PubMed indexed

FREE world wide open access

Online processing with rapid turnaround time.

Real time dissemination of time-sensitive technology.

Publishes as many colored high-resolution images

Read it, cite it, bookmark it, use RSS feed, & many----



CYTOJOURNAL

www.cytojournal.com

Peer-reviewed academic cytopathology journal





NextGen CelBloking™ Kits

**Frustrated with your cell blocks?
We have a better solution!**

Nano

Nano NextGen CelBloking™

Cell block kit to process single scattered cell specimens and tissue fragments of **any** cellularity.



PATENT PENDING



Pack #1



Pack #2

Micro

Micro NextGen CelBloking™

For cellular specimens (more than 1 ml concentrated specimen with Tissuecrit more than 50%)



PATENT PENDING



Pack #2