


Quiz Case

Duct tales of a parotid gland swelling

Swati Raj, MD pathology¹, Monika Singh, MD Pathology¹, Mamta Gupta, MD Pathology¹, Naveen Thapliyal, MD Pathology¹

¹Department of Pathology, Government Doon Medical College, Dehradun, Uttarakhand, India.



An Indian male in his mid-30s complaining of a progressively enlarging right parotid swelling for the past 5 years, with a history of exposure to tuberculosis from a close contact. The ultrasound (USG) report suggests a retention cyst, measuring 5.2 × 4.4 × 2 cm. Direct fine-needle aspiration (FNA) yielded 1 mL of thick, yellowish, turbid fluid, and swelling was reduced slightly after aspiration [Figure 1a-c].

*Corresponding author:

Swati Raj,
Department of Pathology,
Government Doon Medical
College, Dehradun,
Uttarakhand, India.
drsraj29@gmail.com

Received: 13 January 2023

Accepted: 10 March 2023

Published: 29 August 2023

DOI

10.25259/Cytojournal_4_2023

Quick Response Code:

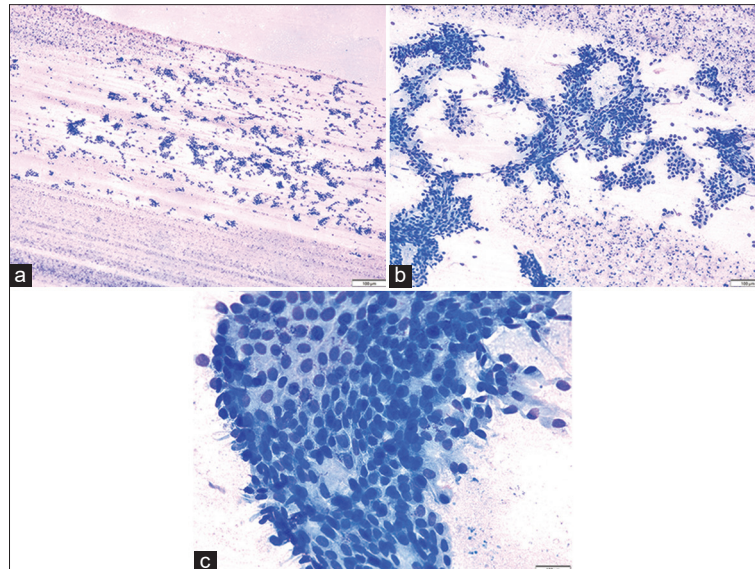


Figure 1: (a and b) Direct FNA smears show cells in papillary architecture in an abundant proteinaceous background (MGG, a: ×400, b: ×1000). (c) Large cohesive sheet of benign looking cells, showing oncocytic changes and minimal nuclear irregularity (MGG, ×4000).

QUESTION # 1

What is the most likely interpretation of FNA using the Milan system? [Figure 1a-c]

- Non-neoplastic
- Atypia of undetermined significance
- Neoplasm: Benign
- Neoplasm: Salivary gland neoplasm of uncertain malignant potential (SUMP)
- Malignant.

ANSWER TO QUESTION # 1

c. Neoplasm: Benign.

FNA smears were cellular and showed benign-looking epithelial cells arranged in large cohesive sheets, clusters, and groups. They exhibit mild degenerative nuclear changes and abundant eosinophilic granular cytoplasm. Background showed abundant eosinophilic proteinaceous material along with a few neutrophils, lymphocytes, macrophages, and debris. There was no evidence of mitosis, necrosis, or atypia in the smears examined. To interpret and report the case, “*The Milan System for Reporting Salivary Gland Cytopathology*” was used; the cytomorphological features were suggestive of Category IV A – Benign Salivary Gland Neoplasm.

On inquiry, the patient showed a previous (3 months prior) USG report and fine-needle aspiration cytology (FNAC), which were done outside. The USG report was suggestive of a retention cyst and the FNAC was consistent with the radiological findings of a “*Retention cyst.*”

QUESTION # 2

An excisional biopsy was performed after 12 days of FNAC. On the basis of gross and microscopic findings, what is the diagnosis? [Figure 2a-d]

- Cystadenoma
- Sclerosing polycystic adenosis
- Acinic cell carcinoma (papillary cystic pattern)
- Mammary analog secretory carcinoma
- Low-grade intraductal carcinoma.

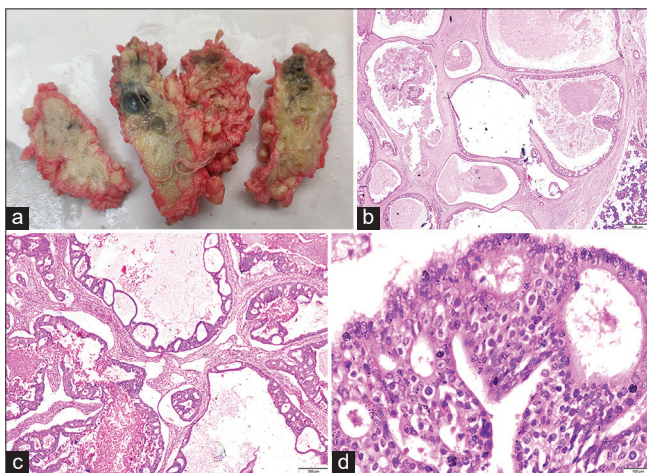


Figure 2: (a) Gross specimen of superficial parotidectomy show solid cystic cut surface. (b) Cystically dilated ducts with tufted, micropapillary anastomosing proliferations of epithelial ductal cells; tumor area with normal serous salivary gland (H&E, $\times 200$). (c and d) Intraductal proliferations with Roman Bridges and “pseudocribiform” papillary architecture of tumor cells, displaying mild to moderate pleomorphism (H&E, c: $\times 1000$, d: $\times 4000$).

ANSWER TO QUESTION # 2 AND FOLLOW-UP OF CASE

e. Low-grade intraductal carcinoma.

There was no evidence of necrosis grossly. Multiple H&E stained sections examined under the microscope showed a salivary gland neoplasm consisting of solid and cystic areas. Cysts showed intracystic and intraductal proliferation of neoplastic epithelial cells arranged in papillary, micropapillary, and “pseudocribiform” architecture, displaying false punched out spaces and “Roman bridge” formation. The cysts cavities were filled with proteinaceous secretions. Tumor cells exhibit mild-to-moderate pleomorphism, vesicular chromatin, inconspicuous 1–2 nucleoli, and a moderate to abundant amount of eosinophilic cytoplasm. At places, a few cells showed apocrine changes. Myoepithelial cells were noted. Adjoining stroma showed areas of hemorrhage and lymphoid cell proliferation, well demarcated from normal salivary gland acini. Tiny foci of necrosis were identified; however, an invasion was not seen. Mitosis was exceedingly rare. No lymphovascular or perineural invasion was noted. Surgical margins were free of tumor cells. Four intraparotid lymph nodes identified microscopically showed features of reactive lymphoid hyperplasia.

To conclude the diagnosis, whole tissue was processed to screen for invasion, which was not identified on the total of 19 sections passed. Thereafter, a diagnosis of “Low-grade-Intraductal Carcinoma” was awarded. Immunohistochemistry (IHC) was performed by application of S100, which came out negative for tumor cells.

Post-operative course

The post-operative course of the patient was fair, and facial nerve palsy was not noted. No swelling recurs at the surgical site or in the nearby regional area on physical examination or radiological investigation, stating that, *there is no recurrent disease 12 months after surgery.*

QUESTION # 3

What is/are the diagnostic feature of low-grade intraductal carcinoma?

- “Pseudocribiform” architecture displaying false punched-out spaces and “Roman bridge” formation without invasion
- Intracystic and intraductal proliferation of neoplastic epithelial cells arranged in a papillary and micropapillary pattern with invasion
- Absence of S100 IHC positivity
- Lymphovascular or perineural invasion
- Absence of myoepithelial cells and presence of rare mitosis.

ANSWER TO QUESTION # 3

- a. “Pseudocribiform” architecture displaying false punched-out spaces and “Roman bridge” formation without invasion.

QUESTION # 4

What are the major pitfalls observed in the cytohistomorphological correlation of this case?

- Gross aspiration of thick yellow fluid, followed by slight reduction of size of the swelling
- USG findings suggestive of retention cyst
- Long-standing history of 5 years
- Murky fluid in background and no evidence of atypia/malignancy noted
- All of the above.

ANSWER TO QUESTION # 4

- e. All of the above.

This case was mislabeled as a retention cyst on USG and was unrecognized and under-diagnosed on FNAC done outside in a private laboratory despite being an extremely rare entity. On both occasions, FNA procedures done outside as well as in our department yielded similar fluidy aspirates [Table 1].

Although making a definite diagnosis of this tumor on FNA smears is challenging, at least can be suggested as salivary gland neoplasm. The Category IV A, B, and C of Milan’s system is highly overlapping. The presence of above-mentioned cytomorphological findings is of a salivary gland multicystic neoplasm; however, exact diagnosis is almost impossible. However, raising the diagnostic possibility of salivary gland neoplasm rather than just a cyst in a pre-operative FNA would be of great help to the surgeon so that the complete resection was planned. The distinguished nomenclature relies solely on histopathological examination of stromal invasion that cannot be evaluated on pure cytological grounds.

Warthin’s tumor was one of the differential diagnoses considered due to the classical background (consisting of few lymphocytes) and cystic nature of the tumor, as well as the few oncocytic looking cells; however, the florid lymphoid background was absent in our case. The lymphocytic background is sometimes very misleading, as in the present case, as hitting an intrasalivary gland lymph node gives a similar picture on a smear, even when associated with oncocytic looking cells.

QUESTION # 5

What are the most obvious biopsy findings describing the present case’s prognosis?

- Cystic areas
- Mild atypia

Table 1: The clues or features favoring on FNAC performed in our laboratory are as follows.

Neoplastic etiology	Benign in nature/against malignant etiology
1. High cellularity	1. Fluid aspiration on two attempts
2. Swelling size	2. Size mildly reduced after aspiration
3. Progressive	3. Cohesive cell arrangement
4. Fixed and firm in consistency	4. No definite atypia
5. Non-tender, no signs of inflammation	5. No mitosis
	6. No necrosis
	7. Murky fluid or proteinaceous background
	8. No hemorrhage
	9. Ultrasound report

FNAC: Fine-needle aspiration cytology

- Absence of necrosis
- Negative surgical margins and absence of stromal invasion
- All of the above.

ANSWER TO QUESTION # 5

- Negative surgical margins and absence of stromal invasion.

BRIEF REVIEW OF THE TOPIC

Low-grade intraductal carcinoma (LG-IC) is a rare salivary gland malignant tumor.^[1] To the best of our knowledge, only 56 cases have been reported in the archives to date. The United States accounts for half of all reported cases, followed by Japan (26%), Canada, China, Korea, Taiwan, Czech Republic, and Italy.^[1-5] So far, only one case has been documented in India as an incidental diagnosis on an excision biopsy of a 56-year-old female, who was clinically and radiologically diagnosed with a pleomorphic adenoma of the palate.^[6]

In 1996, Delgado *et al.*,^[7] mentioned LG-ICs for the first time in a case series, where it was described as a “*mass forming lesion with morphological features analogous to mammary ductal hyperplasia and intact myoepithelial cell layer.*” Since then, the nomenclature of LG-IC has been reviewed at times. It was renamed from “*Low-grade cribriform cystadenocarcinoma*” or “*Low-grade salivary duct carcinoma*” to “*Salivary duct carcinoma in situ*” in 2005.^[8,9] In 2017, the World Health Organization Head and Neck tumors reclassified the entities LGCCC and salivary duct carcinoma

in situ collectively as “*Intraductal carcinoma*,” with *low-grade* and *high-grade* features, respectively.^[10-12]

In the majority of cases, LG-ICs are seen in a wider age range of 27–93 years, with a slight female (M: F = 1:1.3) predilection.^[2-5] The most common site is the parotid gland (>80%), with rare occurrences in minor salivary glands. The clinical presentation of LG-IC is mostly a circumscribed cystic mass with indolent behavior. Exceptionally, LG-IC can be intranodal, having arisen from salivary gland inclusions in the lymph node. Macroscopically, LG-ICs are well-circumscribed, non-encapsulated, multicystic lesions; a size varying from 0.7 to 5.3 cm, and contain serous to hemorrhagic fluid.^[1] Histologically, following variants have been described:

- Intercalated duct-like (most common)^[13]
- Apocrine^[11]
- Mixed/hybrid
- Possibly oncocytic, but may be a variant of intercalated duct type.^[14]

Complete surgical excision with preservation of the facial nerve is the most commonly practiced management at present. LG-IC has an excellent prognosis after complete excision, with no metastasis or mortality at a follow-up of 2–12 years, regardless of nuclear grade. However, recurrence can occur as a result of incomplete resection, positive surgical margins, or metastasis. The previous systemic reviews illustrate that adjuvant radiotherapy is not justified for tumor resections with negative margins, even in the presence of a close margin. However, it may be advised in cases of positive margins or invasive tumors.^[1]

A systematic review performed by Giovacchini *et al.*^[1] revealed the heterogeneous morphology of tumor cells lacking cellular or nuclear pleomorphism, prominent nucleoli, significant mitotic activity, and necrosis. Furthermore, these tumors had no local or perineural invasion.^[1,2,7,15]

Nakazawa *et al.*,^[4] Jeong *et al.*,^[16] and Kokabu *et al.*,^[17] showed FNA reports suggestive of a cystic lesion with a mildly irregularly shaped nucleus with inconspicuous nucleoli and little atypia; some had single, large, and clear cytoplasmic vacuoles. Background showed scattered lymphocytes, neutrophils, macrophages, and eosinophils. The FNA morphology is closely similar to our case findings with specific backgrounds.

Kuo *et al.*^[18] identified the following LG-IC multicystic architecture differential diagnoses: cystadenocarcinoma, cystadenoma, salivary duct carcinoma *in situ*/high-grade intraductal carcinoma, conventional salivary duct carcinoma, acinic cell carcinoma (Papillary Cystic Pattern), mammary analog secretory carcinoma, sclerosing polycystic adenosis, ductal adenoma with striated duct differentiation, and intercalated duct lesion.

According to the literature, FNAC has lower sensitivity to cliché the diagnosis of LG-IC as malignant, with only four FNAs out of all cases reported to date showing malignant neoplasms,^[11,17,19] 23% of cases reported as benign,^[12,20,21] and 46% of cases reported as SUMP.^[3-5,17,22]

Immunohistochemically, Giovacchini *et al.*^[1] reviewed that total 55 cases revealed that 92% cases showed tumor cells positive for S-100, 18% for cytokeratinAE-1/AE-3, 14.5% for mammaglobin, 67% for GCDFP-15, 94% for calponin, 86% for DOG1, 91% for CK14, 95% for SMA, 70% for CEA, and 11% for CK7. Instead, 95% of tumor cells were negative for Her-2/neu, 62% for androgen receptor, 90% for ER, 90% for PR, and 75% for p53. In LG-IC, GATA-3 was generally negative; it may be useful in distinguishing LG-IC from mammary secretory carcinoma, metastatic squamous cell carcinoma, mucoepidermoid carcinoma, salivary duct carcinoma, and Warthin tumor, which are usually positive.^[23] The role of IHC is found to be supportive, however not specific, as well as controversial in the diagnosis for LG-IC.

SUMMARY

LG-ICs are unique in their cytohistomorphological complexity. On histomorphology, they have classical non-invasive pseudocribiform and Roman bridges-like architectural patterns, which are similar to the pattern seen in low-grade intraductal breast carcinoma. This specific tumor is considered the counterpart of low-grade intraductal breast carcinoma, which is highly debatable and still not confirmed. On FNAC, the overlapping cytomorphological features make its identification as a malignant tumor more difficult. FNAC plays a pivotal role in detecting both benign and malignant etiologies, the latter in those not suitable for attempted curative surgery or with recurrent disease before palliative treatment, and can also reduce the rate of salivary gland surgery by one-half to one-third. The crux of the case reported is the importance of FNA with good skills to identify neoplastic etiology, especially indolent malignant tumors like LG-IC when cytomorphological features are benign-looking. However, histopathological examination is considered the “*gold standard*” to arrest the diagnosis of LG-ICs, and after complete excision, it carries an excellent prognosis.

COMPETING INTEREST STATEMENT BY ALL AUTHORS

The authors declare that they have no competing interest.

AUTHORSHIP STATEMENT BY ALL AUTHORS

Each author has participated sufficiently in the work and takes public responsibility for the appropriate portions of

the content of this article. SR: Conceptualization reported and performed FNAC, drafting of the manuscript, literature review. MS: Data acquisition, biopsy reporting, MG: Grossing and reported excision biopsy, critical review, and NT: Revising it critically for important intellectual content and finalization of the manuscript. Each author acknowledges that this final version was read and approved.

ETHICS STATEMENT BY ALL AUTHORS

As this is a quiz case without identifiers, our institution does not require approval from the Institutional Review Board (IRB).

LIST OF ABBREVIATIONS (In alphabetic order)

AUS – Atypia of undetermined significance
 FNA – Fine-needle aspiration
 FNAC – Fine-needle aspiration cytology
 IHC – Immunohistochemistry
 LG-IC – Low-grade-intraductal carcinoma
 SUMP – Salivary gland neoplasm of uncertain malignant potential
 USG – Ultrasonography/ultrasound.

EDITORIAL/PEER-REVIEW STATEMENT

To ensure the integrity and highest quality of CytoJournal publications, the review process of this manuscript was conducted under a **double-blind model** (authors are blinded for reviewers and vice versa) through automatic online system.

REFERENCES

- Giovacchini F, Bensi C, Belli S, Laurenti ME, Mandarano M, Paradiso D, *et al.* Low-grade intraductal carcinoma of salivary glands: A systematic review of this rare entity. *J Oral Biol Craniofac Res* 2019;9:96-110.
- Kusafuka K, Itoh H, Sugiyama C, Nakajima T. Low-grade salivary duct carcinoma of the parotid gland: Report of a case with immunohistochemical analysis. *Med Mol Morphol* 2010;43:178-84.
- Kimura M, Mii S, Sugimoto S, Saida K, Morinaga S, Umemura M. Low-grade cribriform cystadenocarcinoma arising from a minor salivary gland: A case report. *J Oral Sci* 2016;58:145-9.
- Nakazawa T, Kondo T, Yuminomochi T, Nakazawa K, Ishii Y, Mochizuki K, *et al.* Fine-needle aspiration biopsy of low-grade cribriform cystadenocarcinoma of the salivary gland. *Diagn Cytopathol* 2011;39:218-22.
- Ohta Y, Hirota Y, Kohno Y, Kishimoto K, Norose T, Ohike N, *et al.* Cytology of low-grade cribriform cystadenocarcinoma in salivary glands: Cytological and immunohistochemical distinctions from other salivary gland neoplasms. *Diagn Cytopathol* 2016;44:241-5.
- Devi A, Narwal A, Kamboj M, Gupta M, Pandiar D. Low grade intraductal carcinoma of palate: An extremely rare entity with review of literature August 2020. *Indian J Otolaryngol Head Neck Surg* 2022;74:2222-7.
- Delgado R, Klimstra D, Albores-Saavedra J. Low grade salivary duct carcinoma. A distinctive variant with a low grade histology and a predominant intraductal growth pattern. *Cancer* 1996;78:958-67.
- Seethala RR, Stenman G. Update from the 4th edition of the world health organization classification of Head and neck tumours: Tumors of the salivary gland. *Head Neck Pathol* 2017;11:55-67.
- Barnes L, Eveson JW, Reichart P, Sidransky D. *Pathology and Genetics Head and Neck Tumors*. Geneva: World Health Organization; 2005.
- Weinreb I. Intraductal carcinoma of salivary gland (So-Called low-grade cribriform cystadenocarcinoma) arising in an intraparotid lymph node. *Head Neck Pathol* 2011;5:321-5.
- Weinreb I, Tabanda-Lichauco R, Van Der Kwast T, Perez-Ordoñez B. Low-grade intraductal carcinoma of salivary gland: Report of 3 cases with marked apocrine differentiation. *Am J Surg Pathol* 2006;30:1014-21.
- Nishijima T, Yamamoto H, Nakano T, Hatanaka Y, Taguchi KI, Masuda M, *et al.* Low-grade intraductal carcinoma (low grade cribriform cystadenocarcinoma) with tumor-associated lymphoid proliferation of parotid gland. *Pathol Res Pract* 2017;213:706-9.
- Weinreb I, Bishop JA, Chiosea SI, Seethala RR, Perez-Ordonez B, Zhang L, *et al.* Recurrent RET gene rearrangements in intraductal carcinomas of salivary gland. *Am J Surg Pathol* 2018;42:442-52.
- Bishop JA, Nakaguro M, Whaley RD, Ogura K, Imai H, Laklouk I, *et al.* Oncocytic intraductal carcinoma of salivary glands: A distinct variant with TRIM33-RET fusions and BRAF V600E mutations. *Histopathology* 2021;79:338-46.
- Brandwein-Gensler M, Hille J, Wang BY, Urken M, Gordon R, Wang LJ, *et al.* Low-grade salivary duct carcinoma: Description of 16 cases. *Am J Surg Pathol* 2004;28:1040-4.
- Jeong JY, Ahn D, Park JY. Fine-needle aspiration cytology of low-grade cribriform cystadenocarcinoma with many psammoma bodies of the salivary gland. *Korean J Pathol* 2013;47:481-5.
- Kokabu S, Nojima J, Kayano H, Yoda T. Low-grade cribriform cystadenocarcinoma of the palatal gland: A case report. *Oncol Lett* 2015;10:2453-7.
- Kuo YJ, Weinreb I, Perez-Ordonez B. Low-grade salivary duct carcinoma or low-grade intraductal carcinoma? Review of the literature. *Head Neck Pathol* 2013;7:59-67.
- Obokata A, Sakurai S, Hirato J, Sakamoto K, Takekoshi T, Aoki J. Cytologic features of low-grade cribriform cystadenocarcinoma of the submandibular gland: A case report. *Acta Cytol* 2013;57:207-12.
- Arai A, Taki M, Mimaki S, Ueda M, Hori S. Low-grade cribriform cystadenocarcinoma of the parotid gland: A case report. *Auris Nasus Larynx* 2009;36:725-8.
- Wakabayashi N, Umezawa H, Matsumoto NM, Endo Y, Naito Z, Ogawa R. Low-grade cribriform cystadenocarcinoma:

A review of the literature and case report. *Plast Reconstr Surg Glob Open* 2017;5:e1306.

22. Ko YS, Koo JS. Cytomorphological findings and histological correlation of low-grade cribriform cystadenocarcinoma of salivary gland in fine-needle aspiration: A case study. *Korean J Pathol* 2013;47:592-5.
23. Schwartz LE, Begum S, Westra WH, Bishop JA. GATA3

immunohistochemical expression in salivary gland neoplasms. *Head Neck Pathol* 2013;7:311-5.

How to cite this article: Raj S, Singh M, Gupta M, Thapliyal N. Duct tales of a parotid gland swelling. *CytoJournal* 2023;20:22.

HTML of this article is available FREE at:
https://dx.doi.org/10.25259/Cytojournal_4_2023

The FIRST **Open Access** cytopathology journal

Publish in *CytoJournal* and **RETAIN** your *copyright* for your intellectual property

Become Cytopathology Foundation Member to get all the benefits

Annual membership fee is nominal US \$ 50 (US \$ 1000 for life)

In case of economic hardship it is free

For details visit <https://cytojournal.com/cf-member>

PubMed indexed

FREE world wide **open access**

Online processing with rapid turnaround time.

Real time dissemination of time-sensitive technology.

Publishes as many **colored high-resolution images**

Read it, cite it, bookmark it, use RSS feed, & many----



CYTOJOURNAL

www.cytojournal.com

Peer-reviewed academic cytopathology journal





NextGen CelBloking™ Kits

**Frustrated with your cell blocks?
We have a better solution!**

Nano

Nano NextGen CelBloking™

Cell block kit to process single scattered cell specimens and tissue fragments of **any** cellularity.



PATENT PENDING



Pack #1



Pack #2

Micro

Micro NextGen CelBloking™

For cellular specimens (more than 1 ml concentrated specimen with Tissuecrit more than 50%)



PATENT PENDING



Pack #1



Pack #2