



Research Article

# Molecular analysis with pancreaseq® in evaluation and management of pancreatic cysts: A cohort of 28 patients

Gokce Deniz Ardor, Medical Doctor MD,<sup>1</sup> Helena Hanna, MD,<sup>2</sup> Bora Ozalp, MD,<sup>3</sup> Aziza Nassar, MD, MBA, MPH<sup>1</sup>

<sup>1</sup>Department of Pathology and Laboratory Medicine, Mayo Clinic, Jacksonville, <sup>2</sup>Department of Biomedical Sciences, University of South Florida, Tampa, Florida, <sup>3</sup>Department of Biomedical Sciences, Upper School, Detroit Country Day School, Detroit, Michigan, United States.



**\*Corresponding author:**

Aziza Nassar,  
Department of Pathology and  
Laboratory Medicine, Mayo  
Clinic, Jacksonville, Florida,  
United States.

nassar.aziza@mayo.edu

Received: 13 April 2023

Accepted: 10 July 2023

Published: 01 September 2023

**DOI**

10.25259/Cytojournal\_28\_2023

**Quick Response Code:**



## ABSTRACT

**Objectives:** Herein, we present the PancreaSeq® results of 28 patients and emphasize the usefulness of molecular testing in evaluation of pancreatic cysts.

**Material and Methods:** A total of 10 (35.7%) non-diagnostic, 6 (21.4%) negative, 5 (17.8%) atypical, and 7 (25%) were positive for mucinous cystic neoplasm (MCN) pancreatic cyst aspirates were analyzed with PancreaSeq® at Mayo Clinic, Jacksonville between September 2021 and February 2023.

**Results:** Three non-diagnostic, two negative, three atypical, and two positive for MCN cysts were positive for KRAS and GNAS mutations. They were interpreted as intraductal papillary mucinous neoplasm (IPMN) with low risk for progression to high-grade dysplasia/adenocarcinoma. One negative case was positive for KRAS and GNAS mutation and RNF43 copy number alteration. It was interpreted as IPMN with a low risk of progression. Two non-diagnostic, one negative, and two positive for MCN cysts were positive for KRAS mutation. All were interpreted as IPMN/MCNs with low risk of progression. One positive for MCN case was positive for GNAS mutation and ALK fusion and one positive for MCN case was positive for GNAS mutation, ALK fusion, and RNF43 copy number alteration. Both were interpreted as IPMN and their risk of progression was interpreted as not well understood. One atypical case was positive for KRAS and TP53 mutation and was interpreted as IPMN/MCNs with a high risk of progression. VHL mutation was present in one non-diagnostic case. It was interpreted as serous cystadenoma and the risk for progression was low.

**Conclusion:** Molecular analysis of pancreatic cysts with PancreaSeq® is useful in accurate diagnosis, especially when cytologic material is non-diagnostic and helps improve patient management.

**Keywords:** Pancreatic cysts, Pancreatic fine-needle aspiration cytology, Molecular analysis, PancreaSeq®, Next-generation sequencing

## INTRODUCTION

Pancreatic cysts are a broad group of pancreatic lesions that can be benign or malignant in nature, resembling solid pancreatic lesions. Incidental detection rates of pancreatic cysts had increased in recent years due to the advancements in imaging modalities such as computed tomography or magnetic resonance imaging (MRI). The incidence rates are increasing with age and are reported as between 2.6% and 13.5%, according to the most recent reports.<sup>[1,2]</sup> Pseudocysts, serous cystadenomas (SCAs), solid-pseudopapillary neoplasm (SPN), mucinous cystic neoplasm (MCN), and intraductal papillary mucinous neoplasms (IPMN) are some of the cystic lesions most observed in the pancreas with MCN and IPMN representing mucinous pancreatic cystic

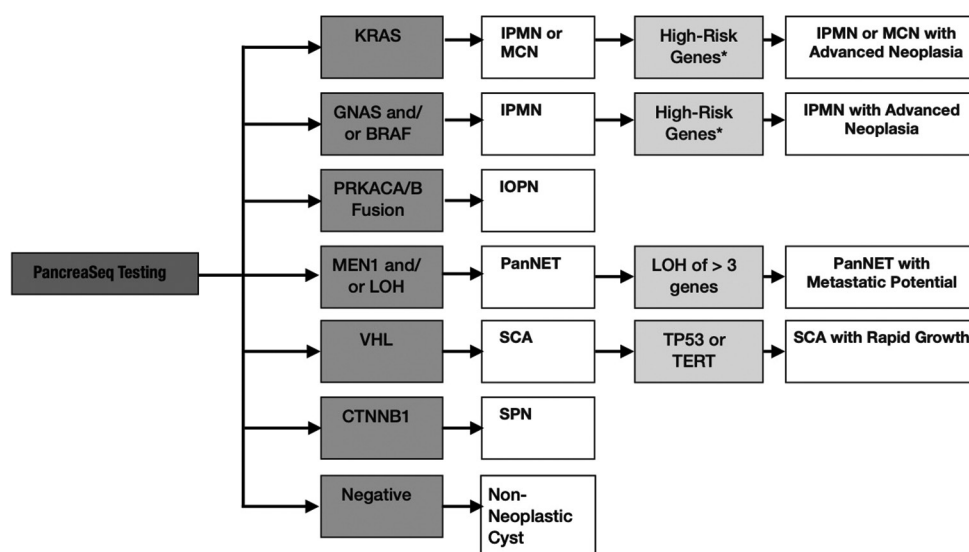
neoplasms. Considering this wide spectrum of pancreatic cysts and their respective malignant potentials, an accurate differential diagnosis and further management are vital for proper patient care and management. At present, imaging results, cytologic analysis of cyst material, and adjunct biochemical testing such as amylase and carcinoembryonic antigen (CEA) are the most common diagnostic tools used for these types of lesions. Unfortunately, these diagnostics tools are not always sufficient. Although cytologic testing is a valuable tool, aspirates can sometimes contain limited material or degenerated cells, which distorts the analysis process. Molecular testing is being performed on these aspirates, even if the material is limited or contains degenerated cells, with accurate results about the genetic abnormalities observed in the different distinct subtypes of cysts.<sup>[3]</sup> Several genetic alterations associated with the most common pancreatic cysts with a high risk of cancer have been revealed by sequencing studies,<sup>[4,5]</sup> which increases its importance as a valuable diagnostic and prognostic tool. PancreaSeq® Genomic classifier is a next-generation sequencing (NGS) test that analyzes 20 tumor genes and detects the mutations related to the precursors of pancreatic cancer.<sup>[6]</sup> It is currently used as a molecular diagnostic adjunct tool for pancreatic cysts detected by imaging and can detect single nucleotide variants and insertions/deletions in targeted regions of 20 pancreatic-related genes and copy number alterations in four genes, which include KRAS, GNAS, NRAS, BRAF, AKT1, APC, CTNNB1, HRAS, IDH1, IDH2, MET, PIK3CA, MEN1, NF2, PTEN, STK11, TERT, VHL, TP53, and TSC2. This targeted NGS technique can

help us in the diagnosis of different types of pancreatic cysts and in the risk assessment for progression to cancer. While mitogen-activated protein kinase gene and/or GNAS gene mutations are specific for mucinous cysts, TP53, SMAD4, and mammalian target of rapamycin alterations are linked to progressive neoplasia, such as high-grade dysplasia and pancreatic ductal adenocarcinoma arising from a mucinous cyst.<sup>[7]</sup> Other pancreatic cyst types, including SCAs, SPNs, and cystic pancreatic neuroendocrine tumors, which are characterized by mutations in VHL, CTNNB1, and MEN1, can also be discovered through NGS [Figure 1].

Thus, PancreaSeq® helps in the diagnosis and clinical management of the most common pancreatic cysts and is a useful and informative method, especially when cytology is non-diagnostic or aspirates contain limited/degenerated cells. In this study, we present the PancreaSeq® testing results of 28 patients at our institution between September 2021 and February 2023 and we highlight the usefulness of PancreaSeq® as an adjunctive testing in the evaluation of pancreatic cysts.

## MATERIAL AND METHODS

Twenty-eight cyst fluids were analyzed with PancreaSeq® at the cytopathology laboratory of Mayo Clinic, Jacksonville between September 2021 and February 2023. Among these aspirates, 10 (35.7%) were non-diagnostic, 6 (21.4%) were negative, 5 (17.8%) were atypical, and 7 (25%) were positive for mucinous neoplasm. None of the samples were reported



**Figure 1:** Significant genomic alterations reported with PancreaSeq® testing and their clinical relevance. \*High-risk genes that includes genomic alterations in TP53, SMAD4, CTNNB1, and mTOR genes. mTOR: Mammalian target of rapamycin, IPMN: Intraductal papillary mucinous neoplasm, MCN: Mucinous cystic neoplasm, IOPN: Intraductal oncocytic papillary neoplasm, PanNET: pancreatic neuroendocrine tumor, SCA: Serosus cystic neoplasm, SPN: Solid pseudopapillary serous cystic adenoma.

as suspicious for mucinous neoplasm in the cytology report. All patients underwent endoscopic ultrasound (EUS) with pancreatic cyst aspiration. Sixteen of them were female and 12 of them were male. The ages of the cohort were ranging between 45 and 91 (median 69.5 and mean of 68.2). Fifteen had a prior history of cirrhosis, pancreatitis, end-stage renal disease, alcoholic and non-alcoholic liver disease, Type 2 diabetes, and/or transplant whereas 13 of them had no prior history of other medical conditions and were diagnosed incidentally. The location of the pancreatic cysts was as follows: Nine in the head, Seven in the body, six in the tail, three in the neck, and three in the uncinata process. The size of the cysts ranged between 2 cm and 6.3 cm (median 3.1 and mean 3.3).

EUS was performed while patients were under sedation using 22-gauge–25-gauge needles, depending on the clinical characteristics of the lesion. The cysts and the remaining pancreas were evaluated and fine-needle aspiration (FNA) of the cysts was performed. Cyst fluid was aspirated and available in all cases which was adequate (>2 mL) for further analysis.

CEA levels from cystic lesions were retrieved from the reports of 20 patients. Cyst fluid was tested with the Access CEA immunoassay as reported in guidelines.<sup>[8]</sup> Amylase levels were retrieved from the reports of eight patients. For PancreaSeq® analysis, the manufacturer's (University of Pittsburgh Medical Center Molecular Genomic Pathology Laboratory) instructions for collection of the cyst fluid samples were followed. In a patient-labeled vial with 600 mL of stabilization fluid, 2–6 mL of fluid were aspirated, the tube cover was secured, and the vial was repeatedly inverted to mix the sample that had been collected. To maintain the integrity of the specimen, samples were sent through overnight delivery with ice packs. A completed test request form and the pathology report were sent with each sample.

Cytologic evaluation and classification was performed for all cases, according to the most recent Papanicolaou Society of Cytopathology Terminology and Nomenclature for Pancreatobiliary Cytology,<sup>[9]</sup> to include non-diagnostic, negative, atypical, suspicious, and malignant/positive categories. According to this classification, the non-diagnostic category is defined as a sample that provides no diagnostic information about the lesion/area sampled. The samples that were categorized as non-diagnostic in this study were mostly acellular. Negative is defined as the absence of malignancy and cellular atypia and contains benign cellular material. In this study, the samples that were categorized as negative mostly contained scant cellularity and rare pancreatic mucinous/non-mucinous epithelium. Atypical is defined as a sample that contains cells with morphologic features beyond normal/reactive changes but are insufficient to classify them as suspicious/malignant. Suspicious is

defined as a sample that contains cells with morphologic features that quantitatively and/or qualitatively fall short of a definitive diagnosis of malignancy. The malignant category was defined as a sample that contains cells that show malignant cytologic features.

## RESULTS

The cyst characteristics, cytologic evaluation, and PancreaSeq® results of each patient were summarized in [Table 1].

In our cohort, most of the samples (10, 35.7%) were non-diagnostic on cytologic evaluation. They were either reported as acellular or mucinous epithelium not identified. Six of them had a positive PancreaSeq® analysis and four of them were negative for any genetic alterations. Three cases were positive for both KRAS and GNAS mutations with no gene fusions or copy number alterations. These three cysts were interpreted as mucinous (IPMN) and their risk of progression to high-grade dysplasia/adenocarcinoma were interpreted as low. Radiologic evaluation demonstrated ductal dilation in one of these cases up to 12 mm. The CEA (CEACAM5) levels were low. The CEA levels were studied in all of them and as follows: 875 ng/mL, 691 ng/mL, and 680 ng/mL. Amylase levels were analyzed in two of them and were 10,300 U/L and 521 U/L, respectively.

Two non-diagnostic cases were positive for KRAS mutation with no gene fusions or copy number alterations. Both were interpreted as mucinous neoplasms (IPMN/MCNs) and their risk of progression to high-grade dysplasia/adenocarcinoma was interpreted as low. Ductal dilation was observed in one of these cases, while enhancing septations was observed on the other. The CEA (CEACAM5) level was low in one of them and undetectable in the other. CEA was studied in one both and was 235 ng/mL and 23 ng/mL, respectively. Amylase levels were not analyzed for these two patients.

One non-diagnostic case was positive for VHL mutation with no gene fusions or copy number alterations. The cyst was interpreted as SCA and the risk of progression was low. The CEACAM5 (CEA) level was undetectable. There were no significant findings on imaging. CEA level was not elevated, and the amylase levels were not studied.

Four non-diagnostic cases were negative for gene mutations, fusions, or copy number alterations and CEA (CEACAM5) level was analyzed and elevated in one (1445 gene expression unit [GEU]). The CEA and amylase levels were studied in two of these cases and was 1060 ng/mL and <0.5 ng/mL, <30 and 103 U/L, respectively.

Six cases were negative on cytologic evaluation with scant cellularity and/or benign pancreatic epithelium. Two of these cases were positive for KRAS and GNAS mutations

**Table 1:** Summary of cyst characteristics, cytologic evaluation, and PancreaSeq® results of our cohort.

| Patient number | Cyst Size (cm) and location | PancreaSeq® results                                 | PancreaSeq® interpretation | Risk of progression to high-grade dysplasia/adenocarcinoma | Cytologic interpretation | CEA level (ng/mL) | Amylase level (U/L) | CEACAM5 level (GEU) | MRI/MRCP                             |
|----------------|-----------------------------|---|----------------------------|--|--------------------------|-------------------|---------------------|---------------------|--------------------------------------|
| 1              | 3.7, Head                   | KRAS, GNAS mutation                                 | IPMN                       | Low  | Positive for MCN         | 89                | NA                  | Low                 | Enhancing septations, nodularity     |
| 2              | 6, Neck                     | KRAS mutation                                       | IPMN/MCNs                  | Low  | Non-diagnostic           | 23                | NA                  | Low                 | Ductal dilation, parenchymal atrophy |
| 3              | 3, Head                     | Negative  | Non-neoplastic cyst        | NA   | Positive for MCN         | 600               | NA                  | Low                 | Ductal dilation                      |
| 4              | 3, Body                     | KRAS mutation                                       | IPMN/MCNs                  | Low  | Negative                 | NA                | NA                  | Low                 | -                                    |
| 5              | 6.3, Head                   | KRAS mutation                                       | IPMN/MCNs                  | Low  | Positive for MCN         | 289               | <30                 | Low                 | Ductal dilation                      |
| 6#             | 2.4, Uncinate process       | KRAS, GNAS mutations, RNF43 copy number alterations | IPMN                       | Low  | Negative                 | 7354              | NA                  | Low                 | -                                    |
| 7              | 3.5, Body                   | Negative  | Non-neoplastic cyst        | NA   | Non-diagnostic           | <0.5              | 103                 | NA                  | Enhancing septations                 |
| 8*             | 4.8, Body                   | KRAS, GNAS mutation                                 | IPMN                       | Low  | Non-diagnostic           | 875               | 10300               | Low                 | Ductal dilation, parenchymal atrophy |
| 9              | 4.4, Tail                   | Negative  | Non-neoplastic cyst        | NA   | Non-diagnostic           | 1062              | <30                 | NA                  | -                                    |
| 10             | 2.7, Tail                   | KRAS, GNAS mutation                                 | IPMN                       | Low  | Non-diagnostic           | 691               | 521                 | Low                 | -                                    |
| 11             | 2, Neck                     | KRAS, TP53 mutation                                 | IPMN/MCNs                  | Elevated   | Atypical                 | NA                | NA                  | Low                 | Enhancing septations                 |
| 12             | 3.4, Tail                   | KRAS, GNAS mutation                                 | IPMN                       | Low  | Non-diagnostic           | 680               | NA                  | Low                 | -                                    |
| 13             | 2, Head                     | KRAS, GNAS mutation                                 | IPMN                       | Low  | Atypical                 | NA                | NA                  | Low                 | Calcifications                       |
| 14             | 2.6, Tail                   | Negative  | Non-neoplastic cyst        | NA   | Non-diagnostic           | NA                | NA                  | NA                  | -                                    |

(Contd...)

**Table 1: (Continued).**

| Patient number | Cyst Size (cm) and location | PancreaSeq® results  | PancreaSeq® interpretation | Risk of progression to high-grade dysplasia/adenocarcinoma | Cytologic interpretation | CEA level (ng/mL) | Amylase level (U/L) | CEACAM5 level (GEU) | MRI/MRCP  |
|----------------|-----------------------------|--|----------------------------|--|--------------------------|-------------------|---------------------|---------------------|---|
| 15             | 3.9, Head                   | Negative   | Non-neoplastic cyst        | NA   | Negative                 | 260               | NA                  | Low                 | Enhancing septations                              |
| 16             | 3.7, Head                   | KRAS, GNAS mutation  | IPMN                       | Low  | Negative                 | NA                | NA                  | Low                 | -   |
| 17*            | 4.8, Tail                   | KRAS, GNAS mutation  | IPMN                       | Low  | Positive for MCN         | 6417              | 1362                | Low                 | Enhancing septations, nodularity, ductal dilation |
| 18             | 2.7, Body                   | GNAS mutation, EML4/ALK fusion                               | IPMN                       | Low  | Positive for MCN         | 19                | NA                  | 221                 | Ductal dilation                                   |
| 19             | 2.5, Head                   | GNAS mutation, EML/4ALK fusion, RNF43 copy number alteration | IPMN                       | Low  | Positive for MCN         | NA                | NA                  | 3946                | Ductal dilation, nodularity                       |
| 20             | 2.2, Head                   | Negative   | Non-neoplastic cyst        | NA   | Non-diagnostic           | NA                | NA                  | 1445                | -   |
| 21             | 3.5, Neck                   | KRAS mutation  | IPMN                       | Low  | Positive for MCN         | 35955             | <30                 | 15630               | Enhancing septations                              |
| 22             | 2.1, Body                   | VHL mutation   | SCA                        | Low  | Non-diagnostic           | 4.6               | NA                  | Undetectable        | -   |
| 23             | 2, Uncinate process         | KRAS, GNAS mutation  | IPMN                       | Low  | Atypical                 | NA                | NA                  | 2534                | -   |
| 24             | 3.1, Tail                   | Negative   | Non-neoplastic cyst        | NA   | Atypical                 | <0.5              | NA                  | NA                  | Enhancing septations                              |
| 25             | 3.8, Head                   | KRAS, GNAS mutation  | IPMN                       | Low  | Atypical                 | 397               | NA                  | 600                 | Calcification, diffuse atrophy                    |
| 26             | 3.7, Uncinate process       | KRAS, GNAS mutation  | IPMN                       | Low  | Negative                 | 1592              | NA                  | 13692               | -   |
| 27             | 2, Body                     | Negative   | Non-neoplastic cyst        | NA   | Negative                 | 1.3               | 480                 | 748                 | -   |
| 28             | 3.1, Body                   | KRAS mutation  | IPMN/MCNs                  | Low  | Non-diagnostic           | 235               | NA                  | Undetectable        | Enhancing septations                              |

MCN: Mucinous cystic neoplasm, IPMN: intraductal papillary mucinous neoplasm, SCA: serous cystic neoplasm, NA: Not applicable, MRI: Magnetic resonance imaging, MRCP: Magnetic resonance cholangiopancreatography, CEA: Carcinoembryonic antigen, GEU: Gene expression unit. #Patient #6 died. \*Patients #8 and #17: Both had distal pancreatectomies and showed IPMN; the second patient (#17) also had focal high grade dysplasia



with no gene fusions or copy number alterations. Both cysts were interpreted as mucinous (IPMN) and their risk of progression was low. There was no duct dilation, enhancing septations, nodularity, or any other significant finding on imaging. The CEA (CEACAM5) level was elevated in one (13,692 GEU). The CEA level was reported for one of them and was 1592 ng/mL. Amylase levels were not reported for both cases.

One cytologically negative case was positive for KRAS and GNAS mutation and RNF43 copy number alteration. This cyst was interpreted as mucinous (IPMN) and the risk of high-grade dysplasia/adenocarcinoma was interpreted as low. There were no pathological findings on imaging. The CEA (CEACAM5) level was low. The CEA level was 7354 ng/mL, but the amylase levels were not studied for this case.

One of the cases that were negative on cytologic evaluation was positive for KRAS mutation with no gene fusions or copy number alterations. The type of cyst was interpreted as mucinous (IPMN), and the risk of high-grade dysplasia/adenocarcinoma was interpreted as low. No pathological imaging findings were observed. The CEA (CEACAM5) level was low. The CEA and amylase levels were not analyzed for this case.

Two cytologically negative cases were negative for any mutations, gene fusions, or copy number alterations and were interpreted as non-neoplastic. One demonstrated enhancing septations with radiologic evaluation. The CEA (CEACAM5) level was elevated in one of the cases (748 GEU). The CEA levels were 260 ng/mL and 1.3 ng/mL. Amylase levels were only reported for one of them and were 480 U/L.

Five cases were classified as atypical on cytologic evaluation. They mostly consist of rare abnormal epithelial cells that represent reactive/degenerative changes but not enough to classify as dysplasia/carcinoma cannot be excluded from the study. Three of them were positive for KRAS and GNAS mutations with no gene fusions or copy number alterations. On MRI/magnetic resonance cholangiopancreatography (MRCP), one of them had enhancing septations and one of the cases demonstrated scant, tiny, and patchy calcifications in the entire pancreas. The CEA (CEACAM5) level was elevated (600 GEU and 2534 GEU). The CEA level was 397 ng/mL in one case, but the Amylase levels were not analyzed.

One of the cases that were classified as atypical was positive for KRAS and TP53 mutation without any gene fusions or copy number alterations. On imaging, enhancing septations were noted. The CEA and amylase levels were not studied for this case.

Another case that was classified as atypical was negative for any gene fusion/mutations or copy number alterations and had enhancing septations on imaging. The CEA (CEACAM5) level was low. The CEA was <0.5 ng/mL.

Seven cases were positive for neoplasm and were suggestive for IPMN with mucinous epithelium present on cytologic evaluation. Two of these cases were positive for KRAS and GNAS mutations without any gene fusions or copy number alterations. On imaging, enhancing septations were observed in both while main duct dilation and peripheral nodularity was observed in just one of them. The type of cysts was interpreted as mucinous (IPMN) and the risk of high-grade dysplasia/adenocarcinoma was interpreted as low in both cases. The CEA (CEACAM5) level was low. The CEA levels were studied for both and were 6417 ng/mL and 89 ng/mL. Amylase level was studied for only one of them (1362 U/L).

Two of the cases that were classified as positive with cytology were positive for KRAS mutation with no gene fusions or copy number alterations. The type of cysts was interpreted as mucinous (IPMN/MCNs), and the risk of high-grade dysplasia/adenocarcinoma was interpreted as low for both cases. One demonstrated enhancing septations and the other demonstrated main duct dilation on imaging. The CEA (CEACAM5) level was elevated in one (15,630 GEU). The CEA levels were 35,955 ng/mL and 289 ng/mL, and amylase levels were <30 in both.

One of the cases that were classified as positive for MCN was positive for GNAS mutation and EML4/ALK fusion without any copy number alterations. The type of cyst was interpreted as mucinous (IPMN), but the risk of high-grade dysplasia/adenocarcinoma was reported as not well understood, due to the rare combination of GNAS mutations and ALK fusions. Ductal dilation was observed on MRI/MRCP. The CEA (CEACAM5) level was elevated at 221 GEU. The CEA was 19 ng/mL and amylase was not studied. Another cytologically positive case was positive for GNAS mutation, EML4/ALK fusion, and RNF43 copy number alterations. The cyst was interpreted as mucinous (IPMN), but the risk of high-grade dysplasia/adenocarcinoma was reported as not well understood, due to rare combination of GNAS mutations, RNF43 copy number alterations, and ALK fusions. It demonstrated enhancing septations and nodularity on MRI/MRCP. The CEA (CEACAM5) level was elevated (3946 GEU). The CEA and amylase were not studied. Finally, one of the cases that was classified as positive with cytologic evaluation was negative for gene fusions/mutations or copy number alterations with PancreaSeq analysis and was interpreted as non-neoplastic. There was mild main duct dilation on imaging. The CEA (CEACAM5) level was low. The CEA was estimated as 600 ng/mL.

All patients except for two (patients #8 and #17) did not have follow-up surgical resections. The two patients with follow-up resections had both distal pancreatectomies which showed IPMN, and only one of those had a focal high-grade dysplasia associated with the IPMN. All patients are alive and well, except for one patient (#6) who died of unrelated cause (sepsis).

## DISCUSSION

There is currently no imaging criteria or any other pre-operative diagnostic criteria to accurately differentiate between the wide range of underlying pathologies that pancreatic cysts can have, from benign to premalignant and malignant etiologies.<sup>[10]</sup> Imaging, cytologic evaluation, and biochemical analysis of the cyst fluid collected through EUS with FNA are the first-line diagnostic tools to determine the nature and the malignant characteristics of pancreatic cysts. Molecular analysis of cyst fluid with NGS is a useful second-line testing that is being used recently, as a supplementary diagnostic tool to better understand the characteristics and malignancy risk of the different types of pancreatic cysts.<sup>[11]</sup> It is an advantageous method for its capability to analyze even inadequate cellular specimens, as opposed to cytology, where one cannot reach a definitive diagnosis. It also offers a more conservative patient management and follow-up by analyzing genetic profile and assessing disease progression, in contrast to surgical intervention. So far, KRAS, GNAS, HRAS, VHL, RNF43, TP53, AKT-1, BRAF, CTNNB, PIK3CA, PTEN, SMAD4, and CDILN2A are some of the novel biomarkers that are reported in pancreatic cysts with molecular analysis.<sup>[12]</sup> Different mutational patterns of the more frequent pancreatic cysts and those that have progressed to adenocarcinoma have also been established by various sequencing studies.<sup>[4-7]</sup>

IPMNs and MCNs constitute mucinous pancreatic cystic neoplasms. IPMN, one of the most common mucinous pancreatic cystic neoplasms, has been demonstrated to have mutations in the KRAS (codons 12, 13 and/or 61), GNAS (codons 201 and 227), RNF43, BRAF, and CTNNB1 genes in over 95% of the cysts. MCNs also found to have KRAS, RNF43, and CTNNB1 mutations but they usually do not have GNAS and BRAF mutations, which makes them highly specific for IPMNs.<sup>[5-7]</sup> Some IPMNs and MCNs possess distinct genetic alterations which make them progress to malignancy. Genetic alterations in TP53, SMAD4, PIK3CA, PTEN, and AKT1 have been demonstrated to carry a high risk for transforming to high-grade dysplasia and early invasive pancreatic ductal adenocarcinoma in IPMNs and MCNs.<sup>[6]</sup> Correspondingly, PIK3CA, PTEN, SMAD4, and AKT1 alterations are reported in up to 60% of IPMNs with advanced neoplasia.<sup>[13,14]</sup> In a prospective study with 626 cyst fluid analysis, Singhi *et al.* demonstrated that 88% of IPMNs with advanced neoplasia carry KRAS and/or GNAS mutations in combination with alterations in PIK3CA, TP53, or PTEN. This combination had a sensitivity of 89% and a specificity of 100% for disease progression.<sup>[6]</sup>

In our cohort, three non-diagnostic, two negative, three atypical, and two positive for MCN cysts were positive for KRAS and GNAS mutation with no gene fusions or copy number alterations. Due to the combination of KRAS

and GNAS mutations, the type of cyst was interpreted as IPMN, in line with the reported literature.<sup>[7]</sup> Moreover, the risk for progression was interpreted as low for all. One cytologically negative case in our cohort was positive for KRAS and GNAS mutation and RNF43 copy number alteration with no gene fusions. It was interpreted as IPMN, since it is demonstrated that RNF43 copy number alterations can be observed in IPMNs,<sup>[5-7]</sup> and the risk of high-grade dysplasia/adenocarcinoma was interpreted as low. Two cytologically non-diagnostic, one negative, and two positive for neoplasm cysts were positive for KRAS mutation without any accompanying gene fusions/copy number alterations on PancreaSeq® analysis. All cases were interpreted as IPMN/MCNs with a low risk of progression, because as evident from the previous studies, KRAS mutation can be observed in both IPMN and MCNs.<sup>[5-7]</sup> CEA (CEACAM5) was analyzed in all and elevated in one case (15,630 GEU). CEA level was elevated in 3/5 (60%). One cytologically positive case was positive for GNAS mutation and ALK fusion with no copy number alterations and one case was positive for GNAS mutation, ALK fusion, and RNF43 copy number alteration. Both were interpreted as IPMN, but their risk of progression was interpreted as not well understood due to this combination's rareness in the reported literature. One atypical case was positive for KRAS and TP53 mutation with no gene fusions/copy number alterations and was interpreted as IPMN/MCNs with a high risk of progression. This finding supports the results of other similar studies, which all state that TP53 mutation accompanying KRAS mutation carries a high-risk for progression to high-grade dysplasia/progressive neoplasia.<sup>[7]</sup>

Another common type of neoplastic pancreatic cysts is SCAs, which have a very low malignant potential. Several studies demonstrated that they usually do not have KRAS, GNAS, or BRAF mutation. In contrast, 89–100% of SCAs carry VHL mutation or deletion, which is a distinctive genetic alteration for them.<sup>[4-6]</sup> In our study, one non-diagnostic case was interpreted as SCA on PancreaSeq® analysis. It harbored VHL mutation with no gene fusions/copy number alterations, in concordance with the literature, and the risk for progression was low. CEA (CEACAM5) expression level was undetectable. CEA level was low and amylase level was also not analyzed.

Analysis of CEA and amylase levels in EUS-FNA derived cyst fluid is currently being used as a part of diagnostic approach to pancreatic cysts and is helpful in understanding the nature of the lesion. Due to the retrospective nature of our study, we were able to gather CEA levels in most cases (20/28, 78.6%) but unable to report amylase levels in 20 cases because it was mostly not studied or not reported in our medical record system.

Analyzing CEA (CEACAM5) mRNA expression in cyst fluids is a useful tool for demonstrating CEA up-regulations.<sup>[15]</sup> Its

analysis with PancreaSeq® alongside amylase and CEA level analysis in cyst fluids can help in better understanding the pancreatic cystic lesions. In our cohort, CEA (CEACAM5) expression levels were analyzed and low in most non-neoplastic cysts but were elevated in two. It was elevated in six IPMN/MCNs cases, low in 13, and undetectable in one. It was also undetectable in our single SCA case.

Our cohort mostly consists of non-diagnostic cyst aspirates (35.7%); however, performing PancreaSeq® analysis with other diagnostic modalities (imaging findings, CEA and amylase levels) helped us clarify the type of cyst and its respective risk of progression to high-risk dysplasia/adenocarcinoma. Thus, it allowed us to guide a more proper patient management with a conservative approach to the cases with low risk of progression, and surgical management to the high-risk ones. Furthermore, four of our negative cysts and four of the atypical cysts were found to have distinct genetic alterations on molecular analysis, mostly consisting of KRAS and GNAS mutations with no gene fusions/copy number alterations. Although they had a low risk for progression, it helped us better understand the type of cyst and guided us through the next stages of patient management. These findings emphasize the importance of molecular analysis in pancreatic cysts management once more.

The limitations of the current study include the lack of surgical follow-up on the majority of the patients except for two, which preclude the ability to evaluate the accuracy of the PancreaSeq® assay.

## SUMMARY

Molecular testing in pancreatic cysts is an important diagnostic tool, especially when cytologic evaluation is non-diagnostic, such as in our study. Approaching pancreatic cyst aspirate analysis with a multimodal strategy that incorporates molecular testing yields valuable insight for accurate diagnosis and better patient management, especially when deciding between a conservative approach and surgical intervention.

## Acknowledgments

The authors express their sincere gratitude to Shanna M. Coletti and Christopher P. Marquez for helping with gathering the methodological information used in this study.

## COMPETING INTEREST STATEMENT BY ALL AUTHORS

The authors have no competing interests to declare.

## AUTHORSHIP STATEMENT BY ALL AUTHORS

All authors contributed equally to this work.

## ETHICS STATEMENT BY ALL AUTHORS

This work was exempted by our Institutional Review Board.

## LIST OF ABBREVIATIONS (In alphabetic order)

CEA - Carcinoembryonic antigen  
 EUS - Endoscopic ultrasound  
 FNA - Fine needle aspiration  
 IPMN - Intraductal papillary mucinous neoplasm  
 MCN - Mucinous cystic neoplasm  
 MRCP - Magnetic resonance cholangiopancreatography  
 MRI - Magnetic resonance imaging  
 NGS - Next generation sequencing  
 SCA - Serous cystadenoma  
 SPN - Solid pseudopapillary neoplasm

## EDITORIAL/PEERREVIEW STATEMENT

To ensure the integrity and highest quality of cytojournal publications, the review process of this manuscript was conducted under a **double-blind model** (the authors are blinded for reviewers and vice versa) through automatic online system.

## REFERENCES

1. Laffan TA, Horton KM, Klein AP, Berlanstein B, Siegelman SS, Kawamoto S, *et al.* Prevalence of unsuspected pancreatic cysts on MDCT. *AJR Am J Roentgenol* 2008;191:802-7.
2. Lee KS, Sekhar A, Rofsky NM, Pedrosa I. Prevalence of incidental pancreatic cysts in the adult population on MR imaging. *Am J Gastroenterol* 2010;105:2079-84.
3. Khalid A, Zahid M, Finkelstein SD, LeBlanc JK, Kaushik N, Ahmad N, *et al.* Pancreatic cyst fluid DNA analysis in evaluating pancreatic cysts: A report of the PANDA study. *Gastrointest Endosc* 2009;69:1095-102.
4. Springer S, Wang Y, Dal Molin M, Masica DL, Jiao Y, Kinde I, *et al.* A combination of molecular markers and clinical features improve the classification of pancreatic cysts. *Gastroenterology* 2015;149:1501-10.
5. Wu J, Jiao Y, Dal Molin M, Maitra A, de Wilde RF, Wood LD, *et al.* Whole-exome sequencing of neoplastic cysts of the pancreas reveals recurrent mutations in components of ubiquitin-dependent pathways. *Proc Natl Acad Sci U S A* 2011;108:21188-93.
6. Singhi AD, McGrath K, Brand RE, Khalid A, Zeh HJ, Chennat JS, *et al.* Preoperative next-generation sequencing of pancreatic cyst fluid is highly accurate in cyst classification and detection of advanced neoplasia. *Gut* 2018;67:2131-41.
7. Paniccia A, Polanco PM, Boone BA, Wald AI, McGrath K, Brand RE, *et al.* Prospective, multi-institutional, real-time next-generation sequencing of pancreatic cyst fluid reveals diverse genomic alterations that improve the clinical management of pancreatic cysts. *Gastroenterology* 2023;164:117-33.e7.
8. Saieg MA, Munson V, Colletti S, Nassar A. Impact of pancreatic cyst fluid CEA levels on the classification of pancreatic cysts



- using the Papanicolaou society of cytology terminology system for pancreaticobiliary cytology. *Diagn Cytopathol* 2017;45:101-6.
9. Pitman MB, Centeno BA, Ali SZ, Genevay M, Stelow E, Mino-Kenudson M, *et al.* Standardized terminology and nomenclature for pancreaticobiliary cytology: The Papanicolaou Society of Cytopathology Guidelines. *Cytojournal* 2014;11 Suppl 1:3.
  10. Garcea G, Ong SL, Rajesh A, Neal CP, Pollard CA, Berry DP, *et al.* Cystic lesions of the pancreas. A diagnostic and management dilemma. *Pancreatology* 2008;8:236-51.
  11. Al-Haddad MA, Kowalski T, Siddiqui A, Mertz HR, Mallat D, Haddad N, *et al.* Integrated molecular pathology accurately determines the malignant potential of pancreatic cysts. *Endoscopy* 2015;47:136-42.
  12. Singh H, McGrath K, Singhi AD. Novel biomarkers for pancreatic cysts. *Dig Dis Sci* 2017;62:1796-807.
  13. Schönleben F, Qiu W, Remotti HE, Hohenberger W, Su GH. PIK3CA, KRAS, and BRAF mutations in intraductal papillary mucinous neoplasm/carcinoma (IPMN/C) of the pancreas. *Langenbecks Arch Surg* 2008;393:289-96.
  14. Garcia-Carracedo D, Turk AT, Fine SA, Akhavan N, Tweel BC, Parsons R, *et al.* Loss of PTEN expression is associated with poor prognosis in patients with intraductal papillary mucinous neoplasms of the pancreas. *Clin Cancer Res* 2013;19:6830-41.
  15. Vuijk FA, de Muynck LD, Franken LC, Busch OR, Wilmink JW, Besselink MG, *et al.* Molecular targets for diagnostic and intraoperative imaging of pancreatic ductal adenocarcinoma

after neoadjuvant FOLFIRINOX treatment. *Sci Rep* 2020;10:16211.

**How to cite this article:** Ardor G, Hanna H, Ozalp B, Nassar A. Molecular analysis with pancreaseq® in evaluation and management of pancreatic cysts: A cohort of 28 patients. *Cytojournal* 2023;20:23.

HTML of this article is available FREE at:  
[https://dx.doi.org/10.25259/Cytojournal\\_28\\_2023](https://dx.doi.org/10.25259/Cytojournal_28_2023)

### The FIRST Open Access cytopathology journal

Publish in *Cytojournal* and RETAIN your copyright for your intellectual property

**Become Cytopathology Foundation Member** to get all the benefits

Annual membership fee is nominal US \$ 50 (US \$ 1000 for life)

**In case of economic hardship it is free**

For details visit <https://cytojournal.com/cf-member>

PubMed indexed

**FREE** world wide open access

**Online processing** with rapid turnaround time.

**Real time** dissemination of time-sensitive technology.

Publishes as many **colored high-resolution images**

Read it, cite it, bookmark it, use RSS feed, & many----



**CYTOJOURNAL**

[www.cytojournal.com](http://www.cytojournal.com)

Peer-reviewed academic cytopathology journal





# NextGen CelBloking™ Kits

**Frustrated with your cell blocks?  
We have a better solution!**

**Nano**

## Nano NextGen CelBloking™

Cell block kit to process single scattered cell specimens and tissue fragments of **any** cellularity.



**PATENT PENDING**



**Pack #1**



**Pack #2**

**Micro**

## Micro NextGen CelBloking™

For cellular specimens (more than 1 ml concentrated specimen with Tissuecrit more than 50%)



**PATENT PENDING**



**Pack #1**



**Pack #2**