

Quiz Case

Unusual case of parietal scalp swelling without palpable swelling in head and neck region

Priyanka Gautam, MD¹, Anshi Singh, MD¹, Vikas Shrivastava, MD¹, Divya Singh, MD¹, Mukul Singh, MS², Brijnandan Gupta¹

¹Department of Pathology, AIIMS, Gorakhpur, Uttar Pradesh, India.

²Department of Surgery, AIIMS, Gorakhpur, Uttar Pradesh, India.



***Corresponding author:**

Brijnandan Gupta,
Department of Pathology,
AIIMS, Gorakhpur,
Uttar Pradesh, India.

brij9890470@gmail.com

Received: 03 August 2022

Accepted: 31 October 2022

Published: 04 September 2023

DOI

10.25259/Cytojournal_26_2022

Quick Response Code:



A 73-year-old woman presented with the swelling in the left parietal region of the scalp, measuring 3 × 3 cm, which was cystic in consistency, and the overlying skin was normal without any palpable swelling in head and neck region. Clinical picture, contrast-enhanced computed tomography (CECT), and cytomorphology of fine-needle aspirate are shown in Figure 1.

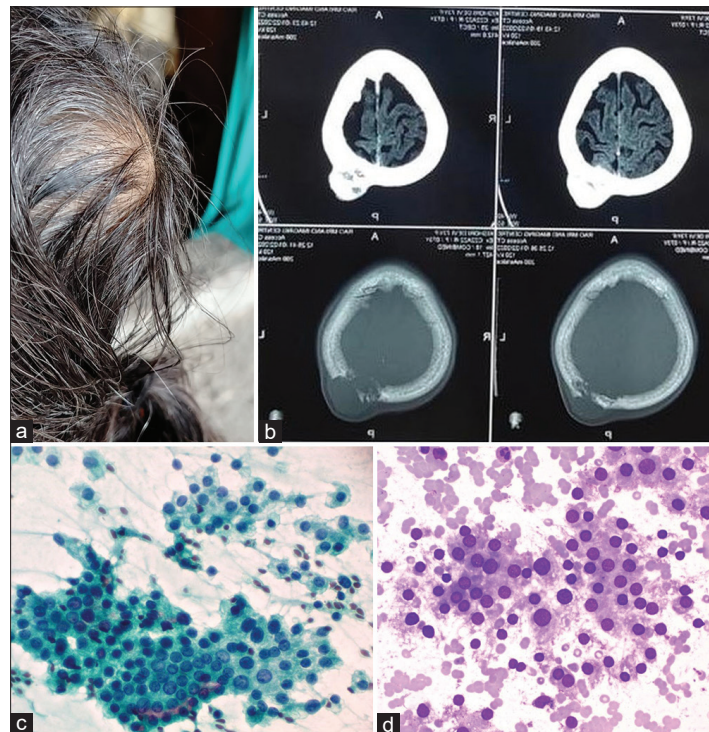


Figure 1: (a) Swelling over the left parietal scalp region; (b) contrast-enhanced computed tomography brain shows destructive mildly enhancing bony mass lesion; (c) aspirate from scalp swelling showing round cells with moderate amount of cytoplasm in sheets and groups with mild nuclear atypia (× 400, Papanicolaou stain); and (d) round cells arranged in small groups and clusters with central nuclei and moderate amount of granular cytoplasm (×400, May-Grunwald-Giemsa stain).

QUESTION 1

What is your most probable diagnosis?

- Metastatic renal cell carcinoma
- Primary adnexal tumor of skin with apocrine differentiation
- Granular cell tumor
- Metastatic Hurthle cell carcinoma

ANSWER

d. Metastatic Hurthle cell carcinoma.

The scalp swelling was [Figure 1a] on CECT brain revealed a destructive, mildly enhancing bony mass lesion with intra- and extra-cranial extension in the left parietal bone [Figure 1b]. The aspirate from scalp swelling of moderate cellularity showing round cells with central nucleus with nuclear dysplasia in the form of high nucleocytoplasmic ratio, nuclear enlargement, mild-to-moderate pleomorphism, and binucleation [Figures 1c, d and 2a, b]. In addition, some of the groups of cells also had presence of fire flares. The thyroid function test was within normal limits. No mass lesion was seen in kidneys on ultrasound. CECT neck showed few hypodense and calcified nodules in bilateral thyroid lobes. Ultrasound-guided aspirate from thyroid showed similar morphology as seen in scalp swelling [Figure 3a and b]. Final diagnosis was metastatic Hurthle cell carcinoma (HCC) of thyroid.

QUESTION 2

Who gave the description of Hurthle cells?

- Max Askanazy
- Karl Hurthle
- James Ewing

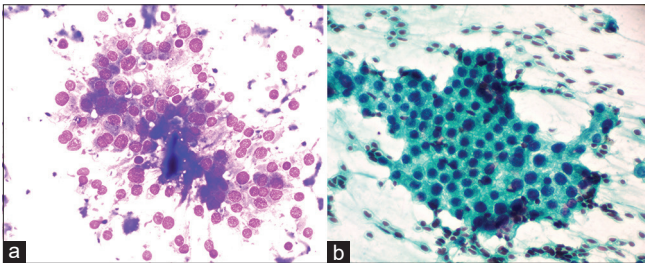


Figure 2: (a) May-Grunwald-Giemsa stained smear from scalp swelling showing the cohesive sheet of round cells with large central nuclei and moderate granular cytoplasm. Occasional binucleation also noted ($\times 400$) and (b) Papanicolaou stained smear showing round cells with moderate amount of granular cytoplasm in sheet with well-defined cell border ($\times 400$).

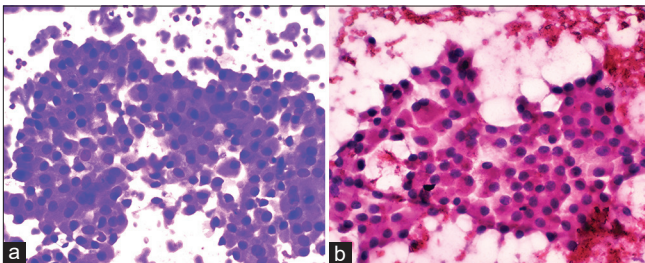


Figure 3: (a and b) Aspirate from thyroid showing the sheet of Hurthle cells with moderate amount of granular cytoplasm in sheet with well-defined cell border with central round nucleus and occasional binucleation ($\times 400$).

ANSWER

a. Max Askanazy.

HCC is a rare differentiated thyroid carcinoma of follicular origin, and it accounts for approximately 3–7% of all thyroid carcinomas.^[1] Max Askanazy, in 1898, described the Hurthle cells/Oncocytic cells in Graves' disease and Karl Hurthle described the C cells. James Ewing, in 1919, wrote the textbook "Neoplastic Diseases," described large, granular eosinophilic cells in thyroid carcinoma, and named them Hurthle cells of the thyroid alveoli. Since then, the "Hurthle cell" term has been used in the literature for the cells that were originally described by Max Askanazy, and it is a misnomer.^[2]

QUESTION 3

In the recent, the World Health Organization (WHO) classification of Tumors of Endocrine Organs published in 2017, how the HCC is classified?

- Variant of follicular carcinoma
- Separate entity

HCC has traditionally been classified as a variant of follicular carcinoma of the thyroid, but it was reclassified as a separate entity under the differentiated thyroid carcinomas in the 4th WHO classification of Tumors of Endocrine Organs in 2017, because it has a distinct clinical presentation, pathological features, and genetic profile.^[3] The present case is being reported due to the rarity of HCC in the thyroid and even rarer is its primary presentation as scalp swelling without any palpable mass in the thyroid.

BRIEF REVIEW OF THE TOPIC

Hurthle cells are also known as oncocytic/oxyphilic/eosinophilic cells. Hurthle cell change is observed in a variety of thyroid entities ranging from benign to malignant (including lymphocytic/Hashimoto thyroiditis, nodular goiter, long-standing chronic hyperthyroidism, Hurthle cell adenoma, and HCC), and it is not specific to any single entity.^[4] Hurthle cell tumors with malignant behavior show metastasis to the lungs, bones, lymph nodes, and brain.^[5] Bone metastasis has been reported in 10–40% of cases, with skull bone metastases only in 2.5–5.8% of cases.^[6] Lymph node metastasis is also observed in various studies, ranging from 9% to 20%.^[7] Sometimes, the primary presentation of thyroid carcinoma is a metastatic lesion, and the present case is one such rare example. If the cytomorphology shows a follicular pattern along with the classic malignant nuclear features in fine-needle aspiration (FNA) of metastatic sites, diagnosis of HCC on FNA is also possible. HCC can be misdiagnosed as some oncocytic neoplasms from other organs are also present with Hurthle/oncocytic cells with

granular cytoplasm, central nucleus, and bland chromatin. In such cases, it is imperative to take into consideration the other clinical and radiological features before making a definitive diagnosis. In cutaneous metastatic lesions, apocrine cells of sweat glands, granular cell tumors, and adnexal tumors of skin with apocrine differentiation may create confusion with Hurthle cells.^[8] Granular cell tumor, on cytology, shows tumor cells predominantly in cohesive/syncytial pattern, as well as scattered singly with ill-defined abundant granular cell borders. Tumor cell nuclei show pleomorphism ranging from round/oval to spindle cells. These cells are slightly smaller in size compared to cells of HCC and tumor cells of HCC have well-defined cytoplasm.^[9] Cytomorphology of metastatic renal cell carcinoma may show round to oval tumor cells in clusters, sheets, acini, and papillary fragments with pale to clear foamy and vacuolated cytoplasm. Some of the cells may show adherence to endothelial cells. There can be mild-to-moderate cellular and nuclear pleomorphism. Foamy cytoplasm on cytology in some cases can help it to differentiate from HCC. However, ancillary studies and radiology are required for making a definite diagnosis.^[10] Primary adnexal tumor of skin includes clear cell hidradenoma which shows biphasic cell population comprising of round to polygonal cells with eosinophilic cytoplasm and vesicular nuclei; other population of cells include clear cells containing glycogen with eccentric nuclei.^[10] HCC is usually treated with total thyroidectomy and skull metastasis by excision of the lesion.^[6] However, there are no consistent guidelines or recommendations for the treatment of skull metastasis.^[6] Total surgical clearance of foci of tumor can be achieved with total thyroidectomy and follow-up of the patient for recurrence or metastasis can be done using thyroglobulin marker.^[6]

SUMMARY

As discussed in the present case, HCC can present as an isolated metastatic disease without palpable thyroid swelling. In such cases, cytomorphological features can point toward a possible primary in the thyroid and lead to an accurate and timely diagnosis. The case also highlights the importance of cytology, radiology, as well as clinical features to arrive at a definitive diagnosis and appropriate treatment in such rare cases.

COMPETING INTERESTS STATEMENT BY ALL AUTHORS

The authors declare that they have no competing interests.

AUTHORSHIP STATEMENT BY ALL AUTHORS

Each author has participated sufficiently in the work and takes public responsibility for appropriate portions of the

content of this article. All authors read and approved the final manuscript. Each author acknowledges that this final version was read and approved.

ETHICS STATEMENT BY ALL AUTHORS

As this is case without identifiers, our institution does not require approval from the Institutional Review Board (IRB).

LIST OF ABBREVIATIONS

CECT – Contrast-Enhanced Computed Tomography
HCC – Hurthle Cell Carcinoma
WHO – World Health Organization

EDITORIAL/PEER REVIEW STATEMENT

To ensure the integrity and highest quality of CytoJournal publications, the review process of this manuscript was conducted under a **double-blind model** (authors are blinded for reviewers and *vice versa*) through automatic online system.

REFERENCES

1. Harel G, Hadar T, Segal K, Levy R, Sidi J. Hurthle cell carcinoma of the thyroid gland. A tumor of moderate malignancy. *Cancer* 1986;57:1613-7.
2. Caturegli P, Ruggere C. Karl Hurthle! Now, who was he? *Thyroid* 2005;15:121-3.
3. Lloyd R, Osamura R, Kloppel G, Rosai J. WHO Classification of Tumours of Endocrine Organs. 4th ed. Lyon: International Agency for Research on Cancer; 2017.
4. Pu RT, Yang J, Wasserman PG, Bhuiya T, Griffith KA, Michael CW. Does Hurthle cell lesion/neoplasm predict malignancy more than follicular lesion/neoplasm on thyroid fine-needle aspiration? *Diagn Cytopathol* 2006;34:330-4.
5. Stojadinovic A, Hoos A, Ghossein R, Urist MJ, Leung DH, Spiro RH, *et al.* Hurthle cell carcinoma: A 60-year experience. *Ann Surg Oncol* 2002;9:197-203.
6. Wong GK, Boel R, Poon WS, Ng HK. Lytic skull metastasis secondary to thyroid carcinoma in an adolescent. *Hong Kong Med J* 2002;8:149-51.
7. Coca-Pelaz A, Rodrigo JP, Shah JP, Sanabria A, Al Ghuzlan A, Silver CE, *et al.* Hurthle cell carcinoma of the thyroid gland: Systematic review and meta-analysis. *Adv Ther* 2021;38:5144-64.
8. Lallu S, Naran S, Bethwaite P. Fine needle aspiration cytology of unsuspected metastatic hurthle cell carcinoma of the thyroid and its pitfalls: A report of two cases. *Diagn Cytopathol* 2007;35:439-43.
9. Chen Q, Li Q, Guo L, Li S, Jiang Y. Fine needle aspiration cytology of a granular cell tumor arising in the thyroid gland: A case report and review of literature. *Int J Clin Exp Pathol* 2014;7:5186-91.

10. Chandra S, Raina MK, Shukla SK, Kusum A, Nautiyal V. Diagnostic rescue of a silent scalp swelling by fine-needle aspiration. *Cytojournal* 2019;16:19.

How to cite this article: Gautam P, Singh A, Shrivastava V, Singh D, Singh M, Gupta B. Unusual case of parietal scalp swelling without palpable swelling in head and neck region. *CytoJournal* 2023;20:33.

HTML of this article is available FREE at:
https://dx.doi.org/10.25259/Cytojournal_26_2022

The **FIRST** **Open Access** cytopathology journal

Publish in *Cytojournal* and **RETAIN** your *copyright* for your intellectual property

Become Cytopathology Foundation Member to get all the benefits
Annual membership fee is nominal US \$ 50 (US \$ 1000 for life)

In case of economic hardship it is free

For details visit <https://cytojournal.com/cf-member>

PubMed indexed

FREE world wide **open access**

Online processing with rapid turnaround time.

Real time dissemination of time-sensitive technology.

Publishes as many **colored high-resolution images**

Read it, cite it, bookmark it, use RSS feed, & many----



CYTOJOURNAL

www.cytojournal.com

Peer -reviewed academic cytopathology journal

