



Editor-in-Chief:

Miaoqing Zhao, PhD, MD (Shandong First Medical University, Jinan, China)

He Wang, MD, PhD (Yale University School of Medicine, New Haven, Connecticut, USA)

Founding Editor & Editor-in-chief Emeritus:

Vinod B. Shidham, MD, FIAC, FRCPath (WSU School of Medicine, Detroit, USA)

Research Article

# Expression of minichromosome maintenance proteins in the exfoliated cells supplement sputum cytology in the diagnosis of lung cancer

Neeraja Panakkal, MSc<sup>1,2</sup>, Asha Lekshmi, PhD<sup>1</sup>, Jagathnath Krishna K. M., PhD<sup>3</sup>, Veena Vemaddevan Saraswathy, PhD<sup>4</sup>, Kunjuraman Sujathan, PhD<sup>1</sup> 

<sup>1</sup>Division of Cancer Research, Regional Cancer Centre, Thiruvananthapuram, <sup>2</sup>Manipal Academy of Higher Education, Manipal, <sup>3</sup>Division of Cancer Epidemiology and Biostatistics, Regional Cancer Centre, <sup>4</sup>Division of Pathology, Regional Cancer Centre, Thiruvananthapuram, Kerala, India.



\*Corresponding author:

Kunjuraman Sujathan,  
Division of Cancer Research,  
Regional Cancer Centre,  
Thiruvananthapuram, Kerala,  
India.

[ksujathan@gmail.com](mailto:ksujathan@gmail.com)

Received: 26 June 2024

Accepted: 28 November 2024

Published: 31 December 2024

DOI

[10.25259/Cytojournal\\_115\\_2024](https://doi.org/10.25259/Cytojournal_115_2024)

Quick Response Code:



Supplementary material

available at: [https://dx.](https://dx.doi.org/10.25259/Cytojournal_115_2024)

[doi.org/10.25259/](https://doi.org/10.25259/Cytojournal_115_2024)

[Cytojournal\\_115\\_2024](https://doi.org/10.25259/Cytojournal_115_2024)

## ABSTRACT

**Objective:** Sputum cytology is recognized as a straightforward and noninvasive way to diagnose lung cancer, although its clinical utility has not yet been investigated. The objective of the study was to detect and classify cancerous cells in sputum by examining their expression of minichromosome maintenance proteins (MCM2 and MCM7). In addition, the study attempted to evaluate these proteins' potential as biomarkers of lung cancer lesions and their relationships with clinicopathological characteristics.

**Material and Methods:** MCM2 and MCM7 expression in sputum samples was evaluated using immunocytochemistry in sputum cell blocks ( $n = 97$ ), and their correlation with clinicopathological features was examined. Diagnostic performance was evaluated as a function of sensitivity and specificity.

**Results:** Immunoexpression of MCM2 and MCM7 was confined to the nuclei of malignant cells alone, suggesting its potential as a differential diagnostic marker. They showed significant correlations with tumor cytology ( $P < 0.001$ ), while MCM7 alone exhibited a significant correlation with tumor stage ( $P = 0.014$ ). The overexpression of these markers was notably pronounced in lung adenocarcinoma compared to other subtypes. In terms of characterizing malignant cells, MCM7 protein demonstrated the highest sensitivity at 92% with an area under the curve (AUC) of 0.961, whereas MCM2 had a sensitivity of 80% and AUC of 0.901.

**Conclusion:** This study presents the inaugural use of MCM7 immunocytochemistry on exfoliated cells in sputum samples, proposing that analyzing immunocytochemical markers in sputum could serve as a cost-effective approach for diagnosing lung cancer. Integrating these assessed markers into routine cytopathology laboratories could augment traditional morphological evaluations, thereby improving the sensitivity of sputum cytology.

**Keywords:** Lung neoplasms, Minichromosome maintenance proteins, Sputum, Immunocytochemistry

## INTRODUCTION

Lung cancer is the leading cause of cancer-related deaths worldwide, with approximately 2.2 million new cases and 1.8 million deaths reported in 2020.<sup>[1]</sup> It represents a group of heterogeneous entities in terms of histology and molecular profile.<sup>[2]</sup> Primary lung cancers are classified into two main histological types: Non-small cell lung carcinoma (NSCLC) and small cell lung carcinoma (SCLC), representing 85% and 15% of all cases, respectively. NSCLC

can be further divided into subtypes, including lung adenocarcinoma (LUAD), lung squamous cell carcinoma (LUSC), and large-cell carcinoma.<sup>[2]</sup> Low survival rates for both NSCLC and SCLC have been linked to late diagnosis and subpar response to conventional chemotherapy and radiation. This emphasizes how crucial it is to identify novel biomarkers and possible therapeutic targets to enhance the prognosis of lung cancer patients. Despite all the NSCLCs have molecularly characterized pre-invasive lesions, they are often asymptomatic and undetectable by the current noninvasive methods. Lots of researches are in progress to identify lung cancer early detection methods. Unfortunately, most of them are imaging technology-based ones and low-dose computed tomography has been identified as a sensitive technique for the early detection of stage 0 lung cancers, and this has been suggested as a screening method. Sputum is a desirable prospective source of lung cancer biomarkers due to its noninvasive nature and propensity to represent the site of injury.<sup>[3]</sup> Various research teams have examined sputum cytology as a potential technique for early lung cancer detection.<sup>[4]</sup> However, none of these studies were found fruitful as sputum cytology suffers a lack of sensitivity to be used for early detection. The reason for the lower sensitivity was the lack of adequate laboratory techniques to fish out the whole cell content without any morphological distortion. Furthermore, it was challenging to distinguish between reactive benign cells and malignant cells due to the morphological changes brought about by laboratory processing techniques, as well as the inherent reactive and degenerative changes caused by the exfoliated cells clogged on mucus. There were no other methods available to enhance the morphological assessment. Hence, the cytologist used to report the same as to contain atypical cells. An average of 20–30% of sputum samples are being reported to have such atypical cells without a definite diagnosis in the pathology division of our hospital.<sup>[5]</sup> However, now, the liquid-based cytology (LBC) methods offer better technology to extract the whole cell content of sputum samples without much distortion. Furthermore, there are ancillary techniques to supplement the conventional method. We recently developed a modified sputum processing method that preserves cells for additional molecular analyses and enables the characterization of specific proteins to complement conventional morphological evaluation.<sup>[5]</sup>

Initiating DNA replication and cell proliferation requires the presence of minichromosome maintenance proteins (MCMs), a group of proteins involved in minichromosome maintenance. They are referred to as the DNA replication-licensing factors by joining the origin recognition complex with additional licensing factors to form the pre-replicative complex, which regulates DNA replication and only permits it to take place once every cell cycle.<sup>[6]</sup> In addition, they play a role in the cohesion, condensation, transcription, and

recombination of DNA molecules and are necessary for replication elongation. A trimeric core complex made up of the MCM4, MCM6, and MCM7 subunits is coupled with a peripheral dimer of the MCM3 and MCM5 to produce a hexameric MCM complex.<sup>[7]</sup> Throughout the cell cycle, all MCM proteins are invariably present in the nucleus. Because MCM proteins are essential for initiating DNA replication in proliferating cells but are absent in quiescent cells, they serve as reliable markers of cell proliferation.<sup>[8]</sup> In a number of cancers, such as lung, ovarian, colon, urothelial, and oral cancers, the expression level of MCMs has been linked to important clinicopathological parameters and demonstrated considerable diagnostic and prognostic value.<sup>[9–11]</sup> In addition, MCMs may serve as indicators for recurrent and precancerous illnesses, according to a number of lines of research, and abnormal expressions of MCMs have been linked to the onset and development of several cancers.<sup>[9,12]</sup> Particularly in humans and other eukaryotes, MCM2 and MCM7 are engaged in a variety of biological processes.<sup>[13]</sup> MCM2 is highly expressed during the proliferation of premalignant lung cells and is considered a potential diagnostic marker for the early detection of malignant pulmonary lesions, whereas MCM7 expression in bronchial brushings of NSCLC patients is associated with prognosis.<sup>[14]</sup> However, the application of MCM7 protein evaluation in sputum cytology still remains unfathomed.

The current work sought to characterize malignant cells in sputum using MCM2 and MCM7. Through the identification of these proteins, the research aimed to improve traditional sputum cytology. Furthermore, the expression of these proteins was investigated in relation to various clinicopathological characteristics.

## MATERIAL AND METHODS

### Subjects

A cohort of 97 patients who were referred from the Medical College Hospital and Sanatorium for Chest Disease in 2019 and 2020 served as the study's subjects. The individuals ranged in age from 39 to 79 years old and included both genders. The selection of subjects was based on:

### Inclusion criteria

1. Adults aged 18 years and above
2. Positive sputum cytology for malignancy confirmed by biopsy
3. Negative sputum cytology findings
4. Complete clinical diagnoses, including, at a minimum, negative chest X-rays
5. Patients capable of producing adequate sputum samples for cytological analysis
6. Patients who provided informed consent for participation.

### Exclusion criteria

1. Patients who have received prior treatment for lung cancer
2. Patients with other significant pulmonary diseases, such as tuberculosis or pulmonary fibrosis
3. Sputum samples that are insufficient in quantity or quality (fewer than five pulmonary macrophages)
4. Patients with a history of other malignancies.

19 LUAD, 23 LUSC, 10 NSCLC, 24 atypical, and 21 with negative for malignant cells (NMCs) are among the lesions that have been histologically shown to be malignant. The selection of these cases was predicated on the sufficiency of their sputum samples and positive clinical follow-up information. Of them, 32 cases belonged to stage III, 22 to stage IV, and 22 to stage II. Clinical complaints and additional clinico-pathological data were collected from patient records and documented on a proforma. Informed consent was obtained from each participant following approval of the study by the institutional review board and human ethics committee (HEC No. 13/019). The study was conducted in accordance with the Declaration of Helsinki.

### Sample collection and processing

Early morning sputum for 3 consecutive days was obtained in the sample bottle provided to the patients. Post-bronchoscopic samples were collected from patients selected for bronchoscopy. Ninety-seven samples of sputum have been selected for the study. Cytologically positive sputum samples with biopsy confirmation of malignancy were taken as positive, and subjects with negative cytology and complete clinical diagnosis, which includes, as a minimum, negative chest X-rays were taken as negative. All three samples of each patient preserved at 4°C were pooled, homogenized, and treated with BD Cytorich® red Preservative (#491336, Becton, Dickinson and Company, USA). After vortexing the samples with twice the volume of red preservative, they were left for half an hour. The combined sample was transferred to a 50 mL centrifuge tube, vortexed again, and centrifuged for 5 min at 600 g. The resulting cell pellet was re-suspended in buffer solution, vortexed, and centrifuged again for 10 min at 800 g. This pellet was then used for cell block preparation.<sup>[5]</sup> Samples for immunocytochemistry have been selected based on the cytopathological analysis for sample adequacy and the presence of representative cells.

### Immunocytochemistry

Immunocytochemistry was carried out in 5 micron sections from cell blocks using MACH4 Universal horseradish peroxidase (HRP) polymer detection system (#BRR4012, Biocare Medical, Pacheco, CA 94553, USA). The sections were deparaffinized with three changes of xylene (CAS no: 1330-

20-7, Sigma -Aldrich Chemical Pvt. Limited Industrial Area, Anekal Taluka Plot No 12, Bangalore, India), each for 10 min, followed by rehydration through decreasing concentrations of alcohol and a final rinse in water, each step lasting 5 min. Cell permeability was enhanced by treating with 4 mM sodium deoxycholate (#RM131, HiMedia, HiMedia Laboratories Pvt. Limited, Maharashtra, India) for 15 min. Antigen retrieval was carried out using the microwave method with sodium citrate buffer (pH 6.0) at 700 W for 15 min. After washing the slides for 5 min in deionized water, the endogenous peroxidase activity was blocked using Peroxidized 1 (#PX968H, Biocare Medical, Pacheco, CA 94553, USA) for 5 min. Slides were washed twice in TBST (TRIS-buffered saline-Tween20 [#MB067, HiMedia, HiMedia Laboratories Pvt. Limited, Maharashtra, India]). The samples were then incubated with a background punisher (#BRR974H, Biocare Medical, Pacheco, CA 94553, USA) for protein block for 5 min and then washed twice in TBST for 5 min each. Sections were treated with primary antibody overnight at 4°C. Mouse monoclonal primary antibodies MCM2 (# sc-373702, Santha Cruz Biotechnology, Texas 75220, USA) and MCM7 (# sc-65469, Santha Cruz Biotechnology, Texas 75220, USA) were used. Antibodies were used in a dilution of 1:25. After washing in TBST, the sections were incubated with MACH4 mouse probe (#BRR534DH, Biocare medical, Pacheco, CA 94553, USA) for 30 min at room temperature and rinsed in TBST twice for 5 min each. The sections were incubated for 30 min at room temperature with MACH4 HRP polymer (#BRR534BH, Biocare Medical, Pacheco, CA 94553, USA) and rinsed twice TBST for 5 min each. Peroxidase activity was developed using 3, 3' Diaminobenzidine (#BRR900AC, Biocare Medical, Pacheco, CA 94553, USA). Slides were rinsed in deionized water and then counterstained with Harris Hematoxylin (GRM9946, Biocare Medical, Pacheco, CA 94553, USA) followed by bluing in running tap water, dehydrated in ascending grades of alcohol for 5 min each, then cleared in three changes of xylene and mounted in dibutylphthalate polystyrene xylene (#100579, Sigma-Aldrich, Merck, Mumbai, India).

The immunocytochemically stained slides were analyzed using a Leica light microscope. Positive control slides were first screened to recognize the pattern of expression. Each of the immunostained slides was initially screened at ×10 magnification followed by ×20 magnification for grading the different intensities of expression pattern. The intensity of expression patterns was scored as mild, moderate, and intense on a zero to 3+ scale. H-scores, ranging from 0 to 300, were calculated by multiplying the staining intensity (0–3) by the percentage of positive cells (0–100%). An H-score of 30 or higher was considered positive. Two of the investigators carried out the immunoscore separately. Rescoring was done on samples if there was any disagreement regarding immunoscores. Images were captured with a camera system

attached to the microscope, utilizing the Leica application software (Leica Application LA Suite V3 [LASV3.8], Leica Microsystems, Danaher, Germany).

### Statistical analysis

The statistical analysis for the study was conducted using the Statistical Package for the Social Sciences software (version 28.0, IBM Corporation; Armonk, NY, USA). Descriptive statistics were employed to summarize the demographic and clinical characteristics of the study participants, with frequencies and percentages applied to the categorical variables. When the theoretical frequency  $T \geq 5$  and sample size  $N \geq 40$ , Chi-square test was used; when  $1 \leq T < 5$  and  $N \geq 40$ , continuity-corrected Chi-square was used for the test; and when  $T = 0$ , Fisher Freeman Halton exact test was used. To evaluate the diagnostic performance of each marker, with the cytology report as the gold standard, sensitivity and specificity were calculated, along with positive predictive value (PPV) and negative predictive value. To assess the diagnostic efficacy of the sputum markers, receiver operating characteristic (ROC) curve was generated and the area under the curve (AUC) was calculated. An AUC value closer to 1 indicates a better diagnostic performance, with  $AUC > 0.9$  indicating high accuracy. A  $p$ -value threshold of  $< 0.05$  was set for all statistical tests. Results with  $P$ -values below this threshold were considered statistically significant.

## RESULTS

### Baseline characteristics and expression patterns of MCM proteins

The study included 97 subjects, comprising 81.4% males (79 out of 97) and 18.6% females (18 out of 97). Among these subjects, 64.9% (63 out of 97) were smokers. The clinicopathological features of the 97 study subjects provided important insights into the association between MCM2 and MCM7 protein expression and different lung cancer subtypes. MCM7-negative and MCM7-positive groups did not exhibit a significant difference with respect to age ( $P = 0.540$ ) and sex ( $P = 0.246$ ) in the different subgroups. Similarly, MCM2 and MCM7 expression did not show significant variation between smokers and non-smokers ( $P = 0.785$  and  $P = 0.799$ , respectively). Of the 34 non-smokers, 22 were positive for MCM2, while 24 were positive for MCM7. Similarly, among smokers (63 subjects), 39 were MCM2 positive, and 46 were MCM7 positive, suggesting that smoking status does not have a strong association with MCM protein expression. Among the 19 patients with LUAD, 16 were positive for MCM2, and all were positive for MCM7, showing a strong association ( $P < 0.001$ ) for both markers. All 23 LUSC cases were positive for both MCM2 and MCM7, further reinforcing the diagnostic relevance of these markers in this

subtype ( $P < 0.001$  for both). Among the 10 NSCLC cases, all were positive for both MCM2 and MCM7 ( $P < 0.001$ ), indicating that MCM proteins are strongly expressed in this subtype as well. Out of 24 atypical cases, 12 were positive for MCM2, and 18 were positive for MCM7, with a significant correlation for MCM7 ( $P < 0.001$ ). The total sample size for the clinical stage analysis is 76 because the 21 samples without malignant cells were not assigned a clinical stage. Among the 22 patients in Stage II, 17 were positive for MCM2 and MCM7, though only MCM7 expression reached statistical significance ( $P = 0.014$ ). This indicates that MCM7 might be more sensitive for detecting cancer at earlier stages. Of the 32 patients in Stage III, 24 were MCM2 positive and 31 were MCM7 positive. While MCM2 did not show significant correlation ( $P = 0.361$ ), MCM7 was strongly associated with tumor stage, suggesting that MCM7 expression increases with disease progression. In Stage IV patients (22 total), 20 were positive for MCM2, and all were positive for MCM7, showing a stronger correlation between MCM7 and advanced-stage disease ( $P = 0.014$ ). These findings suggest that MCM7 may be a more versatile marker, providing insights into both the type and progression of the tumor as shown in Table 1.

Due to the limited sample size within each tumor subtype, characterizing and comparing them individually with clinicopathological features would likely yield statistically insignificant results. Hence, such comparisons were avoided. Instead, a cumulative analysis was performed across all subtypes, examining protein expressions to ensure more robust and meaningful insights.

### Intensity of MCM expression in different tumor types

The expressions of MCM2 and MCM7 were confined exclusively to the nuclei, with no background staining observed. A positive MCM2 marker was detected in 62.9% of the subjects (61 out of 97), while overexpression of MCM7 was observed in 72.2% of the subjects (70 out of 97). The intensity of expression varied among different tumor types. Notably, LUAD samples exhibited the highest expression of MCM7, with a mean H-score of 184.3 [Table 2 and Supplementary Figure 1].

The patterns of MCM2 and MCM7 expression showed varying degrees of intensity, including mild, moderate, and dense expressions in tumor cell nuclei. With a few exceptions, where weak localized expression was detected in a minimal set of cells, neither marker was expressed in samples that were negative for malignancy [Figure 1]. Hematoxylin and eosin (H&E) staining demonstrated the cellular morphology of LUAD, LUSC, NSCLC, atypical cells, and non-malignant cells ([Figure 1a, d, g, j, m], respectively). Moderate nuclear expression of MCM2 [Figure 1b] and dense nuclear expression of MCM7 [Figure 1c] were observed in adenocarcinoma cells. In squamous cell carcinoma cells,

**Table 1:** Association of MCM2 and MCM7 expression with diverse clinicopathological characteristics in lung cancer.

Clinicopathological features	n (97)	MCM2 protein expression status			P-value	MCM7 protein expression status			P-value
		Negative	Positive	Test Statistic		Negative	Positive	Test Statistic	
Mean age (SD)		60.69 (9.19)	61.49 (7.582)	-0.462	0.645	60.37 (9.96)	61.51 (7.43)	-0.615	0.540
Gender									
Male	79	27	52	1.573	0.210	20	59	1.344	0.246
Female	18	9	9			7	11		
Smoking status									
Non-Smoker	34	12	22	0.074	0.785	10	24	0.065	0.799
Smoker	63	24	39			17	46		
Cytology									
LUAD	19	3	16	68.056	<0.001	0	19	75.333	<0.001
LUSC	23	0	23			0	23		
NSCLC	10	0	10			0	10		
Atypical	24	12	12			6	18		
NMC	21	21	0			21	0		
Clinical stage									
II	22	5	17	2.279	0.361	5	17	7.367	0.014
III	32	8	24			1	31		
IV	22	2	20			0	22		

MCM2: Minichromosome maintenance protein 2, MCM7: Minichromosome maintenance protein 7, LUAD: Lung adenocarcinoma, LUSC: Lung squamous cell carcinoma, NSCLC: Non-small cell lung carcinoma, NMC: Negative for malignant cells, SD: Standard deviation

**Table 2:** Mean H score/SD of markers for different lung lesions in sputum samples.

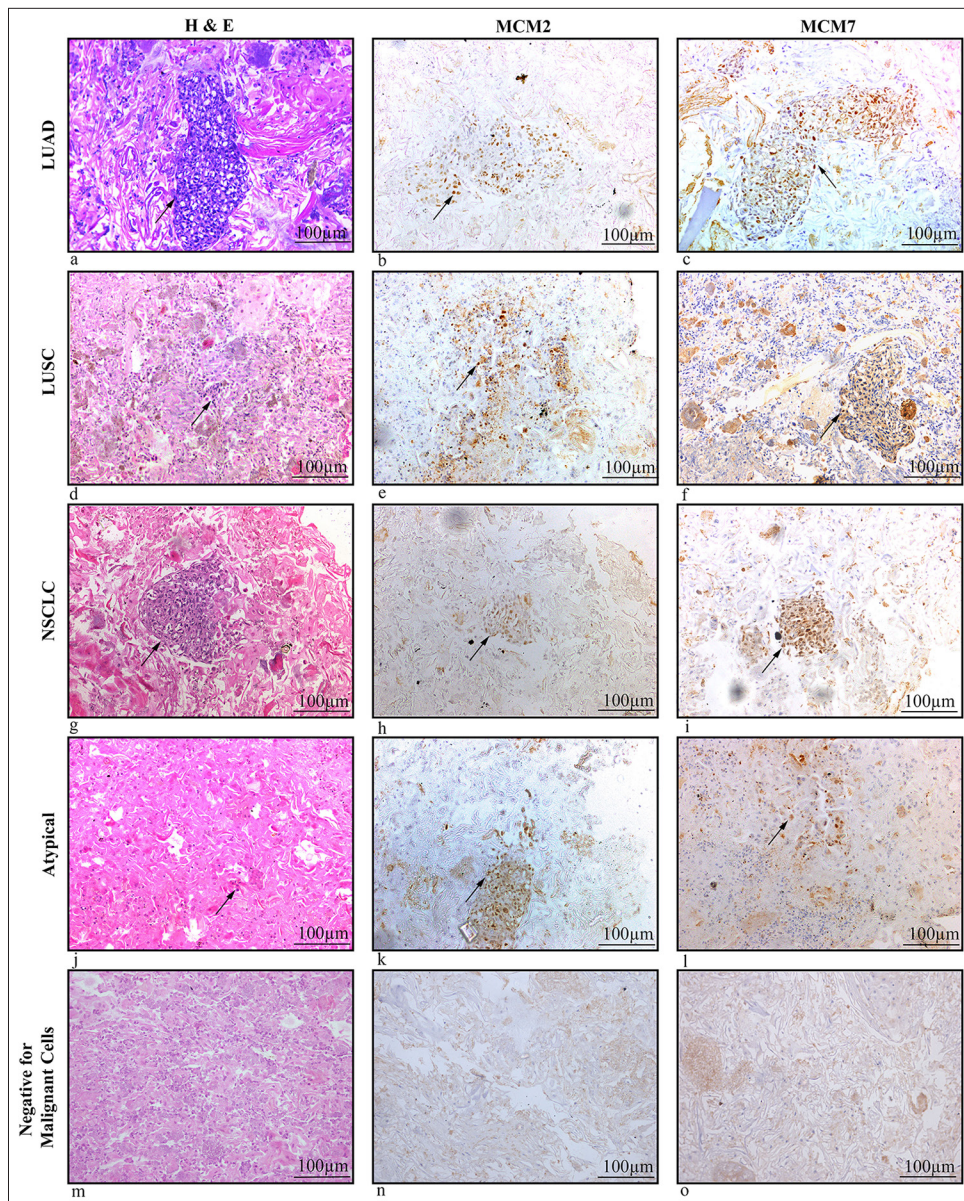
Diagnosis	Number of specimens	MCM 2 mean H score (SD)	MCM 7 mean H score (SD)
LUAD	19	123.9 (70.3)	184.3 (66.3)
LUSC	23	93.1 (53.5)	155.2 (68.9)
NSCLC	10	77 (37.6)	113 (39.2)
Atypical cells	24	22.5 (10.7)	53.5 (30.9)
NMC	21	0 (0)	0 (0)

MCM2: Minichromosome maintenance protein 2, MCM7: Minichromosome maintenance protein 7, LUAD: Lung adenocarcinoma, LUSC: Lung squamous cell carcinoma, NSCLC: Non-small cell lung carcinoma, NMC: Negative for malignant cells, SD: Standard deviation, H Score: Histology score

moderate nuclear expression of MCM2 and MCM7 was noted [Figure 1e and f]. Mild nuclear expression of both markers was seen in NSCLC cells [Figure 1h and i], while atypical cells exhibited weak or mild nuclear expression of MCM2 and MCM7 [Figure 1k and l], though this was limited to a small number of cells. In contrast, non-malignant samples were negative for both MCM2 and MCM7 [Figure 1n and o].

### Diagnostic performance of MCM2 and MCM7

The diagnostic performance of MCM2 and MCM7 proteins for detecting malignancy was thoroughly evaluated. A total of 97 study subjects were tested, with 76 having malignancy and 21 being non-malignant. MCM2 demonstrated a sensitivity of 80.26% (61 true positives and 15 false negatives) and PPV of 100%, with a specificity of 100% (21 true negatives and 0 false positives), indicating that it is highly effective in correctly identifying malignant cases when present. On the other hand, MCM7 exhibited a higher sensitivity of 92.11% (70 true positives and 6 false negatives), also with a PPV of 100% and a specificity of 100% (21 true negatives and 0 false positives), suggesting that it is even more reliable in identifying malignant cells. To further assess the diagnostic accuracy, an ROC curve was constructed (figure not included as Table 3 is explanatory). The AUC for MCM7 was found to be 0.961, which is higher compared to MCM2, indicating superior overall diagnostic performance. This high AUC value for MCM7 underscores its robustness as a biomarker for malignancy in lung cancer diagnostics [Table 3].



**Figure 1:** (a-o) Cellblock sections of sputum samples of lung cancer patients showing MCM2 and MCM7 expressions. (a, d, g, j, m) H&E, magnification 20x of sputum cell blocks in LUAD, LUSC, NSCLC, Atypical and NMC subtypes. (b) Moderate nuclear expression of MCM2 in Adenocarcinoma cells. (c) Dense nuclear expression of MCM7 in Adenocarcinoma cells. (e and f) Moderate nuclear expression of MCM2 and MCM7 in squamous cell carcinoma cells. (h and i) Mild nuclear expression of MCM2 and MCM7 in NSCLC cells. (k and l) Weak/Mild nuclear expression of MCM2 and MCM7 in atypical cells. (n and o) MCM2 and MCM7 negative in non-malignant samples (Scale bar- 100 µm). The arrow points the malignant cells in the cellblock. (H&E: Hematoxylin and eosin, MCM2: Minichromosome maintenance protein 2, MCM7: Minichromosome maintenance protein 7, LUAD: Lung adenocarcinoma, LUSC: Lung squamous cell carcinoma, NSCLC: Non-small cell lung carcinoma, NMC: Negative for malignant cells).

## DISCUSSION

Replicative immortality and sustained proliferative signaling are the well-established hallmarks of cancer.<sup>[15,16]</sup> DNA replication is a key factor in cell proliferation, which occurs

more frequently in malignant cells compared to healthy ones. Cancer cells have aberrant expression of several proteins involved in DNA replication. One example is the replication factor MCM7, which forms the pre-replication complex during the progression of the cell cycle and attaches to the

**Table 3:** Diagnostic test result of MCM proteins based on H score.

Markers	Sensitivity (%)	Specificity (%)	PPV (%)	NPV (%)	Accuracy	AUC
MCM 2	80.26	100	100	58.33	84.54	0.901
MCM 7	92.11	100	100	77.78	98.81	0.961

MCM2: Minichromosome maintenance protein 2, MCM7: Minichromosome maintenance protein 7, PPV: Positive predictive value, NPV: Negative predictive value, AUC: Area under the curve

double-stranded DNA at the replication origins in the late G1 phase.<sup>[17]</sup> It is highly expressed in various malignancies and may serve as a potential marker for cell proliferation.<sup>[18,19]</sup> Further, MCM7 has been demonstrated as a proliferation marker in several cancers, including lymphoma, ovarian cancer, prostate cancer, lung cancer, etc., equivalent to the established proliferation markers like Kiel-67 (Ki-67) and proliferating cell nuclear antigen.<sup>[10]</sup>

MCM proteins are more sensitive markers of proliferation than Ki-67 because MCM proteins can identify a broader range of proliferative cells, including those that may not be detected by Ki-67, especially in the early G1 phase.<sup>[20]</sup> MCM proteins have been studied in various types of lung cancers, including NSCLC and SCLC. Their expression is often higher in more aggressive forms. Ki-67 is also used across different lung cancer types, but its expression can differ significantly among diverse tumor types and even within distinct areas of the same tumor.<sup>[21]</sup> A meta-analysis by Martin *et al.* examined the prognostic value of Ki-67 expression in lung cancer, providing a comprehensive overview of its role in predicting patient outcomes.<sup>[22]</sup> Another study by Stoeber *et al.* investigated the diagnostic potential of MCM proteins in cancer, suggesting broader applications beyond lung cancer.<sup>[23]</sup> The use of MCM proteins in clinical practice is still evolving, but they offer potential as diagnostic and prognostic markers, possibly complementing or even surpassing Ki-67 in certain cases.

MCM7, unlike Ki-67, is expressed throughout the entire cell cycle (except G0), making it a more sensitive marker for detecting cells that are actively proliferating. This is particularly important in lung cancer, where the early detection of proliferative cells can significantly influence prognosis and treatment strategies. Williams G. H. and Stoeber K. emphasized the broader sensitivity of MCM proteins, including MCM7, in identifying proliferative cells across different phases of the cell cycle, which could improve the accuracy of diagnosis of lung cancer. In addition to its diagnostic and prognostic value, MCM7 may also serve as a therapeutic target. Since MCM7 plays a crucial role in DNA replication, targeting it could inhibit cancer cell proliferation, providing a novel approach to lung cancer treatment.<sup>[24]</sup> Samad *et al.* discussed the potential of targeting MCM7 in lung cancer therapy, noting that its inhibition could disrupt tumor growth by interfering with DNA replication processes.<sup>[25]</sup>

Cytological analysis of sputum increases the lung cancer detection rate, and hence, it is considered a poor man's bronchoscopy.<sup>[26]</sup> Veena *et al.*, in 2019, suggested an advanced technique for sputum processing to address the shortcomings of sputum cytology and the uncertainty of atypical samples.<sup>[27]</sup> Recently, there has been a lot of focus on finding certain molecular markers to add to the traditional morphological study of sputum to increase the technique's sensitivity and specificity. LBC of sputum samples provide monolayered smear without much mucus and other debris in the smear background, which reduces the likelihood of diagnostic errors. Furthermore, the cells clogged in mucus can be obtained in the smear without much reactive changes. Computerized screening of sputum cytology slides may be possible with LBC. Cell blocks prepared in cell buttons processed in the LBC method provided clear sections without much background materials of mucus and inflammatory cells. In the current study, we have noticed a higher expression of MCM7 protein in all the lung cancer sputum samples analyzed, which was followed by MCM2 expression which supports the previous reports. MCM2 was found to be an independent predictor of survival in patients with NSCLC and a prospective diagnostic marker for premalignant lung lesions.<sup>[28,29]</sup> According to Toyokawa *et al.*, both the messenger ribonucleic acid (mRNA) and protein levels of MCM7 expression were significantly greater in various cancer tissues compared to normal tissues.<sup>[10]</sup> However, we could not find MCM7 expression in benign respiratory epithelium in any of the sputum samples. The observation of higher MCM7 H score values being positively linked to tumor type in lung sputum samples is in consistence with other earlier reports in lung tissue samples from Liu *et al.*<sup>[30]</sup>

Our investigation also demonstrated a noteworthy correlation of MCM2 with tumor cytology and MCM 7 with tumor stage and cytological type. The prognosis can be predicted using this observation. These results corroborate earlier research that revealed MCM7 markers could be utilized to forecast tumor growth and patients' prognosis with NSCLC.<sup>[10]</sup> A substantial association between MCM2 expression and a poor prognosis in NSCLC patients was also discovered by Yang *et al.*, indicating that tumor proliferation may be a crucial factor in determining the prognosis of NSCLC.<sup>[31]</sup> The poor survival rate for NSCLC patients is

associated with the late-stage presentation of patients with unresectable tumors because there is no validated screening method for early diagnosis, making small biopsies/cytology samples more essential.<sup>[32]</sup>

MCM protein sensitivity in sputum samples has also been examined as a potential predictor of malignant lesions. Cytology samples are more sensitive than histology samples because MCM-positive cells typically arise at the surface of the aberrant epithelia.<sup>[33]</sup> For this reason, MCMs are extremely promising indicators for the early identification of cancer and precancerous conditions in cytology samples. In our evaluation of sputum samples from patients with various subtypes of lung cancer, we found that the MCM7 protein demonstrated a sensitivity of 92% and a specificity of 100% for diagnosing malignancy. Another study showed that cell division cycle 6 protein demonstrated the highest sensitivity of 87.7% in sputum samples for characterization of malignant cells followed by MCM5 and MCM2 with 66.67% and 58.89%, respectively.<sup>[34]</sup>

The current study could recognize some of the samples of sputum reported with an indiscriminate diagnosis of atypical cells to a definite diagnosis of malignancy, suggesting the significance of MCM7 in the differential diagnosis of malignancy in sputum samples. This information can be used to define some alternative techniques for the detection of malignant cells in sputum, particularly for people with clinical complaints and abnormal X-ray results in low-resource environments. Incorporation of MCM7 immunocytochemistry in routine clinical practice will certainly enhance the diagnostic efficacy of sputum cytology, which is comparatively easier, cost-effective, and highly economical compared to bronchoscopy and biopsy for the diagnosis of lung cancer, and it can be repeated easily if required without any hardship to the patient. While this research offers insightful information about using MCM2 and MCM7 as biomarkers to enhance traditional sputum cytology, there are some limitations which include the relatively small sample size in each type of tumors, lack of early-stage tumors and precancerous conditions, and lack of follow-up. A multicentric study in a large cohort from a broader population with follow-up of patients is warranted to generalize the significance of MCM proteins in lung cancer diagnosis.

## SUMMARY

To our knowledge, this is the first study to report MCM7 expression in sputum cells, highlighting its potential to significantly increase the sensitivity of sputum cytology. The incorporation of MCM7 protein analysis into conventional sputum cytology could greatly improve the detection of malignant cells, thus supplementing morphological evaluation methods. This is particularly valuable for samples

with atypical cells, where traditional cytology alone might not provide definitive results. By increasing the sensitivity of sputum cytology, MCM7 can help ensure that more cases of lung cancer are accurately identified at an earlier stage. Furthermore, our analysis suggests that examining MCM7 expression in sputum samples from patients with biopsy-proven premalignant lung conditions could establish this protein as a useful marker for primary screening of lung cancer. This application has the potential to facilitate earlier detection and intervention, thereby improving patient outcomes. In addition to its diagnostic applications, the potential of MCM7 in forecasting the clinical behavior of lung lesions, as well as its prognostic value in terms of survival, warrants further investigation. Exploring these aspects could pave the way to the development of more precise and personalized treatment approaches for lung cancer patients, ultimately enhancing prognosis and survival rates.

## AVAILABILITY OF DATA AND MATERIALS

The data analyzed in this study can be accessed through the corresponding author upon reasonable request.

## ABBREVIATIONS

AUC: Area under the curve  
 CDC6: Cell division cycle 6  
 CT: Computed tomography  
 DPX: Dibutylphthalate polystyrene xylene  
 Ki-67: Kiel-67  
 LBC: Liquid-based cytology  
 LUAD: Lung adenocarcinoma  
 LUSC: Lung squamous cell carcinoma  
 MCM2: Minichromosome maintenance protein 2  
 MCM7: Minichromosome maintenance protein 7  
 MCMs: Minichromosome maintenance proteins  
 NMC: Negative for malignant cells  
 NPV: Negative predictive value  
 NSCLC: Non small cell lung carcinoma  
 PCNA: Proliferating Cell Nuclear Antigen  
 PPV: Positive predictive value  
 ROC: Receiver operating characteristic  
 SCLC: Small cell lung carcinoma

## AUTHOR CONTRIBUTIONS

NP: Wet lab works, data collection and analysis, interpretation of results, original manuscript preparation, review and editing; AL: Supervision of wet lab works, discussion drafting; JKKM: Statistical data analysis; VVS: Immunocytochemical data analysis; KS: Conceptualization, supervision, resources, review, and editing. All authors read and approved the final manuscript.



## ETHICS APPROVAL AND CONSENT TO PARTICIPATE

The study was approved by the Institutional review board and Human ethics committee of the Regional Cancer Centre (HEC No. 13/019 dated 21<sup>st</sup> February 2019). Informed consents were obtained from all the patients. The study was conducted in accordance with the Declaration of Helsinki.

## ACKNOWLEDGMENT

The authors would like to acknowledge the Council of Scientific and Industrial Research (CSIR) for fellowship to Neeraja Panakkal.

## FUNDING

Not applicable.

## CONFLICT OF INTEREST

The authors declare no conflict of interest.

## EDITORIAL/PEER REVIEW

To ensure the integrity and highest quality of CytoJournal publications, the review process of this manuscript was conducted under a **double-blind model** (authors are blinded for reviewers and vice versa) through an automatic online system.

## REFERENCES

- Sung H, Ferlay J, Siegel RL, Laversanne M, Soerjomataram I, Jemal A, *et al.* Global cancer statistics 2020: GLOBOCAN Estimates of incidence and mortality worldwide for 36 cancers in 185 countries. *CA Cancer J Clin* 2021;71:209-49.
- Travis WD, Brambilla E, Nicholson AG, Yatabe Y, Austin JH, Beasley MB, *et al.* The 2015 World Health Organization Classification of lung tumors: Impact of genetic, clinical and radiologic advances since the 2004 classification. *J Thorac Oncol* 2015;10:1243-60.
- Guzman NA, Guzman A. Human sputum proteomics: Advancing non-invasive diagnosis of respiratory diseases with enhanced biomarker analysis methods. *Int J Transl Med* 2024;4:309-33.
- Chowdhury MM, Arif MH, Ekram Ullah E, Al Mamun A, Karim MN, Biswas R. A prospective observational study between the value of sputum cytology and FNAC of bronchial growth in diagnosing lung cancer at Chattogram Medical College Hospital, Bangladesh. *Asian J Med Sci* 2021;12:55-9.
- Saraswathy Veena V, Sara George P, Jayasree K, Sujathan K. Comparative analysis of cell morphology in sputum samples homogenized with dithiothreitol, N-acetyl-L cysteine, Cytosolix(\*) red preservative and in cellblock preparations to enhance the sensitivity of sputum cytology for the diagnosis of lung cancer. *Diagn Cytopathol* 2015;43:551-8.
- Riera A, Speck C. Licensing of replication origins. In: Kaplan D, editors. *The initiation of DNA replication in eukaryotes*. Cham: Springer; 2016. p. 189-211.
- Radhakrishnan A, Gangopadhyay R, Sharma C, Kapardar RK, Sharma NK, Srivastav R. Unwinding helicase MCM functionality for diagnosis and therapeutics of replication abnormalities associated with cancer: A review. *Mol Diagn Ther* 2024;28:249-64.
- Simon NE, Schwacha A. The Mcm2-7 replicative helicase: A promising chemotherapeutic target. *Biomed Res Int* 2014;2014:549719.
- Giaginis C, Vgenopoulou S, Vielh P, Theocharis S. MCM proteins as diagnostic and prognostic tumor markers in the clinical setting. *Histol Histopathol* 2010;25:351-70.
- Toyokawa G, Masuda K, Daigo Y, Cho HS, Yoshimatsu M, Takawa M, *et al.* Minichromosome maintenance protein 7 is a potential therapeutic target in human cancer and a novel prognostic marker of non-small cell lung cancer. *Mol Cancer* 2011;10:65.
- Wang M, Xie S, Yuan W, Xie T, Jamal M, Huang J, *et al.* Minichromosome maintenance protein 10 as a marker for proliferation and prognosis in lung cancer. *Int J Oncol* 2019;55:1349-60.
- Wu W, Wang X, Shan C, Li Y, Li F. Minichromosome maintenance protein 2 correlates with the malignant status and regulates proliferation and cell cycle in lung squamous cell carcinoma. *Onco Targets Ther* 2018;11:5025-34.
- Neves H, Kwok HF. In sickness and in health: The many roles of the minichromosome maintenance proteins. *Biochim Biophys Acta Rev Cancer* 2017;1868:295-308.
- Liu YZ, Jiang YY, Hao JJ, Lu SS, Zhang TT, Shang L, *et al.* Prognostic significance of MCM7 expression in the bronchial brushings of patients with non-small cell lung cancer (NSCLC). *Lung Cancer* 2012;77:176-82.
- Hanahan D, Weinberg RA. The hallmarks of cancer. *Cell* 2000;100:57-70.
- Hanahan D, Weinberg RA. Hallmarks of cancer: The next generation. *Cell* 2011;144:646-74.
- Bell SP, Dutta A. DNA replication in eukaryotic cells. *Annu Rev Biochem* 2002;71:333-74.
- Ren B, Yu G, Tseng GC, Cieply K, Gavel T, Nelson J, *et al.* MCM7 amplification and overexpression are associated with prostate cancer progression. *Oncogene* 2006;25:1090-8.
- Facoetti A, Ranza E, Grecchi I, Benericetti E, Ceroni M, Morbini P, *et al.* Immunohistochemical evaluation of minichromosome maintenance protein 7 in astrocytoma grading. *Anticancer Res* 2006;26:3513-6.
- Joshi S, Watkins J, Gazinska P, Brown JP, Gillett CE, Grigoriadis A, *et al.* Digital imaging in the immunohistochemical evaluation of the proliferation markers Ki67, MCM2 and Geminin, in early breast cancer, and their putative prognostic value. *BMC Cancer* 2015;15:546.
- Chirieac LR. Ki-67 expression in pulmonary tumors. *Transl Lung Cancer Res* 2016;5:547-51.
- Martin B, Paesmans M, Mascaux C, Berghmans T, Lothaire P, Meert AP, *et al.* Ki-67 expression and patients survival in lung

- cancer: systematic review of the literature with meta-analysis. *Br J Cancer* 2004;91:2018-25.
23. Stoeber K, Swinn R, Prevost AT, de Clive-Lowe P, Halsall I, Dilworth SM, *et al.* Diagnosis of genito-urinary tract cancer by detection of minichromosome maintenance 5 protein in urine sediments. *J Natl Cancer Inst* 2002;94:1071-9.
  24. Williams GH, Stoeber K. The cell cycle and cancer. *J Pathol* 2012;226:352-64.
  25. Samad A, Parvez MA, Huq MA, Rahman MS. Transcriptional expression and prognostic roles of MCM7 in human bladder, breast, and lung cancers: A multi-omics analysis. *Netw Model Anal Health Inform Bioinform* 2022;12:8.
  26. Ammanagi AS, Dombale VD, Miskin AT, Dandagi GL, Sangolli SS. Sputum cytology in suspected cases of carcinoma of lung (Sputum cytology a poor man's bronchoscopy!). *Lung India* 2012;29:19-23.
  27. Veena VS, George PS, Rajan K, Chandramohan K, Jayasree K, Sujathan K. Immunocytochemistry on sputum samples predicts prognosis of lung cancer. *J Cytol* 2019;36:38-43.
  28. Tan DF, Huberman JA, Hyland A, Loewen GM, Brooks JS, Beck AF, *et al.* MCM2--a promising marker for premalignant lesions of the lung: A cohort study. *BMC Cancer* 2001;1:6.
  29. Ramnath N, Hernandez FJ, Tan DF, Huberman JA, Natarajan N, Beck AF, *et al.* MCM2 is an independent predictor of survival in patients with non-small-cell lung cancer. *J Clin Oncol* 2001;19:4259-66.
  30. Liu YZ, Jiang YY, Wang BS, Hao JJ, Shang L, Zhang TT, *et al.* A panel of protein markers for the early detection of lung cancer with bronchial brushing specimens. *Cancer Cytopathol* 2014;122:833-41.
  31. Yang J, Ramnath N, Moysich KB, Asch HL, Swede H, Alrawi SJ, *et al.* Prognostic significance of MCM2, Ki-67 and gelsolin in non-small cell lung cancer. *BMC Cancer* 2006;6:203.
  32. Travis WD, Brambilla E, Noguchi M, Nicholson AG, Geisinger K, Yatabe Y, *et al.* Diagnosis of lung cancer in small biopsies and cytology: Implications of the 2011 International Association for the Study of Lung Cancer/American Thoracic Society/European Respiratory Society classification. *Arch Pathol Lab Med* 2013;137:668-84.
  33. Davies RJ, Freeman A, Morris LS, Bingham S, Dilworth S, Scott I, *et al.* Analysis of minichromosome maintenance proteins as a novel method for detection of colorectal cancer in stool. *Lancet* 2002;359:1917-9.
  34. Veena VS, Rajan K, Saritha VN, Preethi SG, Chandramohan K, Jayasree K, *et al.* DNA replication licensing proteins lung cancer early detection markers. *Asian Pac J Cancer Prev* 2017;18:3041-7.

**How to cite this article:** Panakkal N, Lekshmi A, Krishna KMJ, Saraswathy VV, Sujathan K. Expression of minichromosome maintenance proteins in the exfoliated cells supplement sputum cytology in the diagnosis of lung cancer. *CytoJournal*. 2024;21:81. doi: 10.25259/Cytojournal\_115\_2024

HTML of this article is available FREE at:  
[https://dx.doi.org/10.25259/Cytojournal\\_115\\_2024](https://dx.doi.org/10.25259/Cytojournal_115_2024)

The FIRST **Open Access** cytopathology journal

Publish in *CytoJournal* and **RETAIN** your *copyright* for your intellectual property

**Become Cytopathology Foundation (CF) Member at nominal annual membership cost**

For details visit <https://cytojournal.com/cf-member>

**PubMed** indexed

**FREE** world wide **open access**

**Online processing** with rapid turnaround time.

**Real time** dissemination of time-sensitive technology.

Publishes as many **colored high-resolution images**

Read it, cite it, bookmark it, use RSS feed, & many----



**CYTOJOURNAL**

[www.cytojournal.com](http://www.cytojournal.com)

Peer-reviewed academic cytopathology journal

