



## Quiz Case

# Liquid-based Papanicolaou smear: Unusual cytological features of a uterine mass

Dominique Yuan Bin Seow

Department of Anatomical Pathology, Division of Pathology, Singapore General Hospital, Singapore.



## QUIZ INFORMATION

A postmenopausal elderly Filipino female presented with dyspnea and abnormal vaginal bleeding. A chest X-ray showed a right pleural effusion, which was concerning for malignant effusion. She underwent a positron-emission tomography scan, which showed an <sup>18</sup>F-fluoro-2-deoxy-d-glucose-avid uterus. A liquid-based ThinPrep Papanicolaou (Pap) smear was performed. The images are shown in Figure 1.

### \*Corresponding author:

Dominique Yuan Bin Seow,  
Department of Anatomical  
Pathology, Division of  
Pathology, Singapore General  
Hospital, Singapore.

dominique.seow@mohh.com.sg

Received : 07 March 19

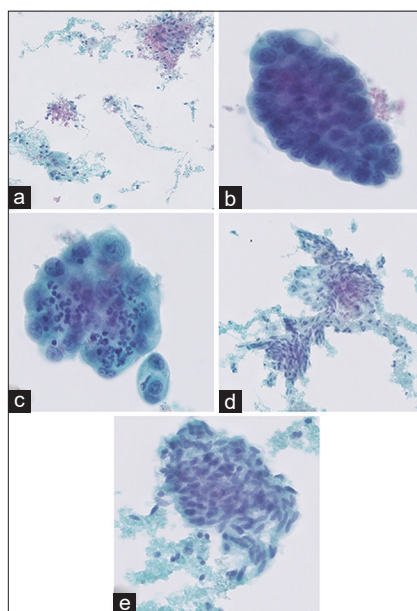
Accepted : 22 August 19

Published : 31 January 20

DOI

10.25259/Cytojournal\_89\_2019

Quick Response Code:



**Figure 1:** (a) Abundant, watery tumor diathesis was present in the background (Pap, ×100); (b) Three-dimensional groups of glandular cells with enlarged nuclei, irregular chromatin, prominent nucleoli, and vacuolated cytoplasm were present (Pap, ×400); (c) Some clusters showed “bag of polyps” appearance and clinging diathesis (Pap, × 400); (d). A second minor population of atypical spindled cells was present (Pap, ×400); (e) These atypical spindle cells exhibited nuclear hyperchromasia, irregular chromatin, variation in nuclear size, and were associated with tumor diathesis (Pap, ×400).

## QUESTION

Q1. What is your interpretation of the above findings?

- Atypical glandular cells of uncertain significance (AGUS)
- Suspicious for carcinosarcoma (malignant mixed Mülleriantumor [MMMT])
- Adenocarcinoma, not otherwise specified
- Squamous cell carcinoma.

**ANSWER**

1. b

Uterine carcinosarcomas, also known as MMMT, are uncommon uterine tumors that comprise malignant epithelial and mesenchymal components. In this case, smears showed a biphasic neoplasm composed of malignant glandular and spindled cell elements, which should raise the differential of a carcinosarcoma.

AGUS is an inappropriate diagnosis as the smear showed background tumor diathesis, as well as tumour cells with overtly malignant cytological features. Although adenocarcinoma is a fair differential diagnosis in this case, it does not explain the presence of an atypical spindle cell population. A spindle cell component of squamous cell carcinoma can also demonstrate the presence of atypical spindled cells. However, squamous cell carcinoma, particularly keratinizing variants, would show “tadpole” and “fiber” cells, along with a background containing high-grade squamous intraepithelial lesion cells. Thus, option B is the favored answer.

**PATIENT FOLLOW-UP**

The patient had a concurrent endometrial sampling performed with the liquid-based Pap smear. It showed a high-grade malignancy with a heterogeneous appearance [Figure 2]. Some areas showed micropapillae, hierarchical branching, and slit-like glands in keeping with a high-grade serous component [Figure 2a]. Other areas showed blunt papillae, tubules lined by cells with eosinophilic to clear cytoplasm-containing eosinophilic luminal secretion, along with positive immunostaining with napsin A [Figure 2b], in keeping with a clear-cell component. Malignant endometroid glands were also present [Figure 2c]. A few fragments showed a fascicular proliferation of malignant spindled cells with brisk mitotic activity [Figure 2d] that was negative for MNF116 and positive for vimentin [Figure 2e]. The overall findings were consistent with carcinosarcoma without any heterologous elements. Following the diagnosis, the patient was lost to clinical follow-up.

**ADDITIONAL QUIZ QUESTION**

1. Which of the following statements is true, given the appearance of a biphasic epithelial/mesenchymal neoplasm on a smear which is suspicious for uterine carcinosarcoma?

- More than 25% of carcinosarcomas demonstrate an atypical or pleomorphic spindle cell component and a malignant glandular component on Pap smears.
- An abnormal Pap smear result in carcinosarcoma correlates with decreased median survival in a stage-independent manner.

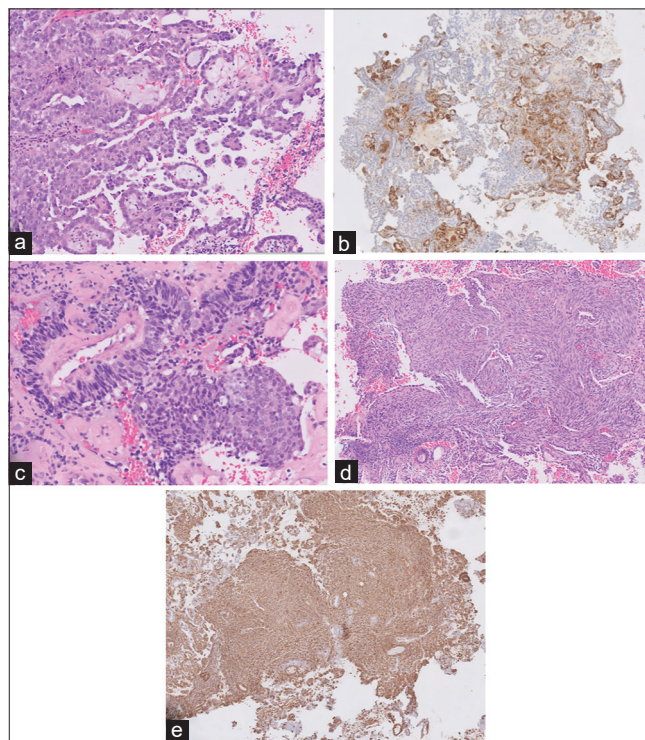
- Conventional Pap smears are highly sensitive for detecting carcinosarcoma.
- A positive Pap smear in carcinosarcoma has no correlation with cervical involvement.

**Answers to additional quiz question**

Q1: B

**BRIEF REVIEW OF THE TOPIC**

Carcinosarcoma of the uterine corpus is a rare malignancy, with an incidence of <2/100,000 women/year.<sup>[1]</sup> Cervical Pap smears are relatively insensitive for detecting carcinosarcoma. Past studies have reported that the detection rate of malignant cells in histologically-proven carcinosarcoma ranges between 56% and 70%.<sup>[2-4]</sup> Carcinosarcoma with positive Pap smears have previously been initially diagnosed with atypical glandular cells, squamous cell carcinoma, endometrial adenocarcinoma, poorly differentiated carcinoma, or adenocarcinoma not otherwise specified.<sup>[2]</sup> Only a minority of cases (5%–9%) are



**Figure 2:** (a) The endometrial biopsy demonstrated malignant epithelial elements composed of high-grade serous carcinoma (H and E, ×200); (b) Areas with napsin A positivity were present, in keeping with a component of clear-cell carcinoma (H and E, ×200); (c) Other areas demonstrated endometroid differentiation (H and E, ×200); (d) A portion of the tumor also showed malignant spindle cell in fascicles with marked nuclear atypia and mitotic activity (H and E, ×200); (e) These clustered groups of spindle cells were negative for MNF116 (not pictured) and positive for vimentin (×200).

initially diagnosed with carcinosarcoma on Pap smear. This is contingent on identifying a sarcomatous component, which is usually absent due to their resistance to exfoliation.<sup>[5]</sup> In one retrospective review, only 8% of cases of uterine carcinosarcomas disclosed atypical spindle cells on Pap smear.<sup>[2]</sup>

Most cases that have reported the cytological features of uterine carcinosarcomas have been described on cervicovaginal smears. Endometrial cytology has not been widely used because of overlapping cells and blood contamination, but the introduction of liquid-based cytology that reduces contamination and forms a thin, uniform layer of cells has allowed a reassessment of the role of endometrial cytology in cytological diagnosis.<sup>[6]</sup> In a recent study, Okano *et al.* compared the features of uterine carcinosarcomas on endometrial and cervical liquid-based smears. They found that the carcinomatous component was detected in 94.4% of endometrial and 76.5% of cervical specimens, whereas the sarcomatous component was detected in 33.3% of endometrial and 17.6% of endocervical specimens. Interestingly, in both types of specimens, the sarcomatous component was more frequently detected in the heterologous type as compared to the homologous type of uterine carcinosarcoma.<sup>[7]</sup>

While the liquid-based Pap smear remains mainly a screening test for cervical lesions, it does fortuitously detect high-grade endometrial cancers, including carcinosarcoma. For patients who have not undergone concurrent endometrial sampling, a Pap smear may be the only initial way an endometrial cancer is detected. Moreover, Pap smears have also been reported to contribute to the improved preoperative identification of patients with high-grade endometrial cancers, including carcinosarcomas.<sup>[8]</sup> Hanley *et al.* also showed that carcinosarcomas with an abnormal Pap smear result correlates with cervical involvement and decreased median survival in a stage-independent manner,<sup>[9]</sup> thus highlighting the Pap smear's potential dual function in screening/diagnosis and prognostication.

On correlating the findings of the endometrial biopsy with the Pap smear for this case, the atypical spindled cell population detected on cytology most likely corresponded to the malignant spindled cell component of the carcinosarcoma in the biopsy. However, it is certainly difficult to issue a confident diagnosis of carcinosarcoma, especially if the spindle cell population detected on cytology is scant or does not demonstrate frankly pleomorphic features. In our case, with the benefit of having a concurrent endometrial biopsy, a diagnosis of carcinosarcoma was made on the Pap smear. In the absence of a biopsy specimen, however, it would still be prudent to report the presence of a neoplasm with malignant epithelial and spindle cell features and raise the differential of carcinosarcoma. Other differentials may include endometrial adenocarcinoma with a spindle cell component, adenosquamous carcinoma, and cervical squamous cell carcinoma.<sup>[2]</sup>

## CONCLUSION

The presence of a biphasic neoplasm composed of a malignant epithelial component and a spindled cell/mesenchymal component should raise the differential for a carcinosarcoma on a Pap smear. Where available, the Pap smear findings should be correlated with histological biopsy findings. While the Pap smear remains an insensitive tool for detecting carcinosarcoma, the presence of a positive Pap smear correlates with cervical involvement and stage-independent decreased survival.

## Acknowledgments

The author would like to thank Dr. A. Chong for her guidance in the diagnosis of the case.

## COMPETING INTERESTS STATEMENT BY ALL AUTHORS

The authors declare that they have no competing interests.

## AUTHORSHIP STATEMENT BY ALL AUTHORS

All authors of this article declare that we qualify for authorship as defined by ICMJE <http://www.icmje.org/#author>. Each author has participated sufficiently in the work and takes public responsibility for appropriate portions of the content of this article.

DS reviewed and reported the case, performed the literature review, selected the appropriate images, and drafted the final manuscript. All authors read and approved the final manuscript.

## ETHICS STATEMENT BY ALL AUTHORS

As this is a case report without identifiers, our institution does not require approval from the Institutional Review Board (IRB) (or its equivalent).

## LIST OF ABBREVIATIONS (In alphabetic order)

AGUS - Atypical glandular cells of uncertain significance  
 HSIL - High-grade squamous intraepithelial lesion  
 LBC - Liquid-based cytology  
 MMT - Malignant mixed Müllerian tumor  
 Pap - Papanicolaou  
 PET - Positron-emission tomography.

## EDITORIAL/PEER-REVIEW STATEMENT

To ensure the integrity and highest quality of CytoJournal publications, the review process of this manuscript was conducted under a **double-blind model** (the authors are

blinded for reviewers and vice versa) through automatic online system.

## REFERENCES

- Vaidya AP, Horowitz NS, Oliva E, Halpern EF, Duska LR. Uterine malignant mixed müllerian tumors should not be included in studies of endometrial carcinoma. *Gynecol Oncol* 2006;103:684-7.
- Snyder MJ, Robboy SJ, Vollmer RT, Dodd LG. An abnormal cervicovaginal cytology smear in uterine carcinosarcoma is an adverse prognostic sign: Analysis of 25 cases. *Am J Clin Pathol* 2004;122:434-9.
- Costa MJ, Tidd C, Willis D. Cervicovaginal cytology in carcinosarcoma [malignant mixed müllerian (mesodermal) tumor] of the uterus. *Diagn Cytopathol* 1992;8:33-40.
- Tenti P, Babilonti L, La Fianza A, Zampatti C, Carnevali L, Sonnino P, *et al.* Cytology of malignant mixed mesodermal tumour of the uterus: Experience of 10 cases. *Eur J Gynaecol Oncol* 1989;10:125-8.
- Gupta N, Dudding N, Smith JH. Eight cases of malignant mixed müllerian tumor (carcinosarcoma) of the uterus: Findings in SurePath™ cervical cytology. *Diagn Cytopathol* 2014;42:165-9.
- Norimatsu Y, Yanoh K, Kobayashi TK. The role of liquid-based preparation in the evaluation of endometrial cytology. *Acta Cytol* 2013;57:423-35.
- Okano K, Ishida M, Sandoh K, Mizokami T, Kita M, Okada H, *et al.* Cytological features of uterine carcinosarcoma: A retrospective study of 20 cases with an emphasis on the usefulness of endometrial cytology. *Diagn Cytopathol* 2019;47:547-52.
- Amkreutz LC, Pijnenborg JM, Joosten DW, Mertens HJ, Van Kuijk SM, Engelen MJ, *et al.* Contribution of cervical cytology in the diagnostic work-up of patients with endometrial cancer. *Cytopathology* 2018;29:63-70.
- Hanley KZ, Oprea-Ilie G, Ormenisan C, Seydafkan S, Mosunjac MB. Atypical findings on cervicovaginal smears correlate with cervical involvement by malignant mixed müllerian tumors of the uterus. *Acta Cytol* 2015;59:319-24.

**How to cite this article:** Seow DY. Liquid-based Papanicolaou smear: Unusual cytological features of a uterine mass. *CytoJournal* 2020;17:2.

### The FIRST Open Access cytopathology journal

Publish in *CytoJournal* and **RETAIN** your *copyright* for your intellectual property

**Become Cytopathology Foundation Member** to get all the benefits

Annual membership fee is nominal US \$ 50 (US \$ 1000 for life)

**In case of economic hardship it is free**

For details visit <https://cytojournal.com/cf-member>

**PubMed** indexed

**FREE** world wide open access

**Online processing** with rapid turnaround time.

**Real time** dissemination of time-sensitive technology.

Publishes as many **colored high-resolution images**

Read it, cite it, bookmark it, use RSS feed, & many----



**CYTOJOURNAL**

[www.cytojournal.com](http://www.cytojournal.com)

Peer-reviewed academic cytopathology journal





# NextGen CelBloking™ Kits

**Frustrated with your cell blocks?  
We have a better solution!**

**Nano**

## Nano NextGen CelBloking™

Cell block kit to process single scattered cell specimens and tissue fragments of **any** cellularity.



**PATENT PENDING**



**Pack #1**



**Pack #2**

**Micro**

## Micro NextGen CelBloking™

For cellular specimens (more than 1 ml concentrated specimen with Tissuecrit more than 50%)



**PATENT PENDING**



**Pack #2**