


Quiz Case

Cytomorphology of a brain lesion and its pitfall

Priyanka Singh¹ MD , Adil Aziz Khan¹ MBBS , Sachin Kolte¹ MD, Mukul Singh¹ MD

¹Department of Pathology, Vardhman Mahavir Medical College and Safdarjung Hospital, New Delhi, India.



***Corresponding author:**
Priyanka Singh,
Department of Pathology,
Vardhman Mahavir Medical
College and Safdarjung
Hospital, New Delhi, India.
dr.singh1907@gmail.com

Received: 22 March 2023
Accepted: 08 June 2023
Published: 09 October 2023

DOI
[10.25259/Cytojournal_24_2023](https://doi.org/10.25259/Cytojournal_24_2023)

Quick Response Code:



A 25-year-old man presented with complaints of giddiness and severe headache for 20 days. Magnetic resonance imaging showed a solid mass lesion of size 56 × 57 mm in the left frontal lobe. Intraoperative tumor cavity fluid (2 mL, clear) was aspirated and sent for cytological examination. Cyto-centrifuge smears prepared were cellular [Figure 1a-c].

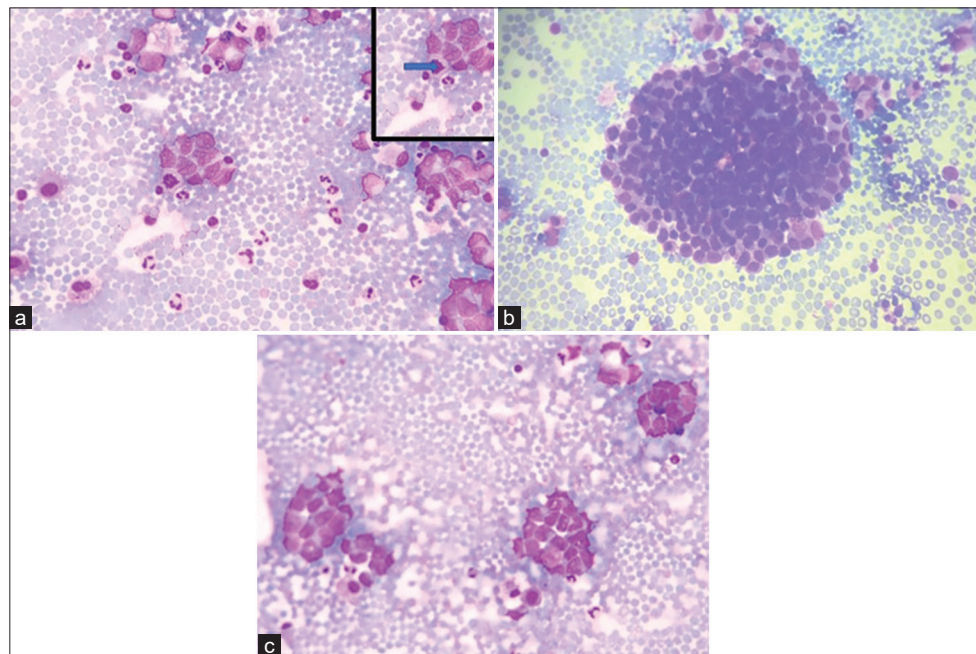


Figure 1: (a-c) (GIEMSA ×40) Smears showing tumor cells in clusters and singly scattered having high N:C ratio and opened up chromatin and pleomorphism. (a) Inset shows atypical mitoses pointed by solid arrow.

QUESTION 1 What is your interpretation?

- Degenerated cells
- Adenocarcinoma
- Glioma
- Small blue round cell tumor.

ANSWER TO QUESTION 1

The correct cytopathological interpretation is d. Small blue round cell tumor.

EXPLANATION

Cyto centrifuge smears prepared were cellular comprising of monomorphic tumor cells arranged in clusters and nests. Individual tumor cells are round to ovoid having scant to moderate amount of delicate cytoplasm. Nuclei were regular, smooth with opened up chromatin, showing mild-to-moderate degree of pleomorphism [Figure 1a-c]. Atypical mitosis was noted. However, rosette or acini formation or necrosis or moulding was not seen.

The cells were cohesive with no acini formation, delicate chromatin and no nucleoli thereby ruling out adenocarcinoma (Option b).

No glial matrix or fibrillary processes or Rosenthal fibres or vessels or calcification or cellular pleomorphism or endothelial cell proliferation were displayed hence possibility of glioma was also excluded from the study (Option c).

Degenerated cells (Option a) were seen but most of the cells were preserved and had distinct cell boundary with nuclear margins and cellular details as discussed briefly above. Based on findings described above, a provisional diagnosis of small blue round blue cell tumor was considered. Cell block and immunocytochemistry could not be performed due to exhaustion of fluid while making smears for routine examination.

Excision surgery was performed and histopathological examination revealed a tumor [Figure 2a and b].

QUESTION 2

All of the following are among the differentials except

- Germ cell tumor
- Astrocytoma
- Melanoma
- Neuroendocrine tumor.

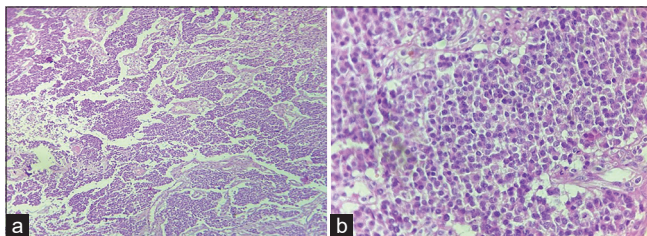


Figure 2: (a) Tumor cells arranged in nest, chords and trabeculae (H & E $\times 10$); (b) Tumor cells having round nucleus and powdery chromatin (H & E $\times 40$).

EXPLANATION

Histopathological examination revealed tumor cells arranged in nests, chords and trabeculae showing moderate degree of pleomorphism. Cells were round to oval with stippled nuclear chromatin [Figure 2a and b]. Areas of hemorrhage and focal areas of necrosis were also seen. Mitotic figures of 2–3/10 high power field noted. The various differentials included are neuroendocrine neoplasm (NEN), germ cell tumor, melanoma, and lymphoma.

Astrocytoma (option b) will show tumor cells having irregular nuclei with variable degree of atypia along with presence of glial processes. Cells can have variable cellular morphology in a fibrillary background which is not seen in this case.

Initial panel of immunohistochemistry (IHC) was applied which included Glial fibrillary acidic protein (GFAP), LCA, SALL4, CK7, CK20, CD117, desmin, myogenin, CD99, HMB 45, and S-100. All above markers came out to be negative except focal pan-cytokeratin positivity [Figures 3a-e]. A secondary panel of synaptophysin and chromogranin applied was positive. KI67 proliferation index was $>20\%$.

QUESTION 3

Which marker helped in excluding the primary nature of the lesion?

- Synaptophysin
- Chromogranin
- Pan-cytokeratin
- GFAP.

EXPLANATION

GFAP is positive in intermediate filament of astrocytes. In the present case, it was negative in the tumor cells.

Synaptophysin and chromogranin are markers for neuroendocrine cells whereas pancytokeratin indicates the epithelial nature of the lesion.

QUESTION 4

All further IHCs can be put to check for the metastatic site of NEN except

- Insulinoma associated protein 1 (INSM-1)
- CDX2- Caudal type homeobox2 (CDX2)
- Thyroid transcription factor 1 (TTF-1)
- Pancreatic battery (Insulin, gastrin, somatostatin, glucagon, etc.).

EXPLANATION

Insulinoma associated protein 1 (INSM-1) is a nuclear marker of neuroendocrine differentiation with better

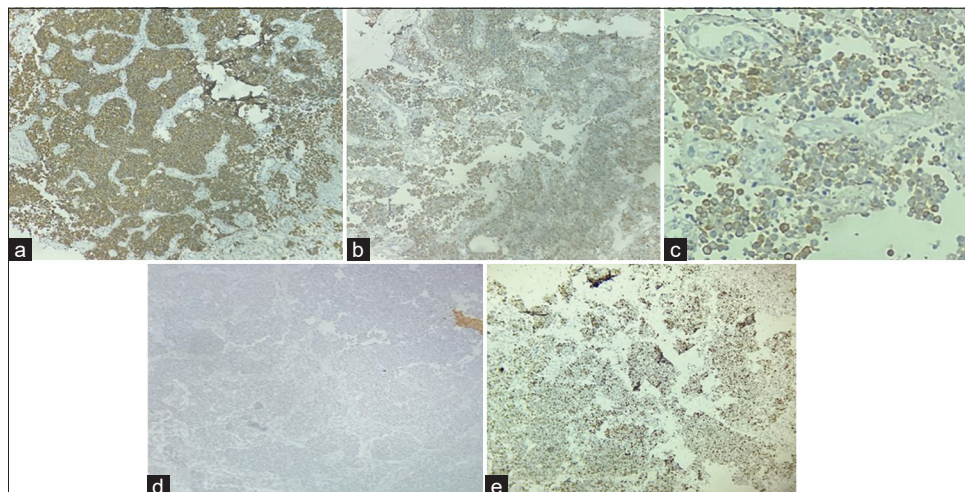


Figure 3: Immunohistochemistry: Strong positive synaptophysin (a), Positive Chromogranin (b), Pancytokeratin focal positive (c), and Glial fibrillary acidic protein negative (d), Ki67 >20% (e) ($\times 40$).

sensitivity and specificity as compared to synaptophysin, chromogranin, and CD56.

CDX2 helps in location metastasis from colon whereas TTF-1 from lung.

On extended IHC, the cells were focally positive for TTF-1 [Figure 4] while negative for Napsin-A and CDX2.

FURTHER FOLLOW UP OF THE CASE

A Positron emission tomography/Computed tomography (PET/CT) was performed which showed metabolically active soft tissue density lesion measuring $2.5 \times 1.7 \times 2.5$ cm in the upper lobe of left lung in the para mediastinal aspect with metabolic activity in the mediastinal lymph nodes. The above PET/CT findings further confirmed the histopathological diagnosis of tumor arising in lung.

BRIEF REVIEW

NEN can develop at any of the initial mentioned systems where the neuroendocrine cells are present.^[1] Incidence of central nervous system (CNS) metastasis is very rare and accounts 1.5–5% of all patients^[2] where NEN source found to be in 1.3–1.4% in all cases of CNS metastasis.^[3] It is always a challenging task to detect primary focus, because patients have specific symptoms when the tumor size is small. Radiological investigations including somatostatin scintigraphy and PET/CT proved to be very useful. Metastatic disease in addition to differentiation and proliferation rates is an important prognostic factor in NEN. Presence of brain metastasis is usually found to be characteristic of a systemic dissemination and disease progression.

Cytological features of neuroendocrine tumors are described in literature that includes monomorphic population of cells,

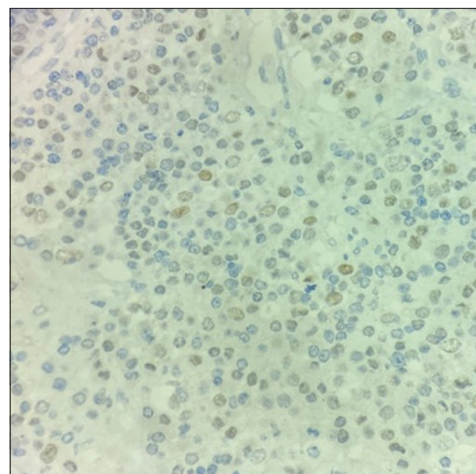


Figure 4: Tumor cells are positive for TTF-1 ($\times 40$).

loosely cohesive fragments, medium in size having abundant cytoplasm, and very few mitotic figures. Occasional rosette formation can be seen. Nuclei were regular, smooth with opened up chromatin, showing mild-to-moderate degree of pleomorphism [Figure 1]. Occasional cells showed prominent nucleolus. Atypical mitosis was seen. Due to variation in the cytomorphological features of neuroendocrine tumor, they mimic a variety of tumors. The features range from discrete cells to tight cohesive clusters, hyperchromatic nuclei with basophilic to granular to scant cytoplasm. Nuclear moulding may or may not be seen. Pleomorphism can be seen.^[4]

In the present case, diagnosis of metastatic neuroendocrine tumor Grade 3 was made. TTF-1 positivity pointed out the brain tumor was metastatic, which was later confirmed by PET-CT that exhibited a primary lesion in the lung. The grading of neuroendocrine tumors (NET) is based on Ki67 proliferation

index. However, in neuroendocrine carcinomas, also it is advised for distinguishing it from Grade 3 NETs.^[5] Features favoring neuroendocrine carcinoma are dirty smear with areas of necrotic debris and very scant cytoplasm in small cell type whereas abundant in large cell type. The population of cells having salt and paper chromatin, severe nuclear fragility, and many atypical mitoses.^[2,6] Only limited previous case reports are available discussing NEN initial presentation as brain metastasis,^[7-11] one of which was reported as a primary brain NEN of third ventricle adjacent to which in the paraventricular nucleus resides group of neuroendocrine cells.^[12] Mostly by the time patient presents with brain metastasis either metastasis to lung happens or develop primary lung tumor. The metastasis to brain occurs due to hematogenous spread of the tumor. Leading cause of death in patients with CNS NENs is secondary to systemic disease progression and a better 10-year overall survival rate is seen in primary brain NENs.^[13] Imaging workup holds importance where CT imaging has sensitivity of 95% in identification of primary tumor.^[14] Etoposide -platinum chemotherapy is the treatment of choice in grade 3 NEN.^[15] In metastatic brain NENs, radiation therapy and surgery are found to be beneficial but more research is required for proper management of primary brain NENs.^[16]

SUMMARY

Metastatic disease is a major prognostic factor in NEN s in addition to differentiation and proliferation rate. Brain metastasis of neuroendocrine carcinoma is a rare entity but the possibility of it should be borne in mind for accurate diagnosis. In the present study, patient has been on regular follow-up for 9 months and is living disease free while continuing on etoposide chemotherapy.

ANSWERS TO ADDITIONAL QUESTIONS Q2 TO Q4

Q2: b, Q3: d, Q4: a.

COMPETING INTERESTS STATEMENT BY ALL AUTHORS

The authors declare that they have no competing interests.

AUTHORSHIP STATEMENT BY ALL AUTHORS

Adil: data curation, Priyanka Singh: Conceptualization, formal analysis, data curation, writing-original draft, and writing-review and editing, Mukul Singh: review and editing, visualization, and supervision, and Sachin Kolte: writing-review and editing.

ETHICS STATEMENT BY ALL AUTHORS

The informed and written consent was obtained from the patient. The case was submitted without identifiers.

LIST OF ABBREVIATIONS (In alphabetic order)

CNS – Central Nervous system
 GFAP – Glial fibrillary acidic protein
 IHC – Immunohistochemistry
 MRI – Magnetic resonance imaging
 NEN – Neuroendocrine neoplasm
 PET/CT – Positron emission tomography/Computed tomography.

EDITORIAL/PEERREVIEW STATEMENT

To ensure the integrity and highest quality of CytoJournal publications, the review process of this manuscript was conducted under a **double-blind model** (the authors are blinded for reviewers and vice versa) through automatic online system.

REFERENCES

- Shalaby AM, Kazuei H, Koichi H, Naguib S, Al-Menawei LA. Assessment of intracranial metastases from neuroendocrine tumors/carcinoma. *J Neurosci Rural Pract* 2016;7:435-9. Retraction in: *J Neurosci Rural Pract* 2017;8:322.
- Nicholson SA, Ryan MR. A review of cytologic findings in neuroendocrine carcinomas including carcinoid tumors with histologic correlation. *Cancer* 2000;90:148-61.
- Hlatky R, Suki D, Sawaya R. Carcinoid metastasis to the brain. *Cancer* 2004;101:2605-13.
- Gupta S, Gupta P, Rohilla M, Gupta N, Srinivasan R, Rajwanshi A, *et al.* Neuroendocrine carcinomas: Cytological mimics and diagnostic dilemmas. *Diagn Cytopathol* 2020;48:440-5.
- Duan K, Mete O. Algorithmic approach to neuroendocrine tumors in targeted biopsies: Practical applications of immunohistochemical markers. *Cancer Cytopathol* 2016;124:871-84.
- Mete O, Hannah-Shmouni F, Kim R, Stratakis C. Inherited neuroendocrine neoplasms. In: Asa SL, La Rosa S, Mete O, editors. *The Spectrum of Neuroendocrine Neoplasia*. Cham, Switzerland: Springer Nature; 2021. p. 409-60.
- Maiuri F, Cappabianca P, De Caro MD, Esposito F. Single brain metastases of carcinoid tumors. *J Neurooncol* 2004;66:327-32.
- Hussein AM, Feun LG, Savaraj N, East D, Hussein DT. Carcinoid tumor presenting as central nervous system symptoms. Case report and review of the literature. *Am J Clin Oncol* 1990;13:251-5.
- Greene KA, Anson JA, Martinez JA, Spetzler RE, Johnson PC. Multicystic metastatic carcinoid to brain: Case report. *J Neurooncol* 1993;17:15-20.
- Porter DG, Chakrabarty A, McEvoy A, Bradford R. Intracranial carcinoid without evidence of extracranial disease. *Neuropathol Appl Neurobiol* 2000;26:298-300.
- Nakamura Y, Shimokawa S, Ishibe R, Ikee T, Taira A. Pulmonary carcinoid found in a patient who presented with initial symptoms of brain metastasis: Report of a case. *Surg Today* 2001;31:510-2.
- Reed CT, Duma N, Halfdanarson T, Buckner J. Primary

neuroendocrine carcinoma of the brain. *BMJ Case Rep* 2019;12:e230582.

13. Hallet J, Law CH, Cukier M, Saskin R, Liu N, Singh S. Exploring the rising incidence of neuroendocrine tumors: A population-based analysis of epidemiology, metastatic presentation, and outcomes. *Cancer* 2015;121:589-97.
14. Kirshbom PM, Kherani AR, Onaitis MW, Feldman JM, Tyler DS. Carcinoids of unknown origin: Comparative analysis with foregut, midgut, and hindgut carcinoids. *Surgery* 1998;124:1063-70.
15. Lacombe C, De Rycke O, Couvelard A, Turpin A, Cazes A, Hentic O, *et al.* Biomarkers of response to etoposide-platinum chemotherapy in patients with grade 3 neuroendocrine neoplasms. *Cancers (Basel)* 2021;13:643.
16. Mallory GW, Fang S, Giannini C, Van Gompel JJ, Parney IF. Brain carcinoid metastases: Outcomes and prognostic factors. *J Neurosurg* 2013;118:889-95.

How to cite this article: Singh P, Khan AA, Kolte S, Singh M. Cytomorphology of a brain lesion and its pitfall. *CytoJournal* 2023;20:38.

HTML of this article is available FREE at:
https://dx.doi.org/10.25259/Cytojournal_24_2023

The FIRST **Open Access** cytopathology journal

Publish in *CytoJournal* and **RETAIN** your *copyright* for your intellectual property

Become Cytopathology Foundation Member to get all the benefits

Annual membership fee is nominal US \$ 50 (US \$ 1000 for life)

In case of economic hardship it is free

For details visit <https://cytojournal.com/cf-member>

PubMed indexed

FREE world wide **open access**

Online processing with rapid turnaround time.

Real time dissemination of time-sensitive technology.

Publishes as many **colored high-resolution images**

Read it, cite it, bookmark it, use RSS feed, & many----



CYTOJOURNAL

www.cytojournal.com

Peer -reviewed academic cytopathology journal





NextGen CelBloking™ Kits

**Frustrated with your cell blocks?
We have a better solution!**

Nano

Nano NextGen CelBloking™

Cell block kit to process single scattered cell specimens and tissue fragments of **any** cellularity.



PATENT PENDING



Pack #1



Pack #2

Micro

Micro NextGen CelBloking™

For cellular specimens (more than 1 ml concentrated specimen with Tissuecrit more than 50%)



PATENT PENDING



Pack #2